

Content available at: <https://www.ipinnovative.com/open-access-journals>

IP International Journal of Maxillofacial Imaging

Journal homepage: <https://www.ipinnovative.com/journals/IJMI>

Case Report

Width of attached gingiva an important consideration for periodontium- A case report and literature review

Ameet Mani¹, Harish Saluja², Shivani Sachdeva^{1,*}, Shubhangi Mani³, Ashmita Lade², Tanupriya Sonkar⁴

¹Dept. of Periodontology, Rural Dental College, Pravara Institute of Medical Sciences, Loni, Maharashtra, India

²Dept. of Oral and Maxillofacial Surgery, Rural Dental College, Pravara Institute of Medical Sciences, Loni, Maharashtra, India

³Dept. of Orthodontics, Rural Dental College, Pravara Institute of Medical Sciences, Loni, Maharashtra, India

⁴Dept. of Prosthodontics, Rural Dental College, Pravara Institute of Medical Sciences, Loni, Maharashtra, India



ARTICLE INFO

Article history:

Received 29-06-2020

Accepted 21-12-2020

Available online 15-01-2021

Keywords:

Attached gingiva

Periodontium

Periodontitis

ABSTRACT

Reduced width can cause inflammation more frequently leading to recession. Increase in width of attached gingiva can be done by free gingival grafts, connective tissue grafts, guided tissue regeneration or acellular dermal matrix (ADM). Though, ADM has advantage that it doesnot create a donor site but, it is costly and shrinkage is more in comparison to connective tissue graft. The present case report is of female patient with reduced width of attached gingiva which causes blanching and sensitivity of teeth.

© This is an open access article distributed under the terms of the Creative Commons Attribution License (<https://creativecommons.org/licenses/by/4.0/>) which permits unrestricted use, distribution, and reproduction in any medium, provided the original author and source are credited.

1. Introduction

Gingival recession is the apical shift of the gingival margin leading to exposed root surfaces, resulting in an unaesthetic appearance¹. The denuded roots become more sensitive, prone to caries and unaesthetic. The two major objectives of gingival augmentation are to cover either the root surfaces or to increase the width of attached gingiva. There are different treatment modalities to increase the width of attached gingiva such as pedicle graft, free gingiva graft (FGG), connective tissue grafts (CTG), guided tissue regeneration, using alloderm membrane etc. but the preferred one is connective tissue graft if compared to other autografts due to double blood supply; one from underlying periosteum and other from the graft from the donor site. Sometimes, shallow palatal vault hinders in the uptake of CTG graft so one has to look for other modalities. The present case report is class III Miller's recession in lower anteriors and complains of sensitivity in teeth and gradual drifting of gingiva apically.

* Corresponding author.

E-mail address: dr.shivani19@gmail.com (S. Sachdeva).

2. Case Report

The present case report is of female patient 44 years who came to outpatient department of Periodontics with the chief complaint of sensitivity and gradual apical migration of lower central incisors. Clinical attachment loss was 7-8 mm with lower central incisors with 3mm of pocket depth. It was a class III Miller's recession. We had planned soft tissue augmentation with mandibular anteriors apically with the aim of increasing width of attached gingiva but not root coverage.

2.1. Treatment protocol

It constituted of scaling and root planing which were performed along with frenectomy at the first sitting. After 4 weeks patient was recalled for gingival augmentation apical to area of recession.

Recipient site was prepared by de-epithelization of overlying buccal gingiva sparing interdental papillae. Measurements of bed were taken with UNC #15 probe and

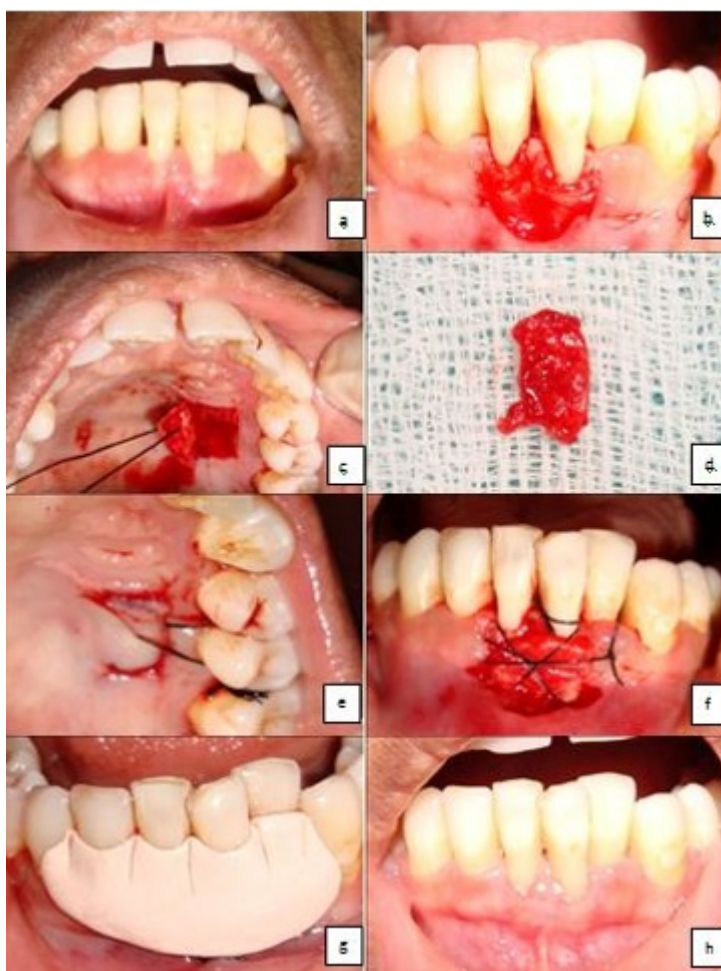


Fig. 1: a) Reduced width of attached gingiva with mandibular anteriors with high frenum attachment and blanching of gingival; b) Recipient bed preparation; c) Donor site extending from first premolar to second premolar through trap door technique; d) Connective tissue procured; e) Donor site sutured; f) Graft stabilized and secured with sutures; g) Coe-pak given h) Follow up 1 year with increased width of attached gingiva

accordingly the bleeder points were inculcated on the palate on the left side from mesial of first premolar where the rugae ended extending till mesial of first molar. This would help to achieve the graft of uniform and maximum thickness.

Trap door technique was followed where one horizontal and two vertical incisions were given using blade #15. The graft was procured of uniform thickness of approx. 1mm and the epithelial flap was placed in position and sutured with silk sutures. The connective tissue graft was secured with sling, periosteal and circumferential sutures on the recipient site. The coe-pak dressing was given and recall was done at 2 weeks, 1 month and 1 year. The healing occurred through primary intention on the donor site unlike FGG. Follow up of one year showed increased width of attached gingiva apical to area of recession along with no blanching negative tension depicted in Figure 1.

3. Discussion

Adequate width of attached gingiva is prerequisite for implant site selection in this modern era of implant dentistry. Though there are many different school of thoughts for adequate width of attached gingiva but the two most popular are by Lang and L oe who suggested that 2 mm of gingiva is an essential prerequisite for periodontal health² and the other by Miyasato et al. demonstrated that, with proper oral hygiene and absence of bacterial plaque, clinically healthy gingiva can exist in areas with minimal or no attached gingiva.³

The connective tissue graft (CTG) has gained considerable attention and is considered a gold standard for soft tissue augmentation. The palatal graft tissue has thicker masticatory mucosa which is mostly the site of choice for harvesting the graft. There are few anatomical considerations to be followed to avoid injury to

neurovascular bundle (NB). One of most important factor is palatal vault.

Reiser Gary mentioned that the retrieval of donor tissue from the premolar region in the high and average palate offers a greater margin at safety than retrieval from the shallow (flat) palatal vault.”⁴ The Table 1 classifies the palatal vault by measuring the Distance between the CEJ and the neurovascular bundle (NB).

Table 1: Classification of palatal vault⁴

Classification	Shape	CEJ-NB
High palate	U-shaped	17mm
Average palate	Flat	12 mm.
Shallow palate	Shallow	7 mm

The other consideration is thickness of graft. The graft should not be thinner than 0.75 mm and not thicker than 1.5mm. The thickest tissue can be procured from in the area from mesial line angle of the palatal root of the first molar till distal line angle of the canine. In the present case CTG was preferred over FGG and alloderm membrane for soft tissue augmentation because of following advantages better healing postoperatively, dual blood supply, colour matching, less shrinkage of tissue and hence more width of Keratinized tissue (KT) can be achieved.

In accordance to our case there are supportive studies by Harris (1988)⁵ and Wei (2007).⁶ In both the clinical trials increase in keratinized tissue from CT grafts was more than alloderm membrane group.

4. Conclusion

The connective graft is the gold standard for increasing the attached gingiva in both high and average vault conditions. In spite, of knowing the significance of adequate width of attached gingiva the acceptance of increasing width is less in implant dentistry which might be due to issues of improper diagnosis and deficiency in time. So, it is of supreme significance in era of implant dentistry and full mouth rehabilitation cases. As the prevalence of periimplantitis and peri mucositis is tremendously increasing day by day. Hence, every clinician placing implants should be aware and give a referral call for a periodontist or oral surgeon before implant placement.

5. Source of Funding

None.

6. Conflict of Interest

The authors declare no conflict of interest.

References

- Allen EP. Use of mucogingival surgical procedures to enhance esthetics. *Dent Clin North Am.* 1988;32:307–30.
- Lang NP, Loe H. The relationship between the width of keratinized gingiva and gingival health. *J Periodontol.* 1992;43:623–7.
- Miyasato M, Crigger M, Egelberg J. Gingival condition in areas of minimal and appreciable width of keratinized gingival. *J Clin Periodontol.* 1977;4(3):200–9. doi:10.1111/j.1600-051x.1977.tb02273.x.
- Reiser G, Bruno JF, Mahan PE, Larkin L. The Subepithelial Connective Tissue Graft Palatal Donor Site: Anatomic Considerations for Surgeons. *Int J Periodont Rest Dent.* 1996;16:131–7.
- Harris RJ. Root coverage with a connective tissue with partial thickness double pedicle graft and an acellular dermal matrix graft: A clinical and histological evaluation of a case report. *J Periodontol.* 1988;69:1305–11.
- Wei PC, Laurell L, Geivelis M, Lingen MW, Maddalozzo D. Acellular dermal matrix allografts to achieve increased attached gingival. Part 1. A clinical study. *J Periodontol.* 2007;11:1297–1355.

Author biography

Ameet Mani, Professor

Harish Saluja, Professor

Shivani Sachdeva, Reader

Shubhangi Mani, Professor

Ashmita Lade, Senior Lecturer

Tanupriya Sonkar, Senior Lecturer

Cite this article: Mani A, Saluja H, Sachdeva S, Mani S, Lade A, Sonkar T. Width of attached gingiva an important consideration for periodontium- A case report and literature review. *IP Int J Maxillofac Imaging* 2020;6(4):112-114.