



Original Research Article

Variations in root canal morphology of the permanent mandibular first molar in Indian population- A CBCT study

Rhea Reji John¹, Vasavi Santosh^{1,*}, Mandavi Waghmare¹, Reema Manoj¹

¹Dept. of Oral Medicine & Radiology, D Y Patil University School of Dentistry, Navi Mumbai, Maharashtra, India



ARTICLE INFO

Article history:

Received 26-05-2021

Accepted 15-06-2021

Available online 14-07-2021

Keywords:

Oral submucous fibrosis

Radiographic evaluation

Morphology of soft palate

ABSTRACT

Aim and Objective: The purpose of this study was to determine the variations in the number of canals and its morphology in permanent mandibular first molars using cone-beam computed tomography (CBCT) in a subset of Indian population.

Materials and Methods: A total of 350 CBCT scans were collected and evaluated in all three orthogonal planes to determine the number of root canals and study their anatomic variations using Vertucci's classification.

Statistical Analysis used: The total number of roots and root canals, the root canal configuration, the incidence, and the correlations between left- and right-side occurrences and between males and females were analysed. Statistically significant differences were evaluated using the chi-square test with SPSS 16.0 for Windows (SPSS, Chicago, IL), with significance set at $p < 0.05$.

Result: The results of this study showed that predominantly, two thirds of the subjects had type VI mesial canal configuration and two-thirds had type I distal canal configuration. Also there was significant variance in the canal anatomy across gender and age of the subjects.

Conclusion: CBCT is a clinically useful tool in understanding the variations in root canal morphology, which guides in the assessment of the canal morphology aiding in successful root canal treatment.

© This is an open access article distributed under the terms of the Creative Commons Attribution License (<https://creativecommons.org/licenses/by/4.0/>) which permits unrestricted use, distribution, and reproduction in any medium, provided the original author and source are credited.

1. Introduction

A detailed knowledge of the root canal morphology and its variation is an essential prerequisite for successful endodontic diagnosis and treatment.¹ The goal of root canal treatment is thorough mechanical and chemical clearing of the entire pulp cavity, its 3D obturation with an inert material and the attainment of a proper hermetic coronal seal to prevent microorganism intrusion. The most common reason for endodontic failure has been recognised as the lack of thorough knowledge about root canal anatomy.²

The permanent mandibular first molar (PMFM) generally has two separate roots with a round, or more frequently elliptical canal in the distal root and two canals in the mesial root. The distal canal is normally straight all the way

to the apex, oval or flattened in cross-section, but quite large which makes instrumentation easy. Regarding mesial root, in 90% they remain separate as far as the foramen; in the remaining 10%, they join together at a common foramen. Studies done in vitro and in vivo have indicated that mandibular molars can have more than three root canals. The PMFM have been reported to have three roots, mesial and distal roots with three canals each or molar with 5, 6, or more canals.³ Root canal morphologies have been analysed by using many methods in earlier studies including use of hematoxylin dye, decalcification and diaphanization techniques, use of electron microscopy, canal staining and clearing technique and micro computed tomography.⁴

However, drawbacks of these techniques in detecting the variations in the canals have directed to the use of 3D techniques to analyse variations. 3D imaging has facilitated the clinician with better insight into tooth morphology along

* Corresponding author.

E-mail address: sanvas72@yahoo.com (V. Santosh).

with interactive image manipulation.⁵

Inherent genetic variations are seen in the root canal anatomy. Variance from different population groups have been cited in literature, but however literature lacks study on Indian population. Hence this study was taken up to evaluate the variations in root canal anatomy of PMFM in a subset of Indian using CBCT imaging.

2. Materials and Methods

450 CBCT scans were scrutinized and diagnostic images of patients aged above 10 yrs with fully matured apices of healthy permanent mandibular molars were selected from the data base of the oral and maxillofacial radiology unit of our institute. Carious, fractured teeth and teeth with periapical lesions or calcifications were eliminated from the study. 350 scans were finally selected to be included in the study.

These CBCT scans were taken using a KODAK CS9000 3D unit with a FOV of 5 X 3.5cm (Care stream Health Inc. NY 14608, USA).

Reformatted axial, coronal, sagittal sections of PMFM images were analysed for root canal configuration in both mesial and distal roots at 200 μ resolution and categorised according to Vertucci's classification (Figure 1). All the images were obtained in the Digital Image Communication in Medicine (DICOM) format and assessed using the Kodak Dental Imaging Software (KDIS).

The images were assessed separately by two residents in oral and maxillofacial radiology and any disagreement was discussed until a consensus was reached.

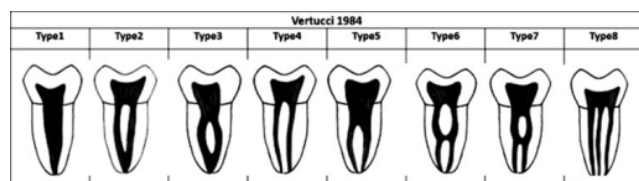


Fig. 1: Vertucci's classification of root canal system

3. Results

52.9% was male cohort and 47.1% was female cohort in the study, with slightly more number of samples of 46 (50.6%) compared to 36 (49.4%).

In the mesial root, incidence of type 6 was seen in 65.4%, followed by type 4 in 33.4%. However, incidence of type 2 canal was very low, only 1.1%. Type 4 mesial canal was more common among males (36.8%) than females (29.7%) whereas type 6 (67.9%) was more common in females and type 1, 3 and 5 were not seen in the mesial root. Statistically significant difference was seen between the genders in respect to the mesial canal (Table 1). We found a statistically insignificant association between the

right and left PMFMs with the type of mesial root canal (Table 2). Age cohorts were formed in a manner such that there was an equal distribution of the samples in each group. Type 6 canal in mesial root was seen prominently across all the age groups. (Table 3)

In the distal root, incidence of type 1 was 64% followed by type 2 (17.1%), type 3 (1.7%), type 4 (6.9%) and type 5 (10.3%). Type 1 canal is seen in almost two-thirds of both males and females whereas type 2 and type 5 canal is slightly more common among males than females. We found a significant variance in the type of canal in distal root across the gender (Table 4). However, statistically insignificant association was seen between the right and left PMFMs and type of distal root canal. (Table 5)

Type 1 distal canal was found to be most prevalent across all age groups but a higher percentage of incidence was seen in the age groups of 10-22 and from 33-70; the variance being statistically significant. (Table 6)

4. Discussion

The advent of CBCT has made it possible to visualise the dentition, the maxillofacial skeleton, and the relationship of anatomic structures in three-dimensions.⁶ Significantly increased use of CBCT is evidenced by a recent Web-based survey of active AAE members in the U.S. and Canada which found that the most frequent use of CBCT was for diagnosis of pathosis, preparation for endodontic treatment or endodontic surgery, and for assistance in the diagnosis of trauma related injuries.⁷

CBCT provides clinicians with three-dimensional information about the external and internal morphology of the root and canal systems.

A comparative evaluation of canal staining techniques, CBCT, peripheral quantitative computed tomography, spiral computed tomography, plain and contrast medium enhanced digital radiography has shown that CBCT and pQCT are as accurate as gold standard in identifying the root canal configuration.⁷

In addition, root canal contours studied with CBCT showed very high correlation to histological sections⁸ and to operating microscopes⁹ providing a realistic prognosis prior to commencing treatment.

Many studies have been undertaken in various ethnic groups to analyse the canal configuration of PMFM. This study was carried out on the institutional population representing a population of Indian origin, study using CBCT on this population is not reported in literature to the best of our knowledge.

We found that more than two-thirds of the patients had type 6 mesial canal configuration in PMFM and about one third had type 4 whereas type 2 was found to be relatively very low. In the distal canal, two-thirds had type 1 followed by type 2; type 3, 4 and 5 was found to be lower than 10%.

Table 1: Crosstab across gender for mesial root canal configuration

			Gender		Total
			Male	Female	
Mesial	2	count	0	4	4
		%within sex	0%	2.4%	1.1%
	4	count	68	49	117
		%within sex	36.8%	29.7%	33.4%
	6	count	117	112	229
		%within sex	63.2%	67.9%	65.4%
Total	count	185	165	350	
	%within sex	100.0%	100.0%	100.0%	

P- 0.048

Table 2: Crosstab across tooth for mesial root canal configuration

			Tooth number		Total
			36	46	
Mesial	2	count	4	0	4
		%within tooth no.	2.3%	.0%	1.1%
	4	count	57	60	117
		%within tooth no.	32.9%	33.9%	33.4%
	6	count	112	117	229
		%within tooth no.	64.7%	66.1%	65.4%
Total	count	173	177	350	
	%within tooth no.	100.0%	100.0%	100.0%	

P- 0.126

Table 3: Crosstab across age groups for mesial canal configuration

		Mesial			T total
		2	4	6	
1	10-22	count	1	20	68
		%within age	1.5%	29.4%	69.1%
2	23-27	count	0	30	73
		%within age	.0%	41.1%	58.9%
3	28-32	count	1	29	68
		%within age	1.5%	42.6%	55.9%
4	33-42	count	2	26	80
		%within age	2.5%	32.5%	65.0%
5	43-70	count	0	12	61
		%within age	.0%	19.7%	80.3%
Total		count	4	117	350
		%within age	1.1%	33.4%	65.4%

P- 0.099

Using radiographs on Indian population authors have found type 2 as the most common in both mesial and the distal root.¹⁰ Clearing technique has shown type 4 to be the most prevalent in mesial root and type 1 in distal root.¹¹

A study on Burmese inhabitants showed that majority had type 1 in distal root whereas type 2 and 4 were prevalent in the mesial root.¹²

South-Asian Pakistani nationals had type 2,4,6 in mesial root and type 1 or 5 in distal.¹³ Zhang R concluded that the Chinese population had most distal roots with type 1 canal whereas mesial roots had more complex canal systems with more than one canal.¹⁴ The denizens of Spain had 2 as

the most frequent configuration in mesial root and type 1 and 4 in distal root¹⁵ whereas Ahmed HA¹⁶ concluded that in the Sudanese population, 59% PMFMs had four canals. Inhabitants of Turkey had predominantly type 4 in mesial root and type 1 in distal root.¹⁷⁻¹⁹

All these above studies show that the configuration of the root canal system in PMFM shows high diversity appearing with different frequencies in different ethnicities.

However, most of the population showed type 1 to be the most prevalent in the distal canal.

In contrast, comparing the configuration in the mesial canal, most of the population studies showed type 4 to be

Table 4: Crosstab across gender for distal canal configuration

	Type of canal		Gender		Total
			Male	Female	
Distal	1	count	121	103	224
		%within sex	65.4%	62.4%	64.0%
	2	count	36	24	60
		%within sex	19.5%	14.5%	17.1%
	3	count	2	4	6
		%within sex	1.1%	2.4%	1.7%
	4	count	6	18	24
		%within sex	3.2%	10.9%	6.9%
	5	count	20	16	36
		%within sex	10.8%	9.7%	10.3%
Total	count	185	165	350	
	%within sex	100.0%	100.0%	100.0%	

P- 0.043

Table 5: Crosstab across tooth number for distal canal configuration

	Type of canal		Tooth number		Total
			36	46	
Distal	1	count	113	111	224
		%within tooth no.	65.3%	62.7%	64.0%
	2	count	28	32	60
		%within tooth no.	16.2%	18.1%	17.1%
	3	count	4	2	6
		%within tooth no.	2.3%	1.1%	1.7%
	4	count	11	13	24
		%within tooth no.	6.4%	7.3%	6.9%
	5	count	17	19	36
		%within tooth no.	9.8%	10.7%	10.3%
Total	count	173	177	350	
	%within tooth no.	100.0%	100.0%	100.0%	

P-0.881

Table 6: Crosstab across age groups for distal canal configuration

Age group	Age		Distal					Total
			1	2	3	4	5	
1	10-22	count	47	8	0	6	7	68
		%within age	69.1%	11.8%	.0%	8.8%	10.3%	100.0%
2	23-27	count	37	19	4	6	7	73
		%within age	50.7%	26.0%	5.5%	8.2%	9.6%	100.0%
3	28-32	count	37	11	1	5	14	68
		%within age	54.4%	16.2%	1.5%	7.4%	20.6%	100.0%
4	33-42	count	59	11	1	2	7	80
		%within age	73.8%	13.8%	1.3%	2.5%	8.8%	100.0%
5	43-70	count	44	11	0	5	1	61
		%within age	72.1%	18.0%	.0%	8.2%	1.6%	100.0%
Total		count	224	60	6	24	36	350
		%within age	64.0%	17.1%	1.7%	6.9%	10.3%	100.0%

P- 0.007

the predominant type followed by type 2 whereas this study showed type 6 with the highest frequency.

Such high frequency of type 6 was not seen in any other study done either in the Indian population or in any South Asian population. The high prevalence of type 6 could be due to the vast latitude of age group included in this study as it was found in higher frequency both in the younger as well as the older age group. Type 6 has intercanal communication in the middle third which can be easily detected in CBCT scans.

Authors have reported that inter-canal communications are more common in the mesial roots¹⁶ which are similar to results found in this study where type 6 was most common in mesial root. Endodontic therapy for these type of canals is comparatively more complicated than the simple tubular and tapered canals.¹⁷

Peiris²⁰ concluded that the canal systems are completely defined by 30-40 yrs and intercanal communications are less prevalent in younger and older groups but high at intermediate ages. However, we found a higher frequency in young as well as older age group.

Results of this study show a significant variance in the type of canal in distal root across the gender which were unlike the results derived by Berkan Celikter et al.²¹

Studies comparing the left and the right PMFM was not found in the literature. Though it did not show any statistical significance it was seen that some types were slightly predominant over the others either in the right or the left.

Successful endodontic therapy is dependent on identification of all root canals followed by proper cleaning, shaping and obturation of all canals. Most often radiographs may not show the presence of all canals within the root, especially in the buccolingual plane.

In several cases, endodontic procedures fail due to varied canal anatomy. We have seen that PMFM has varied anatomy in both mesial and distal canals, which have been reliably detected due to the use of high resolution focused CBCT. The selection of the most appropriate imaging protocol for the diagnostic task at hand is paramount.

Hence we conclude that knowledge of CBCT will help clinicians to visualize the complex root canal anatomy and improve treatment outcome.

5. Limitations

One significant problem, which can affect the image quality and diagnostic accuracy of CBCT images is the scatter and beam hardening caused by high density neighbouring structures, such as enamel, metal posts and restorations. If this scattering and beam hardening is associated close to or with the tooth being assessed, the resulting CBCT images may be of minimal diagnostic value. In clinical endodontic practice, CBCT scanners with a limited field of view will provide clearer images as they will avoid scanning

structures outside the region of interest susceptible to beam hardening (e.g., metallic restorations, dental implants).

6. Conclusion

The authors conclude that PMFM shows high degree of variations in the canal system as well as differences exist between the gender and across the age of the individual. In the subset of Indian population studied, more than two-thirds of the subjects had type 6 mesial canal configuration and two-thirds had type 1 in the distal root. CBCT plays a phenomenal role in diagnosis and treatment planning facilitating image guidance in operative and surgical procedures.

7. Source of Funding

None.

8. Conflict of Interest

The authors declare that there is no conflict of interest.

References

1. Amardeep NS, Raghu S, Natanasabapathy V. Root canal morphology of permanent maxillary and mandibular canines in Indian population using cone beam computed tomography. *Anat Res Int*. 2014;2014:731859. doi:10.1155/2014/731859.
2. Llana C, Fernandez J, Ortolani PS, Forner L. Cone-beam computed tomography analysis of root and canal morphology of mandibular premolars in a Spanish population. *Imaging Sci Dent*. 2014;44(3):221–7.
3. Ballullaya SV, Vemuri S, Kumar PR. Variable permanent mandibular first molar: Review of literature. *J Conserv Dent*. 2013;16(2):99–110. doi:10.4103/0972-0707.108176.
4. Altunsoy M, Ok E, Nur BG, Aglarci OS, Gungor E, Colak M. A Cone Beam Computed Tomography Study of Anterior Teeth in the Turkish Population. *Eur J Dent*. 2014;8(3):302–6.
5. Gaurav V, Srivastava N, Rana V, Adlakha VK. A study of root canal morphology of human primary incisors and molars using cone beam computerized tomography: an in vitro study. *J Indian Soc Pedod Prev Dent*. 2013;31(4):254–9.
6. Neelakantan P, Subbarao C, Subbarao CV. Comparative Evaluation of Modified Canal Staining and Clearing Technique, Cone-Beam Computed Tomography, Peripheral Quantitative Computed Tomography, Spiral Computed Tomography, and Plain and Contrast Medium-enhanced Digital Radiography in Studying Root Canal Morphology. *J Endod*. 2010;36(9):1547–51. doi:10.1016/j.joen.2010.05.008.
7. Estrela C, Bueno MR, Leles CR, Azevedo B, Azevedo JR. Accuracy of Cone Beam Computed Tomography and Panoramic and Periapical Radiography for Detection of Apical Periodontitis. *J Endod*. 2008;34(3):273–9. doi:10.1016/j.joen.2007.11.023.
8. Huang CC, Chang YC, Chuang MC, Lai TM, Lai JY, Lee BS, et al. Evaluation of Root and Canal Systems of Mandibular First Molars in Taiwanese Individuals Using Cone-Beam Computed Tomography. *J Formos Med Assoc*. 2010;109(4):303–8.
9. Park JB, Kim N, Park S, Kim Y, Ko Y. Evaluation of Root Anatomy of Permanent Mandibular Premolars and Molars in a Korean Population with Cone-Beam Computed Tomography. *Eur J Dent*. 2013;7(1):94–101.
10. Goel NK, Gill KS, Taneja JR. Study of Root Canal Configuration in Mandibular First Permanent Molar. *J Indian Soc Pedod Prev Dent*. 1991;8(1):12–4.

11. Chourasia HR, Meshram GK, Warhadpande M, Dakshindas D. Root Canal Morphology of Mandibular First Permanent Molars in an Indian Population. *Int J Dent*. 2012;2012:745152. doi:10.1155/2012/745152.
12. Gulabivala K, Aung TH, Alavi A, Ng YL. Root Canal Morphology of Burmese Mandibular Molars. *Int Endod J*. 2001;34(5):359–70.
13. Wasti F, Shearer AC, Wilson NHF. Root canal systems of the mandibular and maxillary first permanent molar teeth of South Asian Pakistanis. *Int Endod J*. 2001;34(4):263–6. doi:10.1046/j.1365-2591.2001.00377.x.
14. Zhang R, Wang H, Tian YY, Yu X, Hu T, Dummer PMH. Use of cone-beam computed tomography to evaluate root and canal morphology of mandibular molars in Chinese individuals. *Int Endod J*. 2011;44(11):990–9. doi:10.1111/j.1365-2591.2011.01904.x.
15. Pablo O, Abadal JM, Estevez R, Moreno F, Zaballos TP, Sanchez MP. CBCT study of root canal morphology of mandibular first molars in a Spanish population. *Res Root Canal Morphol*. 2012;43(1):15–27.
16. Ahmed H. Root and Canal Morphology of Permanent Mandibular Molars in a Sudanese Population. *Int Endod J*. 2007;40(10):766–71.
17. Demirbuga S, Sekerci AE, Dincer AN, Cayabatmaz M, Zorba YO. Use of cone-beam computed tomography to evaluate root and canal morphology of mandibular first and second molars in Turkish individuals. *Med Oral Patol Oral Cirurgia Bucal*. 2013;18(4):e737–44. doi:10.4317/medoral.18473.
18. Nur BG, Ok E, Aglarci OS, Colak M, Gungor E. Evaluation of the Root and Canal Morphology of Mandibular Permanent Molars in a South-Eastern Turkish Population Using Cone-Beam Computed Tomography. *Eur J Dent*. 2014;8(2):154–9.
19. Chhabra S, Yadav S, Talwar S. Analysis of C-shaped canal systems in mandibular second molars using surgical operating microscope and cone beam computed tomography: A clinical approach. *J Conserv Dent*. 2014;17(3):238–43. doi:10.4103/0972-0707.131785.
20. Peiris HRD, Pitakotuwage TN, Takahashi M, Sasaki K, Kanazawa E. Root canal morphology of mandibular permanent molars at different ages. *Int Endod J*. 2008;41(10):828–35. doi:10.1111/j.1365-2591.2008.01428.x.
21. Celikten B, Tufenkci P, Aksoy U, Kalender A, Kermeoglu F, Dabaj P, et al. Cone beam CT evaluation of mandibular molar root canal morphology in a Turkish Cypriot population. *Clin Oral Investig*. 2016;20(8):2221–6. doi:10.1007/s00784-016-1742-2.

Author biography

Rhea Reji John, Ex PG Student

Vasavi Santosh, Professor

Mandavi Waghmare, Professor and HOD

Reema Manoj, Associate Professor

Cite this article: John RR, Santosh V, Waghmare M, Manoj R. Variations in root canal morphology of the permanent mandibular first molar in Indian population- A CBCT study. *IP Int J Maxillofac Imaging* 2021;7(2):61-66.