

Content available at: <https://www.ipinnovative.com/open-access-journals>

IP International Journal of Maxillofacial Imaging

Journal homepage: <https://www.ijmi.in/>

## Original Research Article

## Comparative evaluation of canal transportation and centering ability between 4% and 6% rotary files using cone beam computed tomography — An invitro study

P. Hemalatha<sup>1,\*</sup>, V. Sanjana<sup>1</sup>, Prabeesh Padmanabhan<sup>1</sup>, M. Muthalagu<sup>1</sup>,  
M. Shahul Hameed<sup>1</sup>

<sup>1</sup>Dept. of Conservative Dentistry and Endodontics, Best Dental Science college and Hospital, Madurai, Tamil Nadu, India



## ARTICLE INFO

## Article history:

Received 04-10-2021

Accepted 11-11-2021

Available online 25-01-2022

## Keywords:

Cone beam computed tomography

Postinstrumentation

## ABSTRACT

**Aim:** Aim of the study was to evaluate the canal transportation and centering ability of 4% and 6% rotary systems by cone beam computed tomography (CBCT).

**Materials and Methods:** Sixty permanent mandibular first molar mesio-buccal canals were chosen and divided into two groups (n=30) according to the bio mechanical preparation method used: Vortex blue and XP Endo Shaper. After placing on a customized wax sheet substrate, the samples were scanned using CBCT and then subjected to instrumentation according to the group selected. Then post instrumentation CBCT was taken. Slices from the axial slice were obtained at 3 mm, 6 mm, and 9 mm from the root apex, corresponding to the apical, middle, and coronal thirds, respectively, from both exposures.

**Results:** The results showed that there were no statistically significant differences in canal centering and transportation between both the groups. However vortex blue group showed less transportation and less amount of untouched dentin.

**Conclusion:** It was concluded that " 6% taper group though having higher taper showed better centering ability and less amount of untouched dentin and 4% taper file group though an adaptive core technology showed more transportation because of its non-uniform expansion to thermal changes.

This is an Open Access (OA) journal, and articles are distributed under the terms of the [Creative Commons Attribution-NonCommercial-ShareAlike 4.0 License](https://creativecommons.org/licenses/by-nc-sa/4.0/), which allows others to remix, tweak, and build upon the work non-commercially, as long as appropriate credit is given and the new creations are licensed under the identical terms.

For reprints contact: [reprint@ipinnovative.com](mailto:reprint@ipinnovative.com)

### 1. Introduction

The fundamental goal of any root canal preparation is to increase the root canal space in order to allow antibacterial disinfection or to avoid (re-)infection by placing a fluid-tight root canal filling in conjunction with a suitable coronal restoration.<sup>1</sup> There are many concepts, methods, and procedures for preparing root canals since the beginning of contemporary endodontics, and one of the goals in root canal preparation is to produce a form that tapers from coronal to apical while retaining the original canal shape.<sup>2</sup>

Regardless of the file design, the amount of tools required, and the surprising variety of procedures

advocated, endodontic therapy has traditionally been treated with hope for likely success, particularly in curved root canals. Several procedural mistakes can arise during the shaping of curved root canals, including apical transportation, zips, ledges, root perforations, loss of working length, root canal straightening, or departure from the original course.<sup>3</sup>

The use of increasingly larger diameter files during root canal enlargement reduces the angle of curvature due to the propensity to migrate toward the root canal's outer wall, resulting in a non-instrumented inner dentine wall in the apical third, which may mean a worse prognosis for treatment.<sup>4</sup>

The incorporation of nickeltitanium (NiTi) files for canal shaping was a breakthrough in clinical endodontics, which

\* Corresponding author.

E-mail address: [hemaendo@gmail.com](mailto:hemaendo@gmail.com) (P. Hemalatha).

had previously relied on a long sequence of stainless steel (SS) hand files and numerous rotating gateslidden drills.<sup>5</sup>

NiTi files can be inserted in curved root canals with less lateral force on the root canal walls because they have a lower modulus of elasticity. However, NiTi has a propensity to straighten, especially in instruments with a larger taper and tip, which negates this benefit.<sup>6</sup>


Centric ability is the ability of an instrument to remain centered in the canal, thus preserving the canal anatomy.<sup>7</sup> Transportation is defined within The Glossary of Endodontic Terms as removal of the root canal dentin on the outer wall of the curve within the apical half of the canal as a result of the tendency of instruments to regain their original straight shape during canal preparation.<sup>8</sup>

Several investigations have revealed that when stiffness rose, the incidence of transportation in the apical area of canals increased as well. The amount of force required to bend a file is greatly affected by nickel-titanium instruments with a higher taper, reducing the file's flexibility. The research Influence of Taper on the Flexibility of Nickel-Titanium Rotary Files by Christopher J. Kingma found that greater taper files are stiffer than 0.04 mm files, leading in a higher chance of canal transportation.<sup>9</sup>

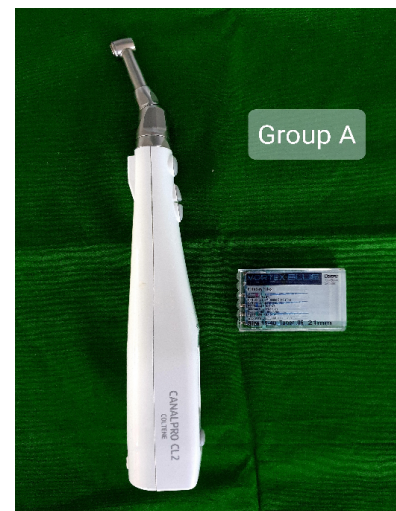
Radiographic imaging, cross-sectioning and longitudinal cleavage of the samples were previously employed to assess canal transportation. It's possible that the latter procedures will result in sample loss. New imaging techniques like Computed Tomography, Micro-CT (Micro Computed Tomography), and CBCT (Cone beam computed tomography) have pitched in which have given a new dimension to the endometrics. Because of their non-destructive nature and ability to get accurate linear measurements, these techniques have produced acceptable and repeatable results. They also calculate the amount of dentin that has been removed following instrumentation.<sup>10</sup>

CBCT is a high-resolution imaging technique that may be used to assess root canal morphology, fractures, and changes in the root canal system after preparation. The current investigation employed CBCT because it is a non-invasive imaging technique that allows for reliable and repeatable three-dimensional evaluation of the root canal system without causing damage to the samples. On CBCT scans, there are two techniques for measuring canal transit. Some investigators superimposed the pre- and postoperative images to see how the canal route changed as a result of the preparation. However in our study more precise method is overlapping the pre- and postoperative cross-sectional pictures at three different levels, and measure the distance between the external root surface and internal canal wall at the mesial and distal aspects.

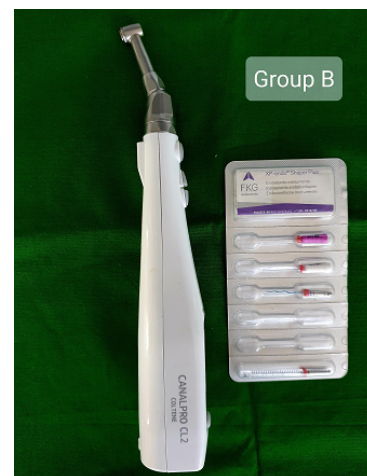
Thus, the study aims to compare the canal transportation, centering ability of 4% and 6% rotary files in curved extracted mesiobuccal root canals of mandibular molars using Cone Beam Computed Tomography.



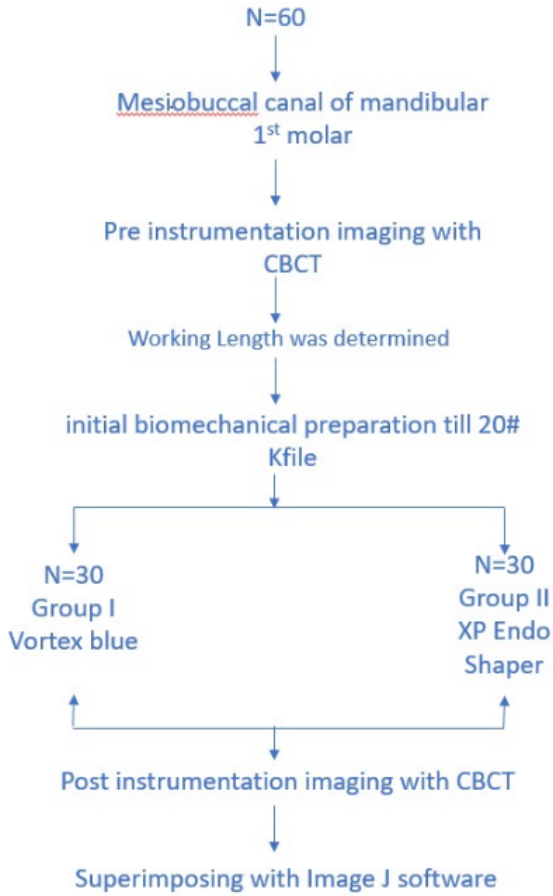
**Fig. 1:** Specimens were embedded in a horse shoe shaped wax sheet blocks




**Fig. 2:** The canals prepared using vortex blue in the sequence of 15/0.06, 20/0.06, 25/0.06, 30/0.06 at a rotational speed of 500 rpm and 3 Ncm torque.



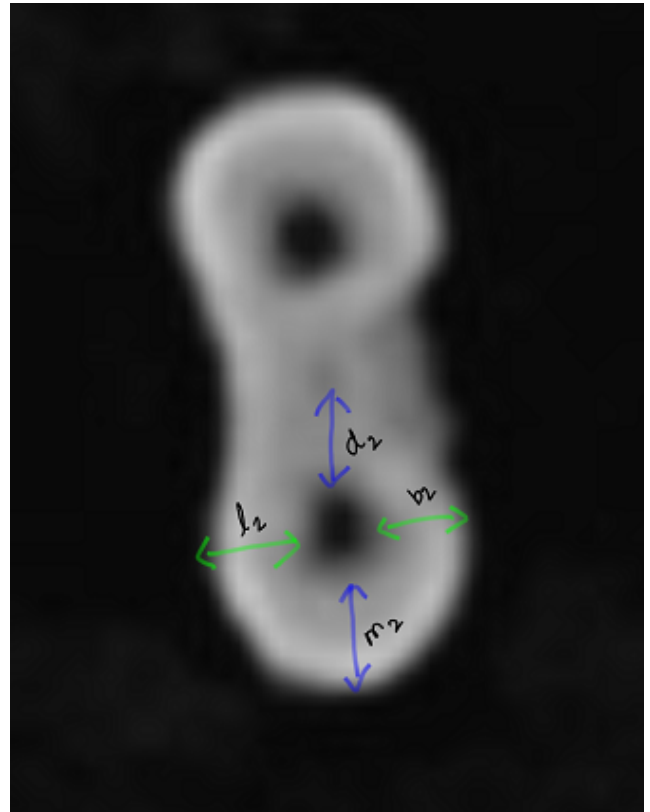
**Fig. 3:** The canals were prepared using XP Endo Shaper file system at a rotational speed of 900 rpm along with torque values of 1Ncm.



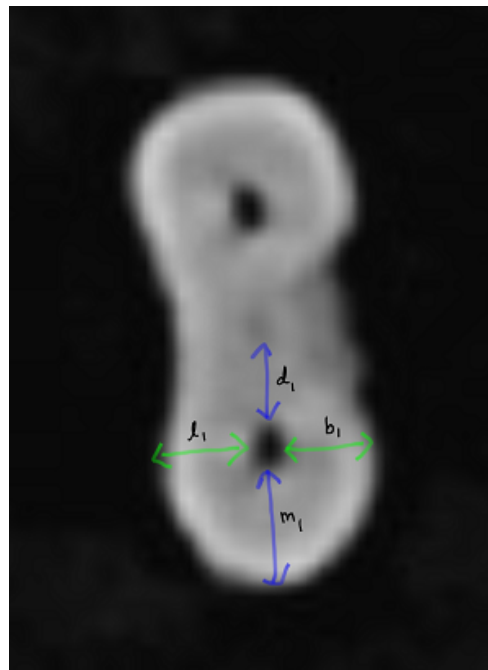
**Fig. 4:** The transportation in the mesiodistal and buccolingual direction was estimated by superimposing pre- and postoperative CBCT images using Image J software at 3mm, 6mm and 9mm from the apex



**Fig. 5:** L2 is the shortest distance from the lingual edge of the root to the lingual edge of the instrumented canal.



**Fig. 6:** L2 is the shortest distance from the lingual edge of the root to the lingual edge of the instrumented canal.



**Fig. 7:** L2 is the shortest distance from the lingual edge of the root to the lingual edge of the instrumented canal.

## 2. Materials and Methods

Recently extracted 60 mandibular first molars with fully formed apices, free from caries, cracks and calcification was selected. The selected teeth were cleaned for tissue fragments and calcified debris with ultrasonic scaler and then stored in 0.1% thymol solution. This study was approved by the Ethical Committee/ Institutional Review Board of Best Dental Science College, Madurai.

All the teeth was subjected to an initial periapical radiographs in mesiodistal and buccolingual directions to determine the root canal morphology. Teeth with calcified canals, internal or external root resorption, cracks, prior root canal treatment, old restoration, and caries were excluded.

The crown of each chosen tooth was removed using a diamond disc at the level of the cementum enamel junction to obtain a 14 mm long mesiobuccal canal, and the specimens were embedded in a horse shoe shaped wax sheet blocks (Figure 1). CBCT imaging was used to capture pre-instrumentation images. Starting at the apical end of the root, all teeth were scanned with their roots perpendicular to a CBCT beam.

A glide path was created using a 10 K file size. Subtract 1 mm from the length at which the file tip extruded apically to get the working length. All canal preparations were done using RC Help (Prime Dental Products Pvt. Ltd.), and the root canals were irrigated with 2 mL 2.5 percent sodium hypochlorite solution after each instrumentation. After initial biomechanical preparation till 20# Kfile, these 60 mesiobuccal roots were divided into two groups. (Figures 2 and 3)

1. Group 1 — the canals were prepared using Vortex blue in the sequence of 15/0.06, 20/0.06, 25/0.06, 30/0.06 at a rotational speed of 500 rpm and 3 Ncm torque.
2. Group 2 - The canals were prepared using XP Endo Shaper file system at a rotational speed of 900 rpm along with torque values of 1Ncm. It has 0.01 taper initially and when heated to body temperature it starts shaping at ISO size 15 and progress to ISO size 30 with a 0.04 taper.

After the use of each file, canal irrigation was performed with 2 mL of 2.25% NaOCl solution. Thirty-gauge irrigation needle was used. After canal preparation, each canal was irrigated with 5 mL of 17% ethylenediaminetetraacetic acid (EDTA) solution for final rinse and then was dried with sterile paper points.

Postinstrumentation CBCT images were obtained with identical values and positions as preinstrumentation images after canal shaping. (Figure 1)

The transportation in the mesiodistal and buccolingual direction was estimated by superimposing pre- and postoperative CBCT images using Image J software at 3mm, 6mm and 9mm from the apex (Figure 4). The dimensions were measured by calculating the shortest distance from the

periphery of the uninstrumented canal to the periphery of the tooth in both mesial distal and buccal lingual directions and then compare it with prepared canals at all the three levels.

The formula used to compute the canal centering ratio at each level:<sup>11</sup>

$$(m1-m2)/(d1-d2) \text{ and } (b1-b2)/(l1-l2)$$

The degree of mesiodistal canal transportation:

$$(m1-m2) - (d1-d2)$$

The degree of buccolingual transportation:

$$(b1-b2) - (l1-l2)$$

Where,

1. M1 is the shortest distance from the mesial edge of the root to the mesial edge of the pre instrumented canal,
2. M2 is the shortest distance from the mesial edge of the root to the mesial edge of the instrumented canal,
3. D1 is the shortest distance from the distal edge of the root to the distal edge of the pre instrumented canal,
4. D2 is the shortest distance from the distal edge of the root to the distal edge of the instrumented canal,
5. B1 is the shortest distance from the buccal edge of the root to the buccal edge of the pre instrumented canal,
6. B2 is the shortest distance from the buccal edge of the root to the buccal edge of the instrumented canal,
7. L1 is the shortest distance from the lingual edge of the root to the lingual edge of the pre instrumented canal,
8. L2 is the shortest distance from the lingual edge of the root to the lingual edge of the instrumented canal. (Figures 5, 6 and 7)

### 2.1. Statistical analysis

The data was expressed in mean and standard deviation. Statistical Package for Social Sciences (SPSS 16.0) version used for analysis. ANOVA (Post hoc) followed by unpaired t test used for analysis. P value less than 0.05 considered statistically significant at 95% confidence interval.

## 3. Results

1. The mean and standard deviation values of the canal transportation and the centering ratio between the groups at 3mm are reported in Table 1.
2. The mean and standard deviation values of the canal transportation and the centering ratio between the groups at 6mm are reported in Table 2.
3. The mean and standard deviation values of the canal transportation and the centering ratio between the groups at 9mm are reported in Table 3.

The Vortex Blue showed optimal centering ability and less canal transportation as compared to XP Endo Shaper.

**Table 1:** Comparison of mean canal transport (mm) values between the groups of 3 mm.

Observation	Group-I (MEAN±SD)	Group-II (MEAN±SD)	df	t value	p value
MDC	1.15±0.37	1.08±0.40	58	0.681	0.498
BLC	1.36±0.63	1.29±0.44	58	0.530	0.598
MDT	0.0004±0.001	0.0001±0.001	58	0.697	0.489
BLT	0.0011±0.003	0.0008±0.001	58	0.402	0.689

(p>0.05 no significant difference compared group-A with group-B)

**Table 2:** Comparison of mean canal transport (mm) values between the groups of 6 mm

Observation	Group-I (MEAN±SD)	Group-II (MEAN±SD)	df	t value	p value
MDC	1.10±0.37	0.99±0.36	58	1.23	0.224
BLC	1.11±0.34	1.16±0.38	58	-0.512	0.611
MDT	0.0001±0.002	-0.0004±0.001	58	1.12	0.267
BLT	0.0003±0.001	0.0006±0.002	58	-0.81	0.418

(p>0.05 no significant difference compared group-A with group-B)

**Table 3:** Comparison of mean canal transport (mm) values between the groups of 9 mm

Observation	Group-I (MEAN±SD)	Group-II (MEAN±SD)	df	t value	p value
MDC	1.20±0.38	1.39±1.12	58	-0.844	0.402
BLC	1.14±0.40	1.25±0.38	58	-1.113	0.270
MDT	0.0006±0.002	0.0009±0.002	58	-0.570	0.571
BLT	0.0000±0.003	0.001±0.001	58	-1.625	0.110

(p>0.05 no significant difference compared group-A with group-B)

#### 4. Discussion

Intraoral radiography is based on the transmission, attenuation, and recording of X-rays on an analogue film or digital receptor, and it necessitates a geometrically optimised X-ray generator, tooth, and sensor to produce a correct projection of the tooth. A two-dimensional (2D) representation of a three-dimensional (3D) object is created. The resultant image may show exposure or geometric defects and be unsatisfactory if any component of the imaging chain process is disrupted. 3D features such as complicated dental anatomy and surrounding structures might make 2D "shadows" harder to understand and contribute to endodontic case non-healing. The most significant benefit of CBCT in endodontics is that it can show anatomic characteristics in 3D that intraoral, panoramic, and cephalometric pictures can't. The projection data is reconstructed using CBCT units to provide interrelational pictures in three orthogonal planes (axial, sagittal, and coronal). Furthermore, because CBCT data reconstruction is done natively on a computer, data may be reoriented in their real spatial connections.

Image data may be sectioned non-orthogonally due to the isotropic structure of the volumetric dataset's generated volume pieces ("voxels"). In multiplanar reformation, most software allows for multiple nonaxial 2D pictures (MPR). Oblique, curved planar reformation (producing "simulated" distortion free panoramic pictures) and serial transplanar reformation (offering cross-sections) are two examples of MPR modes that may be utilised to emphasise specific

anatomic areas for a variety of diagnostic purposes. Zoom magnification, window/level changes, and text or arrow annotation are all possible enhancements. Cursor-driven measuring algorithms give the physician an interactive tool for dimensional evaluation in real time. On-screen measurements are distortion-free and magnification-free.<sup>10</sup>

While shaping files can remove pulp and bacteria, the penetration of irrigants into the apical areas of the roots is the actual measure of canal disinfection. In theory, a well-constructed taper allows irrigating solutions to reach the apical areas of the tooth, which would otherwise go unnoticed. The endodontic literature confirms the validity of this idea in two locations. One is that cleaner canals arise from greater apical diameters. Canals prepared to a #50 ISO diameter, for example, are cleaner than canals prepared to a #30 ISO diameter, according to studies. In general, the larger the canal preparation, the better, as long as the preparation does not risk or induce iatrogenic events. The fact that non-vital teeth with apical disease do not recover at the same pace as live teeth is the second piece of evidence in the endodontic literature supports this theory. This second finding is connected to the first in that optimal shape and cleaning include preparing the proper taper as well as the master apical diameter.<sup>12</sup>

The mandibular first molar's mesiobuccal canal was chosen for this investigation because it is the most challenging canal to treat due to its convoluted course. It exits the pulp chamber in a mesial direction, then switches to a distal direction near the root's centre. The mesiobuccal canal bends to the buccal first, then lingually, from the

proximal viewpoint. The mesiolingual canal is straighter at the top and then bends buccally in the middle third.<sup>13</sup>

Regarding centering ability for group I more amount of dentin was removed in buccolingual direction at 3mm. At 6mm and 9mm there was no statistical difference. Lowest amount of dentin was removed in buccolingual direction at 6mm for group II, more amount of dentin was removed in buccolingual direction at 3mm. At 6mm and 9mm there was no statistical difference. Lowest amount of dentin was removed in buccolingual direction at 6mm.

Comparing both the groups, there was a substantial difference in buccolingual centering ability at the apical third (3mm), which may be related to the presence of a curve coronal to the apical third and a thin taper. Both the groups showed lowest removal of dentin in buccolingual direction at 6mm. This might be attributed to two causes: first, tooth-related variables, since this area indicates the start of curvature, where the file flexes and bends; and second, file-related factors.<sup>14</sup>

Regarding canal transportation, group I showed less transportation mesiodistally at 3mm and group II showed less transportation mesiodistally at 6mm.

#### 4.1. Out of the 30 samples in group I at

1. **3mm** — Mesiodistally, 10 samples had no transportation, 13 had transportation and 7 untouched canals.
  - a. Buccolingually 6 samples had no transportation, 15 had transportation and 6 untouched canals.
2. **6mm** — Mesiodistally, 8 samples had no transportation, 14 had transportation and 8 untouched canals.
  - a. Buccolingually 9 samples had no transportation, 13 had transportation and 8 untouched canals.
3. **9mm** — Mesiodistally, 6 samples had no transportation, 17 had transportation and 7 untouched canals.
  - a. Buccolingually 5 samples had no transportation, 17 had transportation and 8 untouched canals.

#### 4.2. Out of the 30 samples in group II at

1. **3mm** — Mesiodistally, 7 samples had no transportation, 13 had transportation and 10 untouched canals.
  - a. Buccolingually 2 samples had no transportation, 21 had transportation and 7 untouched canals.
2. **6mm** — Mesiodistally, 9 samples had no transportation, 9 had transportation and 12 untouched canals.
  - a. Buccolingually 6 samples had no transportation, 16 had transportation and 8 untouched canals.
3. **9mm** — Mesiodistally, 7 samples had no transportation, 16 had transportation and 7 untouched

canals.

- a. Buccolingually 3 samples had no transportation, 22 had transportation and 5 untouched canals.

Comparing the two groups, group I was better showing less transportation and less number of untouched dentin than group II.

M-wire is used to make VortexBlue files, which have a distinctive blue hue due to the titanium oxide coating.<sup>15</sup> Though the exact manufacturing procedure for this blue alloy has not been revealed, new investigations have offered a plausible reason for the better flexibility and fatigue resistance of this blue alloy when compared to another M-wire alloy. Depending on the processing circumstances, M-wire might contain varying amounts of austenite, martensite, and R-phase. The Blue treatment may affect the proportion of R-phase in M-wire since VortexBlue instruments are more flexible.<sup>16</sup> However, VortexBlue files did not demonstrate a substantial reduction in transportation in spite of its greater taper in the current research. The VB instrument features a triangle cross-section and demonstrates uniform contact with the canal wall throughout rotation, with three contact points.<sup>15</sup>

The XP Endo Shaper file is part of a new generation of rotary files that can extend beyond their original dimensions. Studies reveal that its light weight and expanding characteristics appear to better address the canal's three-dimensional structure while yet enabling debris to escape.<sup>17</sup> This was in contrast to our study in which XP Endo Shaper showed more transportation in mesiobuccal direct at 6mm. Highest amount of dentin removal was seen in XPS group at 9mm. This may be due to non-uniform expansion of the file inside the canal.

Considering the two groups vortex blue group has less amount of untouched dentin than XP Endo Shaper group despite its sequential file system. This states that a single file cannot justify into all the canals and provide proper shaping of the canal.

#### 4.3. Clinical Impact

The amount of dentin that has been removed following instrumentation can be measured using CBCT because of their non-destructive nature and ability to get accurate linear measurements.

Keeping in mind the amount and aggression of dentin removed and the amount of untouched areas in the canal new instruments with new design features can be formulated.

There is a general fact that 4% taper files are more flexible and has less transportation thus preserving more amount of dentin. In chronic infection cases the bacteria may penetrate deeper into the dentinal tubules. In such cases higher taper files can remove more amount of dentin and provide a complete biological results which is not possible

with less taper files. So 6% taper files show better clinical results.

## 5. Conclusion

Within the limitations of this study, it can be concluded that there was no statistically significant difference between the two tested groups. 6% taper group though having higher taper showed better centering ability and less amount of untouched dentin. In comparison to previous systems, the innovative manufacturing process of 6% taper files results in improved shaping ability, resulting in less transportation and better centering ability. 4% taper file group though an adaptive core technology showed more transportation because of its non-uniform expansion to thermal changes. Despite the small sample size, all of the file systems utilised in this investigation demonstrated optimal centric ability and acceptable apical transfer. As a result, further research with a bigger sample size is required to provide more precise results.

## 6. Ethical Approval Code

(2019-STF-BrIV-HEM-0)

## 7. Source of Funding

None.

## 8. Conflict of Interest

None.

## References

- Weine FS, Kelly RF, Lio PJ. The effect of preparation procedures on original canal shape and on apical foramen shape. *J Endod.* 1975;1(8):255–62. doi:10.1016/S0099-2399(75)80037-9.
- Pansheriya E, Goel M, Gupta KD, Ahuja R. Comparative Evaluation of Apical Transportation and Canal Centric Ability in Apical Region of Newer nickel-titanium File Systems Using cone-beam computed tomography on Extracted Molars: An In Vitro Study. *Contemp Clin Dent.* 2018;9(6):215. doi:10.4103/ccd.ccd\_17\_18.
- Peters OA. Current challenges and concepts in the preparation of root canal systems: a review. *J Endod.* 2004;30(8):559–67. doi:10.1097/01.don.0000129039.59003.9d.
- Greene KJ, Krell KV. Clinical factors associated with ledged canals in maxillary and mandibular molars. *Oral Surg Oral Med Oral Pathol.* 1990;70(4):490–7. doi:10.1016/0030-4220(90)90217-g.
- Serene TP, Adams JD, Saxena A. Nickel-titanium instruments : applications in endodontics; 1995. p. 112.
- Torres DU, Rodriguez MPG, Luque CMF. Shaping ability of Mtwo and Twisted File rotary systems in curved root canals. *J Clin Exp Dent.* 2012;4(5):275–80. doi:10.4317/jced.50867.
- Gundappa M, Bansal R, Khoriya S. Root canal centering ability of rotary cutting nickel titanium instruments: A meta-analysis. *J Conserv Dent.* 2014;17(6):504–9. doi:10.4103/0972-0707.144567.
- American Association of Endodontists. Glossary of endodontic terms. In; 2020. Available from: <https://www.aae.org/specialty/clinical-resources/glossary-endodontic-terms/>.
- Christopher J. Influence of taper on the flexibility of nickel-titanium rotary files Marquette University e-Publications@Marquette Master's Theses . 2009; Available from: [https://epublications.marquette.edu/theses\\_open/249/](https://epublications.marquette.edu/theses_open/249/).
- Scarfe WC. Use of Cone Beam Computed Tomography in Endodontics. *Int J Dent.* 2009;2009:634567. doi:10.1155/2009/634567.
- Gambill JM, Alder M, Rio CE. Comparison of nickel-titanium and stainless steel hand-file instrumentation using computed tomography. *J Endod.* 1996;22(7):369–75. doi:10.1016/S0099-2399(96)80221-4.
- Mounce RE, S DD, Glassman G. Choosing Taper in Canal Preparation: Applying Proven Clinical Strategies. *Oral Health.* 2010; Available from: <https://www.oralhealthgroup.com/features/choosing-taper-in-canal-preparation-applying-proven-clinical-strategies/>.
- Gulabivala K, Aung TH, Alavi A, Ng YL. Root and canal morphology of Burmese mandibular molars. *Int Endod J.* 2001;34(5):359–70. doi:10.1046/j.1365-2591.2001.00399.x.
- Al-Asadi A, Al-Hashimi R. In-vitro Assessing the Shaping Ability of Three Nickel-Titanium Rotary Single File Systems by Cone Beam Computed Tomography. *Int J Med Res Health Sci.* 2018;7(2):69–74.
- Plotino G, Grande NM, Cotti E, Testarelli L, Gambarini G. Blue treatment enhances cyclic fatigue resistance of vortex nickel-titanium rotary files. *J Endod.* 2014;40(9):1451–3. doi:10.1016/j.joen.2014.02.020.
- Shen Y, Zhou HM, Zheng YF. Current challenges and concepts of the thermomechanical treatment of nickel-titanium instruments. *J Endod.* 2013;39(2):163–72. doi:10.1016/j.joen.2012.11.005.
- Alfadley A, Alrajhi A, Alissa H, Alzgehaibi F, Hamadah L. Shaping Ability of XP Endo Shaper File in Curved Root Canal Models. *Int J Dent.* 2020;2020:4687045. doi:10.1155/2020/4687045.

## Author biography

**P. Hemalatha**, Head of the Department

**V. Sanjana**, PG Student

**Prabeesh Padmanabhan**, Professor

**M. Muthalagu**, Reader

**M. Shahul Hameed**, Lecturer

**Cite this article:** Hemalatha P, Sanjana V, Padmanabhan P, Muthalagu M, Shahul Hameed M. Comparative evaluation of canal transportation and centering ability between 4% and 6% rotary files using cone beam computed tomography — An invitro study. *IP Int J Maxillofac Imaging* 2021;7(4):156-162.