

Content available at: <https://www.ipinnovative.com/open-access-journals>

IP International Journal of Maxillofacial Imaging

Journal homepage: <https://www.ijmi.in/>

Case Report

Bilateral bifid canines in mandible: A CBCT study of a rare case

Hemant Sawhney^{1,*}, Jayant Kumar¹, Richa Mishra¹, Anka Sharma¹,
Vanshika Agarwal¹

¹Dept. of Oral Medicine, Diagnosis & Radiology, School of Dental Sciences, Sharda University, Greater Noida, Uttar Pradesh, India



ARTICLE INFO

Article history:

Received 28-02-2022

Accepted 01-03-2022

Available online 07-04-2022

Keywords:

Carestream

Impaction

Radiographs

ABSTRACT

Developmental disturbances such as change in tooth shape, size and number are recognized conditions. One such anomaly is supernumerary root. The condition is more common in molars than in anterior teeth. The studies have however shown the variation in the morphology of single rooted mandibular canine. Adding to the literature is this case report which presents impacted mandibular canine with two roots and root canals using CBCT. The awareness of these variations through varying research materials is a must. The success of treatment depends on internal and external anatomy of tooth as well. Thereby, lack of knowledge of these anatomical aberrations could lead to failure of treatment, especially endodontic treatment. Proper pre operative imaging and interpretation is a key to hike success rates with anatomical complexities and variabilities.

This is an Open Access (OA) journal, and articles are distributed under the terms of the [Creative Commons Attribution-NonCommercial-ShareAlike 4.0 License](https://creativecommons.org/licenses/by-nc-sa/4.0/), which allows others to remix, tweak, and build upon the work non-commercially, as long as appropriate credit is given and the new creations are licensed under the identical terms.

For reprints contact: reprint@ipinnovative.com

1. Introduction

The mandibular canine is a strategically important tooth in the dental arch. Canine is called the “cornerstone” of the mouth because of its location, which reflects its dual function to complement the incisors and premolars during mastication. Lower canine is a tooth with a robust, long root and very good implantation, making it a valuable abutment tooth for any type of prosthetic treatment.¹ It also plays a major role in occlusal guidance during the eccentric movements and posterior disocclusion.²

From a morphological standpoint, mandibular canine is usually a monoradicular tooth. The internal anatomy of the radicular canals does not always correlate with the outer shape of the tooth. The mandibular canines do not always display the basic anatomy that we expect with one root and one canal.³ Due to introduction of new technologies

related to intraoperative vision magnification and innovative radiological imaging systems, there has been a noticeable increment in the number of clinical studies and case reports that have revealed morphological variations, such as the presence of two roots and two root canals in the mandibular canine. Finding variations, such as this, is unpredictable and the clinician must assume that any mandibular canine could morphologize with variation, so that any unforeseen treatment complications during an endodontic treatment related to unusual root canal anatomy can be avoided.⁴

When a patient has an impacted canine, the timing of orthodontic treatment, the type of surgical procedure to expose the tooth, the orthodontic mechanics, and the potential problems vary depending on its morphology and position in the jaw.⁵ However, an impacted mandibular canine which have double roots as well as two root canals, is a very rare finding in literature and has a great impact in orthodontic treatment. Cone-beam computed tomography is a modern diagnostic modality that may be useful when

* Corresponding author.

E-mail address: hemant.sawhney@sharda.ac.in (H. Sawhney).

conventional radiographs provide limited information and further details are necessary.

This paper reports a rare incidence of bilateral mandibular canines with two roots and root canals and left canine being impacted.

2. Case Report

A healthy 53-year-old female patient was referred to the department of Oral Medicine and Radiology, School of Dental Sciences, Sharda University, India from a private clinic for cone beam tomographic evaluation of lower anterior teeth before orthodontic correction. The patient had a chief complaint of pain in the lower left anterior region. Clinical examination revealed severe attrition with endodontic attempt in left central and lateral incisors, with tenderness on percussion on both. The left canine was found to be clinically missing and patient did not give a history of extraction of the same. Electric pulp testing was performed for all the mandibular anterior teeth and delayed response was observed in both 32 and 34. CBCT was performed using Carestream CS 9300 Select 3D digital imaging system (Carestream Dental LLC, Atlanta, GA, USA). Images were obtained at 84 kVp, 10 mA with an FOV of 5x5 with 180 μ m resolution.

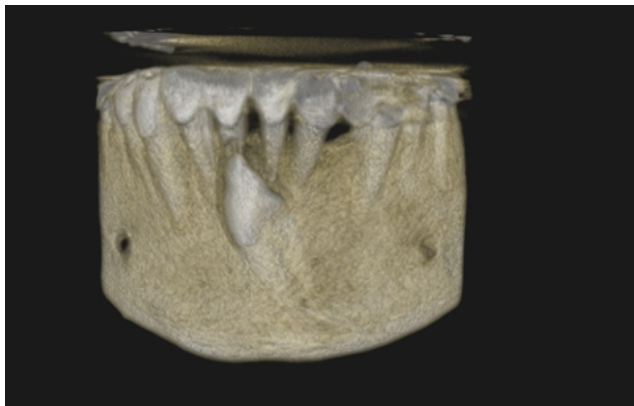


Fig. 1: CBCT 3– dimensional image showing vertically impacted mandibular canine 33

CBCT revealed vertically impacted 33 in the symphysis region of mandible involving both the alveolar and basal process (Figure 1). The impacted tooth measured approximately 23.4 mm in length and 7.3mm width at the CEJ. The crown was noted in the alveolus inferior to the apical 3rd of 42,41,31. The impacted tooth was obliquely placed and was oriented labially and causing thinning and perforation of adjoining mandibular labial cortex. The crown of the impacted tooth was in contact with the cervical and middle one third level of 41 causing external root resorption (Figure 2). The radicular portion showed furcation with evidence of lingual and buccal roots (Figure 3). The apical third region of the root did not

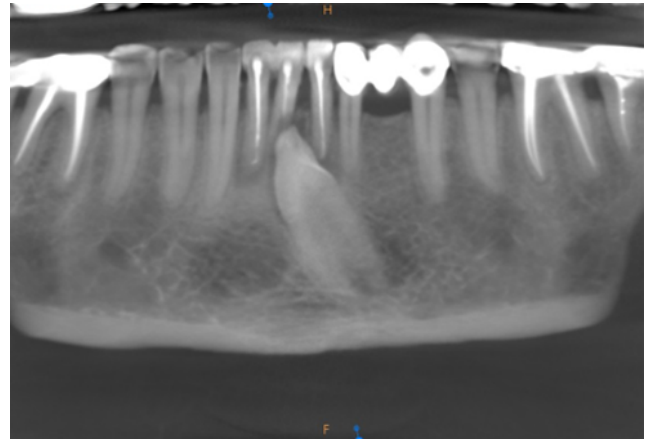


Fig. 2: The presence of crown of impacted canine between cervical and middle third of mandibular incisors and causing external root resorption.

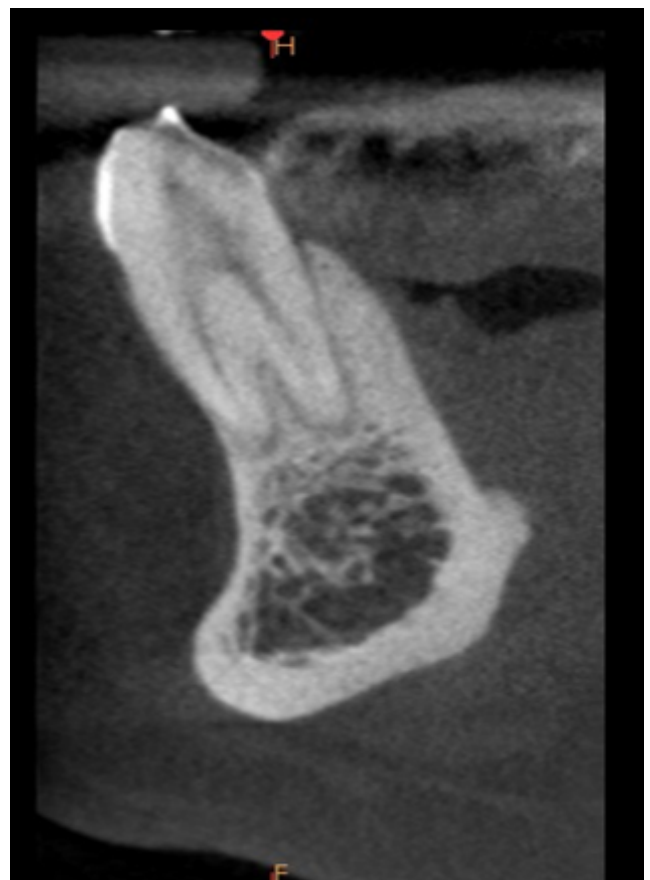


Fig. 3: The root portion showing bifurcation with clear picture of buccal and lingual roots.

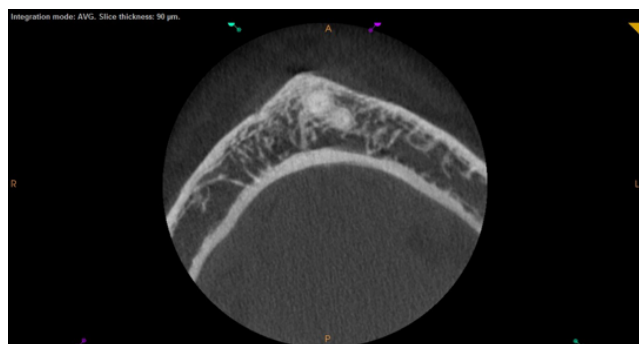


Fig. 4: CBCT imaging of peculiar two rooted mandibular canine with two canals.

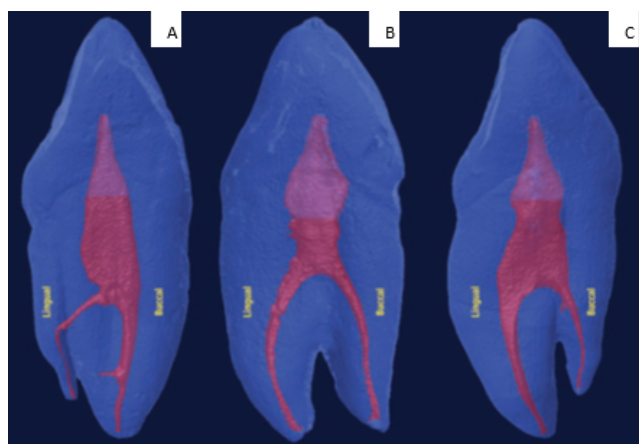


Fig. 5: (a) Two-rooted mandibular canines with a buccal root larger than lingual root, (b) Buccal and lingual roots of the same size, (c) Lingual root larger than buccal root

reveal any dilaceration. Impacted tooth revealed normal radicular and pulpal morphology with normal follicular space. Deciduous precursor was not present. The radicular portion of right mandibular canine showed furcation with evidence of lingual and buccal roots. Incomplete endodontic treatment of 32 and 34 were evident.

3. Discussion

The knowledge of any anomalous anatomical variation is of keen importance for the treatment modalities to be successful. These morphological changes within root and root canal system would be predicted in any tooth to any degree and incidence. Overlooking the fact, mandibular canine is the least studied tooth, the complex variations in the root canal system has been reported in the tooth via numerous studies. The presence of two roots in addition to two root canals is a rare occurrence in mandibular canine with a range of 1 -5%⁴(Figure 4). Pecora JD et al. (1993) studied 830 mandibular canines analysing the internal anatomy, directions and number of roots. The

results showed 1.7% of the teeth with two roots and root canals.⁶ D' Arcangelo et al. added to the literature two cases of mandibular canine with two roots underwent endodontic treatment.⁷ Another case report was added by Heling et al. of two roots in mandibular canine though the tooth exhibited three canals.⁸

Generally, the roots in bifid mandibular canine are positioned buccally and lingually which are difficult to identify in pre operative radiograph due to superimposition. Thus, the definitive diagnosis requires three-dimensional imaging modality CBCT. The bifurcation can be present either in the apical third, middle third or cervical third, implying a certain degree of difficulty in treatment. If present in the apical third, it poses a greater difficulty in localization and preparation and perforation of bifurcation becomes easy if present in the cervical region.⁴The studies have predicted the level of bifurcation in two rooted canine for 43-57% in cervical third and about 40% in the middle third.⁹ In our case report, the bifurcation was present apically.

Impacted teeth are those with delayed eruption or no eruption in correspondence to their normal timeline. The frequency of mandibular canine to be impacted is relatively a rare and unusual occurrence in against to maxillary canine. The prevalence rate of impaction varies from 0.8 -2.3% for maxillary canine to 0.05 -0.4% for mandibular canine.¹⁰ The impacted mandibular canine, as present in this case report can be classified on the basis of angulation and depth. In regards to angulation, it can be mesioangular, distoangular, vertical or horizontal. According to depth, it is classified as follows:

1. Level: The crown of the impacted canine is at the cervical margin of the adjacent tooth.
2. Level: The crown of the impacted canine is between the cervical margin and root of the adjacent teeth.
3. Level: The crown of the impacted canine is below the apex of the root of adjacent teeth.¹¹

The other classification is depicted in the Figure 5.

This case report includes vertical impaction of mandibular canine at level 2. Various treatment alternatives have been suggested for the case like extraction, auto transplantation or surgical exposure of the impacted teeth followed by moving the tooth into the dental arch orthodontically.¹²Surgical treatment has been however considered to be the more favoured option.

The associated complications of impaction or delayed eruption are pulpal necrosis, ankylosis and external root resorption.¹³Walker et al. studied root resorption about 67% in lateral incisors and 11% in central incisor adjacent to impacted teeth.¹⁴The following case report shows root resorption in mandibular anteriors in proximity to impacted mandibular canine. The diagnosis of resorbing root is made more evident with an advanced and innovative radio aid,

CBCT. A study predicted 63% improvement in detection rates of root resorption associated with impacted canine using CBCT.¹⁵ Even the extent of resorption shown in CBCT is more precise than normal radiographs.

4. Conclusion

Although mandibular canine is usually a single rooted tooth, the clinician must be aware of the existing anatomical variation of two roots and two canals. Careful interpretation of these variations using conventional radiograph techniques and advanced imaging techniques like CBCT is required. These pre operative interpretations would lead to greater precision and a successful treatment.

5. Source of Funding

None.


6. Conflict of Interest

None.

References

1. Cella AO, Mărgărit R, Gheorghiu IM. Endodontic treatment of a mandibular canine with two roots. *Rom J Morphol Embryol*. 2011;52(3):923–6.
2. Abduo J, Tennant M, Mcgeachie J. Lateral occlusion schemes in natural and minimally restored permanent dentition: a systematic review. *J Oral Rehabil*. 2013;40(10):788–802. doi:10.1111/joor.12095.
3. Arora V, Nikhil V, Gupta J. Mandibular Canine with Two Root Canals - An Unusual Case Report. *Int J Stomatological Res*. 2005;23(4):1–4.
4. Plascencia H, Cruz A, Gascón G, Ramírez B, Díaz M. Mandibular Canines with Two Roots and Two Root Canals: Case Report and Literature Review. *Case Rep Dent*. 2017;8459840:1–10. doi:10.1155/2017/8459840.
5. Peerlings RHJ. Treatment of a horizontally impacted mandibular canine in a girl with a Class II Division 1 malocclusion. *Am J Orthod Dentofac Orthop*. 2010;137(4):154–62. doi:10.1016/j.ajodo.2008.08.025.
6. Pecora JD, Sousaneto MD, Saquy PC. Internal anatomy, direction and number of root and size of human mandibular. *Braz Dent J*. 1993;4(1):53–7.
7. Arcangelo CD, Varvara G, Fazio D, P. Root canal treatment in mandibular canines with two roots: a report of two cases. *Int Endod J*. 2001;34(4):331–5. doi:10.1046/j.1365-2591.2001.00376.x.
8. Heling I, Dadon IG, Chandler N. Mandibular canine with two roots and three root canals. *Dent Traumatol*. 1995;11(6):301–3.
9. Silva D, Marinho RV, Praado D, Botelho MM, Reges TL, et al. Anatomical variations in the permanent mandibular canine: Forensic importance. *Rev Sul Bras Odontol*. 2012;9(4):468–73.
10. Aydin U, Yilmaz HH, Yildirim D. Incidence of canine impaction and transmigration in a patient population. *Dentomaxillofac Radiol*. 2004;33(3):164–73. doi:10.1259/dmfr/15470658.
11. Yavuz MS, Aras MH, Büyükkurt MC, Tozoglu S. Impacted Mandibular Canines. *J Contemp Dent Pract*. 2007;7(8):78–85.
12. Peerlings RHJ. Treatment of a horizontally impacted mandibular canine in a girl with a Class II Division 1 malocclusion. *Am J Orthod Dentofac Orthop*. 2010;137(4):154–62. doi:10.1016/j.ajodo.2008.08.025.
13. Gujar AN, Rani MS. Orthodontic management of impacted mandibular canine- A case report. *Indian J Orthod Dentofac Res*. 2016;2(3):131–5.
14. Walker L, Encisco R, Mah J. Three-dimensional localization of maxillary canines with cone-beam computed tomography. *Am J Orthod Dentofac Orthop*. 2005;128(4):418–41. doi:10.1016/j.ajodo.2004.04.033.
15. Jawad Z, Carmichael F, Houghton N, Bates C. A review of cone beam computed tomography for the diagnosis of root resorption associated with impacted canines, introducing an innovative root resorption scale. *Oral Surgery, Oral Medicine, Oral Pathology and Oral. Oral Surg Oral Med Oral Pathol Oral Radiol*. 2016;122(6):765–71. doi:10.1016/j.oooo.2016.08.015.

Author biography

Hemant Sawhney, Professor and Head  <https://orcid.org/0000-0002-0862-0760>

Jayant Kumar, Assistant Professor

Richa Mishra, Assistant Professor

Anka Sharma, Assistant Professor

Vanshika Agarwal, Intern

Cite this article: Sawhney H, Kumar J, Mishra R, Sharma A, Agarwal V. Bilateral bifid canines in mandible: A CBCT study of a rare case. *IP Int J Maxillofac Imaging* 2022;8(1):20-23.