

Content available at: <https://www.ipinnovative.com/open-access-journals>

IP International Journal of Maxillofacial Imaging

Journal homepage: <https://www.ijmi.in/>

Original Research Article

Morphology and morphometric analysis of mental foramen in south Indian population – A CBCT study

Sanjana Ravindra¹, Poornima Chandra^{1,*}, Balaji Pachipulusu¹¹Dept. of Oral Medicine and Radiology, Rajarajeswari Dental College and Hospital, Bangalore, Karnataka, India

ARTICLE INFO

Article history:

Received 10-05-2022

Accepted 09-06-2022

Available online 20-07-2022

Keywords:

Mental foramen

Cone beam computed tomography

Shape of mental foramen

Position of mental foramen

Type of mental foramen.

ABSTRACT

Background and Objectives: It is essential to define the exact location of the mental foramen to avoid potential injury to the neurovascular bundle during surgical procedures in the mandibular interforaminal region. This radiographic study was aimed to evaluate the morphology and morphometric dimensions of mental foramen (MF) among Indian population. This study also investigated the dimorphic variations of mental foramen with respect to gender and laterality.

Materials and Methods: The images of 80 subjects (160 mandibular sites) with the age range of 20 to 60 years who had undergone cone beam computed tomographic (CBCT) were retrieved from the archives and examined for morphology and morphometry of mental foramen.

Results: Oval shaped mental foramen was one and a half times greater than round shape, which was predominant in females. Position 4 was the most common location on right and left side respectively. Type I and type III were the most common radiographic appearance of mental foramen on right and left side respectively. The mean mesiodistal, superoinferior and buccolingual dimensions of MF were 2.49 ± 0.86 mm, 2.83 ± 0.73 mm and 2.44 ± 0.72 mm respectively. The mean dimensions of the mental foramen were significantly higher among the males when compared to females. The mental foramen was positioned at an average of 11.13 ± 3.40 mm from the alveolar crest (MF-C) on the right side and was positioned at 10.79 ± 3.21 mm on the left side. The distance of the mental foramen from the alveolar crest was significantly higher among the Group I when compared to Group IV.

Conclusion: The morphology of the mental foramen did not show any variations among the gender and age in the Indian population. The morphometric values of the mental foramen showed variability of 1-2 mm among different subjects of our population.

This is an Open Access (OA) journal, and articles are distributed under the terms of the [Creative Commons Attribution-NonCommercial-ShareAlike 4.0 License](https://creativecommons.org/licenses/by-nc-sa/4.0/), which allows others to remix, tweak, and build upon the work non-commercially, as long as appropriate credit is given and the new creations are licensed under the identical terms.

For reprints contact: reprint@ipinnovative.com

1. Introduction

The mental foramen is a funnel-like opening located on the surface of the anterolateral aspect of the mandible. It marks the termination of the mandibular canal in the mandible, through which the inferior alveolar nerve and vessels pass. It forms an important anatomical landmark in the mandible.¹ A complete understanding of this structure is essential, as it emerges as a neurovascular bundle, and any direct

or indirect damage during surgical procedure would lead to complications.² It is known that there are no absolute anatomical landmarks for reference, and the foramen cannot be clinically visualized or palpated. The mental foramen differs in size, shape and location which may be related to race, age and gender.³ Several imaging modalities have been used to evaluate the morphology and morphometry of mental foramen and anterior loop of mental nerve.

Computed Tomography (CT) and Cone beam computed tomography (CBCT) have brought about paradigm shift in diagnostic imaging and have helped overcome the

* Corresponding author.

E-mail address: drpoornichandra@yahoo.com (P. Chandra).

limitations of two-dimensional imaging. Cone Beam Computed Tomography is a volumetric imaging modality which is ideal for capturing anatomic structures with less radiation exposure (0.04 – 0.17 mSv), is cost effective and has short acquisition time. All these considerations make CBCT a very promising imaging modality in maxillofacial diagnosis.⁴

With the above background, the present study is designed to determine the morphology and morphometric dimensions of mental foramen using CBCT.

2. Materials and Methods

The images of 80 subjects with the age range of 20 to 60 years who had undergone cone beam computed tomographic (CBCT) examination of the mandible were retrieved from the archival records of the Department of Oral Medicine and Radiology using random sampling method. All the subjects were equally divided into four age groups with intervals of 10 years each and with equal distribution of males and females in each of these groups. The CBCT images of the mandibular premolar and molar regions of both the sides were included in the study. The images with pathologies and fractures, errors and artifacts obscuring visibility of the structures in the mandibular premolar-molar region were excluded from the study.

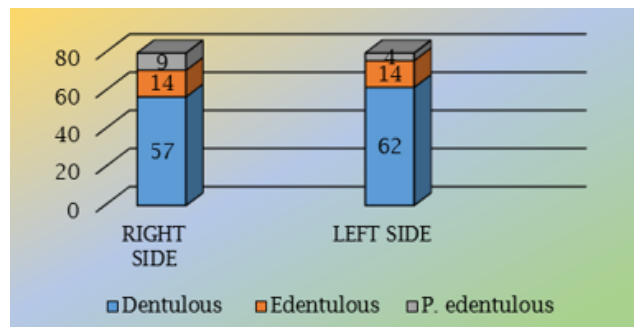
The images were obtained using CBCT machine (Soredex, Sweden) and measurements were made using OnDemand software. The three standard sections, that is, axial, coronal and sagittal sections were used for making the measurements.

One hundred and sixty mandibular sites were examined for morphology and morphometric analysis of mental foramen. The shape, position and type of mental foramen was determined. The shape of the mental foramen was classified either as oval or round shape as described by Lacerda et al.⁵ and was correlated with age and gender. The position of the mental foramen was assessed as given by Ngeow et al.⁶ The radiographic appearance of the mental foramen was analysed as classified by Yosue et al.⁷ The sample was subjected to intra and inter examiner variability.

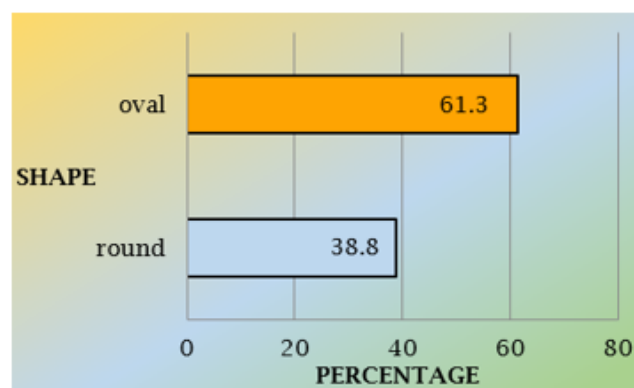
3. Results

Descriptive and inferential statistical analysis were carried out in this study. Results on categorical variables (such as age, gender, dentition status, shape, position and type of mental foramen) are presented as numbers and percentages. Results on continuous measurements (mesiodistal, buccolingual and superoinferior dimension, distance from the crest and length of anterior loop) are presented as mean and standard deviation. The level of significance (p-value) was set at $p < 0.05$. Right and left sides of the mandible of 80 subjects (40 males, 40 females) i.e., a total of 160 mandibular sites were examined for

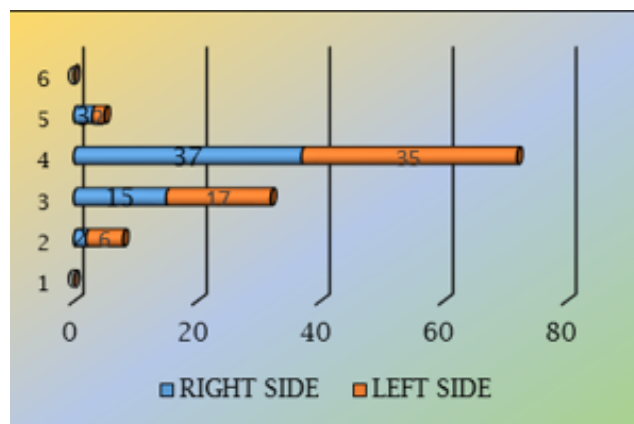
assessing the morphology and morphometry of mental foramen. Based on the age, the study group was divided into 4 subgroups as follows:



Graph 1: Dentition status on right and left side of the arch.



Graph 2: Shape of the mental foramen



Graph 3: Position of the mental foramen on right and left side of the arch

Table 1: Age distribution of the study group

Age (in years)	Groups	Frequency	Percent
21-30	I	20	25
31-40	II	20	25
41-50	III	20	25
51-60	IV	20	25
Total		80	100.0
Mean ±SD	39.2±12.2		

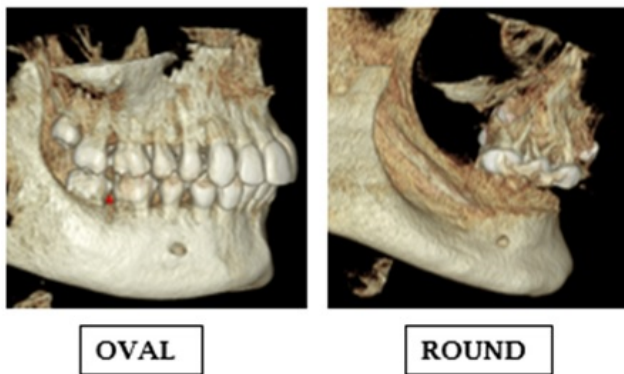


Fig. 1: Shape of the mental foramen as seen in our study group

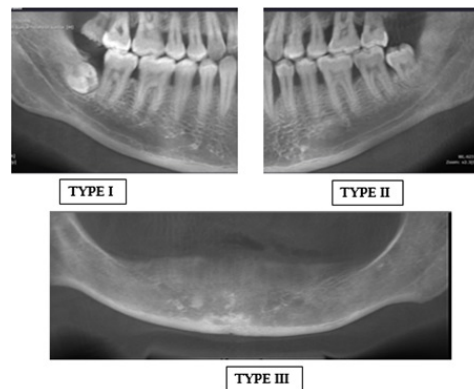


Fig. 3: Radio graphic type of mental foramen

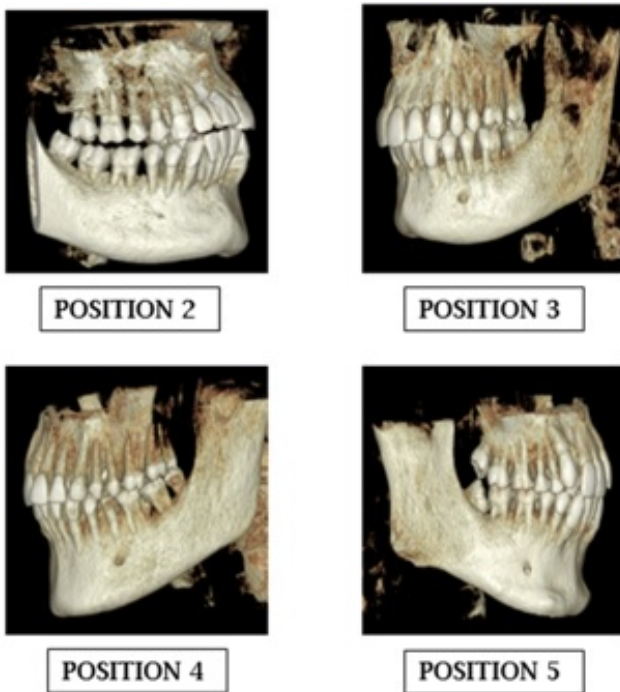


Fig. 2: Position of the mental foramen as seen in our study group

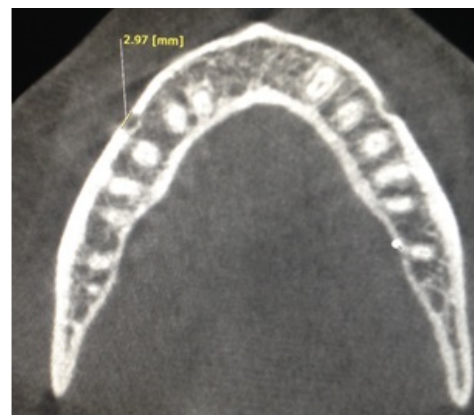

Fig. 4: Mesiodistal dimension of the mental foramen (CBCT-axial section)

Table 2: Cross tabulation of age and shape and gender and shape of the mental foramen

Group	Shape of The Mental Foramen			
	Right Round	Oval	Chi square	p
I	10 50.0%	10 50.0%		
II	4 20.0%	16 80.0%		
III	9 45.0%	11 55.0%	4.371	0.2
IV	8 40.0%	12 60.0%		
Gender	Shape of The Mental Foramen			
	Right Round	Left Round	Chi square	P
Male	21 52.5%	18 45.0%	6.373	0.01*
Female	10 25.0%	13 32.5%		
		Oval	Chi square	P
		22 55.0%	1.317	0.2
		27 67.5%		

Table 3: Cross tabulation of age and position and gender and position of mental foramen

Group	Position of Mental Foramen						Chi square	p	Chi square	p									
	Right Side	1	2	3	4	5					6	Left side	3	4	5	6			
1	0	0	5	13	1	0	0	0.0%	0	1	13	1	0	0.0%	0.0%	0.0%	0.0%	12.67	0.3
11	0	0	2	13	2	0	0	0.0%	0	0	13	1	0	0.0%	20.96%	1.61%	0.0%	12.67	0.3
111	0	2	5	8	0	0	0	0.0%	0	2	10	0	0	0.0%	20.96%	1.61%	0.0%	12.67	0.3
1V	0	0	3	3	0	0	0	0.0%	0	2	4	0	0	0.0%	16.12%	0.0%	0.0%	12.67	0.3
Gender	Position of Mental Foramen	Right Side	1	2	3	4	5	6	Chi square	p	Left Side	3	4	5	6	Chi square	p		
Male	0	0	8	17	2	0	0	0.0%	14.57	0.2	0	0	2	4	5	6	0	0	0
Female	0	2	7	20	1	0	0	0.0%	14.57	0.2	2	8	19	0	0	0	0	0	0
	0.0%	3.5%	12.2%	35.0%	1.7%	0.0%	0.0%	0.0%	14.57	0.2	3.2%	12.9%	30.64%	0.0%	0.0%	0.0%	0.0%	12.67	0.3

Table 4: Cross tabulation of age and type and gender and type of mental foramen

Group	Right Side					Chi square	p	Type of mental for a men Left Side					Chi square	p	
	1	2	3	4				1	2	3	4				
I	7 35 %	9 45 %	4 20 %	0 0 %				7 35 %	7 35 %	6 30 %	0 0 %				
II	5 25 %	1 5 %	14 70 %	0 0 %		24.21	0.0*	4 20 %	2 10 %	14 70 %	0 0 %		11.89	0.06	
III	10 50 %	3 15 %	7 35 %	0 0 %				5 25 %	7 35 %	8 40 %	0 0 %				
IV	8 40 %	10 50 %	2 10 %	0 0 %				5 25 %	10 50 %	5 25 %	0 0 %				
Gender															
Right Side															
Male	13 32.5 %	9 22.5 %	18 45.0 %	0 0.0 %		4.620	0.09	9 22.5 %	12 30.0 %	3 7.5 %	0 0.0 %			1.340	0.5
Female	17 42.5 %	14 35.0 %	9 22.5 %	0 0.0 %				12 30.0 %	14 35.0 %	14 35.0 %	0 0.0 %				

Table 5: Morphometric parameters of mental foramen

Dimension	Right	Left
	MEAN ± SD	MEAN ± SD
M-D	2.93 ± 0.86	2.85 ± 0.86
B-L	2.52 ± 0.69	2.35 ± 0.74
S-I	2.71 ± 0.67	2.95 ± 0.79
MF-C	11.13 ± 3.40	10.79 ± 3.21

Table 6: Cross tabulation of age and morphometric parameters of mental foramen

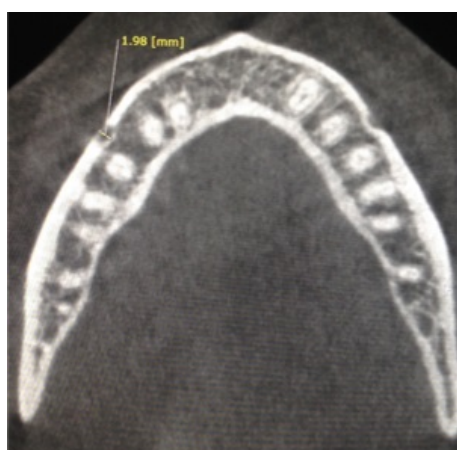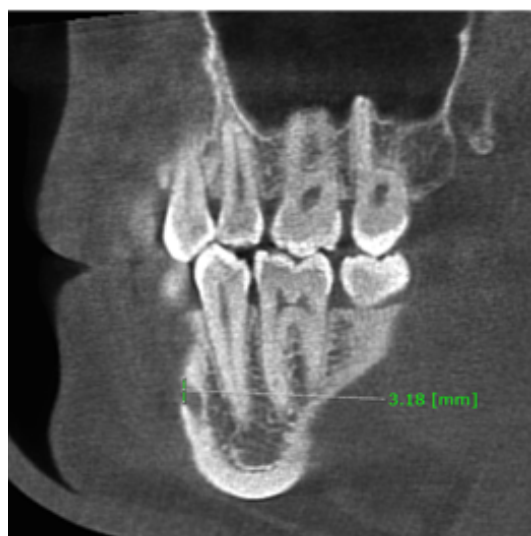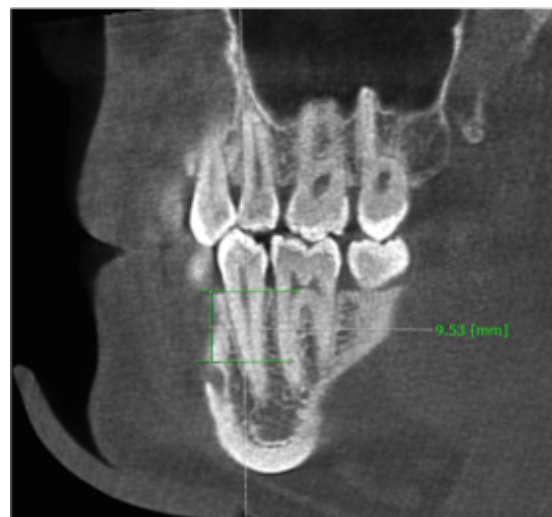Dimension	Group	Right side			Left side		
		Mean ± SD	F	P	Mean ± SD	F	p
M-D	I	3.41 ± 1.05	2.075	0.03	3.14 ± 1.08	1.5	0.1
	II	2.75 ± 0.56			2.69 ± 0.63		
	III	2.76 ± 0.84			2.96 ± 0.90		
	IV	2.80 ± 0.82			2.61 ± 0.72		
B-L	I	2.70 ± 0.82	1.54	0.2	2.68 ± 0.94	0.80	0.4
	II	2.63 ± 0.62			2.19 ± 0.70		
	III	2.26 ± 0.58			2.23 ± 0.60		
	IV	2.51 ± 0.69			2.30 ± 0.60		
S-I	I	2.73 ± 0.68	1.22	0.3	3.11 ± 0.77	0.42	0.7
	II	2.89 ± 0.53			2.94 ± 0.63		
	III	2.49 ± 0.58			2.85 ± 0.77		
	IV	2.73 ± 0.83			2.88 ± 0.99		
MF-C	I	12.19 ± 3.58	1.97	0.12	12.14 ± 2.93	3.19	0.02*
	II	11.61 ± 2.69			10.69 ± 3.21		
	III	10.29 ± 3.49			10.94 ± 3.14		
	IV	10.25 ± 3.52			9.39 ± 3.19		

Table 7: Cross tabulation of dentition status and morphometric parameters of mental foramen

Dimension	Dentition status	Right side			Left side		
		Mean ± SD	F	p	Mean ± SD	F	p
M-D	Dentulous	3.04 ± 0.91	2.2	0.1	2.94 ±	2.25	0.11
	Partially edentulous	2.64 ± 0.54			2.73 ±		
	Completely edentulous	2.76 ± 0.79			2.49 ±		
B-L	Dentulous	2.58 ± 0.75	0.5	0.5	2.32 ± 0.74	90	0.40
	Partially edentulous	2.38 ± 0.58			2.34 ± 0.72		
	Completely edentulous	2.41 ± 0.42			2.83 ± 0.83		
S-I	Dentulous	2.80 ± 0.67	2.8	0.1	2.92 ± 0.78	.38	0.68
	Partially edentulous	2.40 ± 3.19			3.11 ± 0.94		
	Completely edentulous	2.64 ± 3.03			2.79 ± 0.53		
MF-C	Dentulous	11.79 ± 3.19	4.5	0.01*	11.52 ± 3.04	8.60	0.00*
	Partially edentulous	8.94 ± 3.63			8.54 ± 2.53		
	Completely edentulous	10.39 ± 3.03			7.42 ± 2.57		

Table 8: Cross tabulation of gender and morphometric parameters of mental foramen

Dimension	Gender	Right Side			Left Side		
		Mean ± SD	t	p	Mean ± SD	t	p
M-D	Male	3.15 ± 0.80	2.2	0.025*	2.93 ± 0.75	0.8	0.4
	Female	2.72 ± 0.88			2.77 ± 0.96		
B-L	Male	2.71 ± 0.59	2.4	0.001*	2.57 ± 0.63	2.7	0.007*
	Female	2.34 ± 0.74			2.13 ± 0.78		
S-I	Male	2.84 ± 0.66	1.8	0.07	3.22 ± 0.88	3.2	0.002*
	Female	2.57 ± 0.66			2.67 ± 0.59		
MF-C	Male	11.57 ± 3.20	1.1	0.2	11.01 ± 3.41	0.6	0.5
	Female	10.7 ± 3.57			10.57 ± 3.03		

**Fig. 5:** Bucco-lingual dimension of the mental foramen (Axial section - CBCT)**Fig. 6:** Supero-inferior dimensions of the mental foramen (CBCT-Sagittal section)**Fig. 7:** Distance between superior margin of the mental foramen and the alveolar crest (CBCT –Sagittal section)

1. Group I – 21 to 30 years
2. Group II – 31 to 40 years
3. Group III – 41 to 50 years
4. Group IV – 51 to 60 years (Table 1)

Each of these groups has 20 subjects and equal number of males and females i.e., 10 males and 10 females in each group. Among the 160 mandibular sites, 119 were dentulous, 13 were partially edentulous in the region of premolars and 14 were completely edentulous (Graph 1).

4. Morphology of The Mental Foramen

4.1. Shape

The shape of the mental foramen was analysed using 3D reconstruction of the CBCT images (Figure 1). The mental foramen was mostly oval shaped (61.3%) both on the right and left side of the mandible (Graph 2) (Figure 1). There was no correlation between age and the shape of the mental foramen (Table 2). Males had both oval and round shaped mental foramen while females had significantly higher number of oval shaped mental foramen (Table 2).

4.2. Position

The position of the mental foramen was analysed using 3D reconstruction of the CBCT images (Figure 2). The position of mental foramen was classified into 6 positions according to Ngeow et al.⁶ Position 4 was the most common location of the mental foramen both on the right and left sides (59.64% and 58.06% respectively) (Graph 3) (Figure 2). The position in relation to age and gender did not show any correlation (Table 3).

4.3. Type

The radiographic type of mental foramen was assessed using panoramic reconstruction of CBCT images (Figure 3). The radiographic appearance of mental foramen was divided into 3 types as proposed by Yosue et al.⁷ On the right side, Type I was the most commonly found, while type III was the most common type on the left side. Correlating the age and type of mental foramen, type II was significantly higher in on both sides of the jaw (Table 4). There was no statistically significant correlation between gender and type of mental foramen (Table 4).

5. Morphometric Analysis of Mental Foramen

5.1. Mean dimension of mental foramen

The mesio-distal and bucco-lingual dimensions of the mental foramen was measured on axial sections (Figures 4 and 5) and the supero-inferior dimension was measured using sagittal sections (Figure 6). Table 5 shows the mesio-distal, bucco-lingual and supero-inferior dimensions of the mental foramen on both right and left sides. There was no significant difference in the M-D, B-L and S-I dimensions among various age groups and was not correlated to the status of the dentition in the arch (Tables 6 and 7). The mean dimensions [mesiodistal (M-D), buccolingual (B-L) and supero-inferior (S-I)], of the mental foramen were significantly higher among the males when compared to females (Table 8).

5.2. Distance between mental foramen and alveolar crest

The distance between the superior margin of the mental foramen and the alveolar crest was measured using sagittal sections (Figure 7). The mental foramen was positioned at an average of 11.13 ± 3.40 mm from the alveolar crest (MF-C) on the right side and was positioned at 10.79 ± 3.21 mm on the left side (Table 5). There was a significant difference in the mean distance of mental foramen from the crest on the right side among various age groups, the distance was highest among Group I (12.3 ± 3.58 mm) followed by group II (11.61 ± 2.69 mm), Group III (10.29 ± 3.49 mm), and Group IV (10.25 ± 3.52 mm) respectively. Similarly, there was a significant difference in the mean

distance of mental foramen from the crest on the left side among various age groups, the distance was highest among Group I (12.1 ± 2.93 mm) followed by Group III (10.6 ± 3.2 mm), Group II (10.6 ± 3.21 mm), and Group IV (9.39 ± 3.19 mm) respectively. The mean distance was higher in males compared to that in females, but however it was statistically insignificant. On the left side of the arch, the distance between the mental foramen and alveolar crest was significantly higher among Group I when compared to Group IV (Table 6). The distance of the mental foramen from the crest was not significantly different among males and females (Table 8). In edentulous subjects, the mental foramen was significantly closer to the alveolar crest than dentulous and partially edentulous subjects (Table 7).

There was no significant difference in the intra-examiner and inter-examiner mean values of parameters and there is a good correlation between intra- and inter-examiner values.

6. Discussion

Treatment planning for mandibular surgical procedures is often complicated by the unknown location and extent of anatomical structures. One such anatomical structure is mental foramen and its anterior loop. It is essential to define the exact location of the mental foramen and to consider the possibility of anterior loop of mental nerve located mesial to the mental foramen to avoid potential injury to the neurovascular bundle during surgical procedures in the mandibular interforaminal region.

Procedures such as placement of dental implants, osteotomy, bone harvesting, although considered to be safe elective procedures, sensory disturbances have been reported as a complication in upto 31% of patients in the first two weeks following surgery, with 10-15% of patients continuing to complain of sensory disturbances even up to 15 months after procedure.⁸

This radiographic study was aimed to evaluate the morphology and morphometric dimensions of mental foramen and the anterior loop with an objective to assess their variations among Indian population. This study also assessed the dimorphic variations of mental foramen and its anterior loop with respect to gender and laterality using cone beam computed tomography.

In present study, the shape, position and type of mental foramen were assessed according to the criteria suggested by Lacerda R et al,⁵ Ngeow et al,⁶ Yosue T et al.⁷ respectively.

In this study, the most frequent position of MF was position 4 (64.70%) followed by position 3 (26.89%) and position 1 and position 6 was not seen in any of the images. There was no statistically significant difference between gender ($p=0.2$) and age ($p = 0.2$) (Tables 4 and 5). Our results are in concordance with studies done by Parnia F et al,⁹ Sheiki M et al,¹⁰ Juan CP et al,¹¹ Genu PR et al,¹² Ebrahimi M et al,¹³ Saito K et al,¹⁴ Panjnoush M et al.¹⁵

and Chandra et al.¹⁶ However, studies done by von Arx T et al,¹⁶ Gungor E et al.¹⁷ showed that position 3 was most common.

In our study, the most frequent radiographic appearance of mental foramen was diffuse type (37.5%) and in none of the cases it was unidentified type. There was no significant difference in terms of age and gender (Tables 6 and 7).

The present study measured the horizontal and vertical diameter of the mental foramen. The horizontal dimension of the mental foramen was measured using the mesiodistal and buccolingual dimension of mental foramen whereas the vertical diameter was measured by taking superoinferior dimension.

The mean mesiodistal dimension of MF in our study were 2.93 ± 0.86 mm and 2.85 ± 0.86 mm on right and left side respectively (Table 8). There was no statistical difference with respect to age ($p = 0.03$). However, on the right side of the arch it was noted that the mean mesiodistal dimension was greater in males as compared to females ($p = 0.025$) whereas on the left side, there was no significant difference in terms of gender. These dimensions were similar to the studies done by von Arx T et al,¹⁶ but studies done by Kalender et al,¹⁸ Gungor et al.¹⁷ and Çağlayan et al.¹⁹ showed higher horizontal diameter than that seen our study. In the present study, the mean buccolingual dimensions were 2.53 ± 0.69 and 2.35 ± 0.74 mm on right and left side respectively (Table 8). There was no significant difference in the buccolingual dimension and age of the patient. There was statistically significant difference seen in buccolingual dimension among different genders. It was noted that males had slightly higher dimension as compared to females on both right side ($p = 0.001$) and left side ($p = 0.007$).

The mean superoinferior dimensions of MF were 2.71 ± 0.67 mm and 2.95 ± 0.79 mm on right and left side respectively (Table 8). There was no statistical difference with regards to age ($p = 0.3$). These dimensions were similar to the studies done by von Arx et al,¹⁶ but studies done by Kalender et al,¹⁸ Gungor et al.¹⁷ showed higher vertical diameter than our study.

Results obtained from our study showed that size of mental foramen on left side was slightly larger than the right side which is analogous to the study done by Phillips et al.² On the other hand, Yosue T et al.⁷ reported that there is no significant difference in the diameter of mental foramen with respect to laterality.

In our study, the mean distance from mental foramen and alveolar crest were 11.13 ± 3.40 mm and 10.79 ± 3.21 mm on right and left side respectively (Table 8). It was noted that MF-C was highest among the group I and lowest among group IV, and there was statistically significant difference on left side of the arch ($p = 0.02$). The mean distance was higher among males than females but was not statistically significant. This was in accordance to the studies done by von Arx T et al.¹⁶ In our study, the distance between MF-

C was less in older age groups which was similar to the previous studies done by Gungor et al,¹⁷ von Arx T et al,¹⁶ This may be attributed to the loss of teeth which in turn leads to resorption of alveolar bone hence, mental foramen is located closer to the alveolar crest as age progresses.

The dimensions of the mental foramen found in our study has positive correlation with those of some studies but has differences from some other studies. Hence, the dimensions of the mental foramen are specific to ethnicity and gender.

To the best of our knowledge, this seems to be one of the few studies to examine the radiographic type of mental foramen using cone beam computed tomography, which also measured the other horizontal dimension of mental foramen i.e. the buccolingual dimension. Hence, these findings could be used in future studies with larger samples to make more accurate analysis.

The data was subjected to intra and inter examiner variability. Statistical analysis showed there was no significant difference in the intra as well as inter examiner observations. Therefore, it can be inferred that there is good intra and inter examiner reliability suggesting that measurements made on CBCT images are accurate and reproducible.

7. Conclusion

To conclude, the morphology of the mental foramen showed variations among the gender and age in Indian population. The morphometric values of the mental foramen showed variability of 1-2 mm among different subjects of our population. Hence, treatment planning that involves the interforaminal region of the mandible should be carried out on a case-by-case basis to determine appropriate location and dimension of mental foramen. A good intra and inter examiner reliability was observed in our study, suggesting that measurements made on CBCT images are accurate and reproducible.

8. Source of Funding

None.

9. Conflict of Interest

None.

References

1. Raju G, Sairam V, Geethamalika, Vikas S. Evaluation of mental foramen - A CBCT assessment. *IP Int J Maxillofac Imaging*. 2018;4(1):23–6.
2. Phillips JL, Weller N, Kulild JC. The mental foramen: Part 1. Size, orientation, and positional relationship to the mandibular second premolar. *J Endod*. 1990;16(5):221–3.
3. Juodzbalys G, Wang HL, Sabalys G. Anatomy of mandibular vital structures. Part 2: Mandibular incisive canal, mental foramen and associated neurovascular bundles in relation with dental implantology. *J Oral Maxillofac Res*. 2010;1(1):3.

4. Eskenazi AV, VJames JM, Graces MAS, Escoda CG. A retrospective radiographic evaluation of the anterior loop of the mental nerve: comparison between panoramic radiography and cone beam computerized tomography. *Med Oral Patol Oral Cir Bucal*. 2015;20(2):239-45.
5. Lacerda R, Oliveira PC, De Andrade CA, Souza CC, Braitt GR, De Souza FS. Tomographic evaluation of the position and form of the mental foramen in a Brazilian subpopulation. *J Dent Med Sci*. 2016;15(12):105-10.
6. Ngeow WC, Yuzawati Y. The location of mental foramen in a selected Malay population. *J Oral Sci*. 2003;45(3):171-5.
7. Yosue T, Brooks S. The appearance of mental foramina on panoramic radiographs. I. Evaluation of patients. *Oral Surg Oral Med Oral Pathol*. 1989;68(3):360-4.
8. Rosa MB, Maior BSS, Machado VDC, Francischone CE. Retrospective study of the anterior loop of the inferior alveolar nerve and the incisive canal using cone beam computed tomography. *Int J Oral Maxillofac Implant*. 2013;28(2):388-92.
9. Parnia R, Moslehefard E, Hafezeqoran A, Mahboub F, Kahnamoui HM. Characteristics of anatomical landmarks in the mandibular interforaminal region: A CBCT study. *Med Oral Patol Oral Cir Bucal*. 2012;17(3):420-5.
10. Sheiki M, Kheir K, Hekmatian M. Cone beam computed tomography evaluation of mental foramen variations: a preliminary study. *Int J Dent*. 1989;2015(1):1-4.
11. Juan CP, Eduardo QC. Morphological and morphometric study of the mental foramen using cone beam CT in dentate adult patients. *Odontostomatologia*. 2014;16(24):1-9.
12. Genu PR, De Holanda RJ, De Oliveira PB, De Vasconcelos B, Cruz NCD. Analysis of anatomical landmarks of the mandibular interforaminal region using CBCT in a Brazilian population. *Braz J Oral Sci*. 2014;13(4):303-7.
13. Ebrahimi M, Pripatnanont P, Omami G, Tharanon W. Cone beam computed tomography analysis of mental and genial spinal foramina in a Thai population. *Int J Dent Oral Sci*. 2015;2(4):65-71.
14. Saito K, De Araujo NS, Saito MT, De Carvalho PL. Analysis of the mental foramen using cone beam computerized tomography. *Rev Odontol*. 2015;44(4):226-31.
15. Panjnoush M, Rabiee ZS, Kheirandish Y. Assessment of location and anatomical characteristics of mental foramen and mandibular incisive canal using cone beam computed tomography. *J Dent*. 2016;13(2):126-32.
16. Chandra P, Govindraj P, Chowdhary R. Radiographic evaluation of anatomical variables in maxilla and mandible in relation to dental implant placement. *Indian J Dent Res*. 2016;27(4):344-51.
17. Arx V, Friedli T, Sendi M, Losanoff P, Bornstein S. Location and dimensions of the mental foramen: A radiographic analysis by using cone beam computed tomography. *J Endod*. 2013;39(12):1522-8.
18. Gungor E, Aglarci OS, Unal M, Dogan MS, Guven S. Evaluation of mental foramen location in the 10-70 years age range using cone beam computed tomography. *Niger J Clin Pract*. 2017;20(1):88-92.
19. Kalender A, Orhan K, Aksoy U. Evaluation of the mental foramen and accessory mental foramen in Turkish patients using cone beam computed tomography images reconstructed from a volumetric rendering program. *Clin Anat*. 2012;25(5):584-92.

Author biography

Sanjana Ravindra, P G Student

Poornima Chandra, Professor

Balaji Pachipulusu, Professor and Head

Cite this article: Ravindra S, Chandra P, Pachipulusu B. Morphology and morphometric analysis of mental foramen in south Indian population – A CBCT study. *IP Int J Maxillofac Imaging* 2022;8(2):45-55.