

Content available at: <https://www.ipinnovative.com/open-access-journals>

IP International Journal of Maxillofacial Imaging

Journal homepage: <https://www.ijmi.in/>

## Case Report

# A giant peripheral ossifying fibroma-A case report

Manisha Tanaji Sherkhane<sup>1,\*</sup>, Antu Kizhakethodikayil<sup>1</sup>, Bindu Pekkodath<sup>1</sup>,  
Divya Kallanchira Devraj<sup>1</sup>, Lidiya Thomas<sup>1</sup>, Nileena R Kumar<sup>1</sup>

<sup>1</sup>Dept. of Oral Medicine and Radiology, Government Dental College, Kozhikode, Kerala, India



### ARTICLE INFO

#### Article history:

Received 16-12-2022

Accepted 16-02-2023

Available online 18-04-2023

#### Keywords:

POF

Contrast Enhanced Computed

Tomography (CECT)

Calcification

### ABSTRACT

Peripheral ossifying fibroma (POF) is a reactive lesion of the gingiva which predominantly affects women and is usually found anterior to the maxillary molars. POF is usually a fibroma of the gingiva which shows some areas of calcification or ossification. According to literature, POF is a separate clinical entity rather than a transitional form of pyogenic granuloma or irritation fibroma. Surgical excision is the treatment of choice for POF, though the recurrence has been reported in many cases. We present a case of large POF arising from alveolar mucosa in left maxillary edentulous region in 57 years old female patient.

This is an Open Access (OA) journal, and articles are distributed under the terms of the [Creative Commons Attribution-NonCommercial-ShareAlike 4.0 License](https://creativecommons.org/licenses/by-nc-sa/4.0/), which allows others to remix, tweak, and build upon the work non-commercially, as long as appropriate credit is given and the new creations are licensed under the identical terms.

For reprints contact: [reprint@ipinnovative.com](mailto:reprint@ipinnovative.com)

## 1. Introduction

POF is a reactive lesion of the gingival tissues which predominantly affects women and is usually seen anterior to the molars in the maxilla. Synonyms of POF are peripheral cementifying fibroma, peripheral fibroma with osteogenesis, calcifying or ossifying fibroid epulis, peripheral fibroma with calcification, calcified or ossified fibrous epulis and calcified fibroblastic granuloma. POF can arise as a result of irritations such as trauma, micro-organisms, plaque, calculus, faulty restorative materials and dental appliances.<sup>1</sup> POF accounts for 3.1% of all oral tumors and 9.6% of gingival lesions.<sup>2</sup> POF is typically seen as a growth of interdental papilla. It is commonly seen in second decade with gradual decrease in incidence as age increases. POF shows clinically benign behaviour, usually smaller than 2 cm in diameter. The base of POF lesion may be sessile or pedunculated, the colour is identical to that of the gingiva or slightly reddish and the surface may appear ulcerated. Diagnosis is based on clinical

presentation and biopsy. Incidences of recurrence have been reported 16–20%.<sup>3</sup> Reasons for recurrence include incomplete excision of the lesion, failure to eliminate local causes, and difficulty in access during surgery due to complex location. Deep excisions have been preferred for recurrent cases of POF.<sup>3</sup>

## 2. Case Report

57 years old female patient reported to our institute with chief complaint of large mass in mouth for ten years. Slow and gradual increase in size of the growth noticed by the patient over the period of ten years. Patient was asymptomatic with absence of any functional impairment like eating or talking. So, patient did not seek any treatment. Patient was concerned only about esthetics, so reported to our institute for treatment. There was no relevant medical or dental history or any deleterious habits.

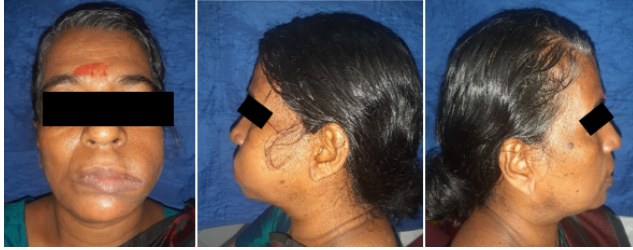Facial asymmetry was noted on extraoral examination due to diffuse swelling on left side of face which was extending supero-inferiorly from ala-tragus line to 2 cm superior to the inferior border of the mandible and antero-posteriorly from ala of nose to 2 cm anterior to the tragus

\* Corresponding author.

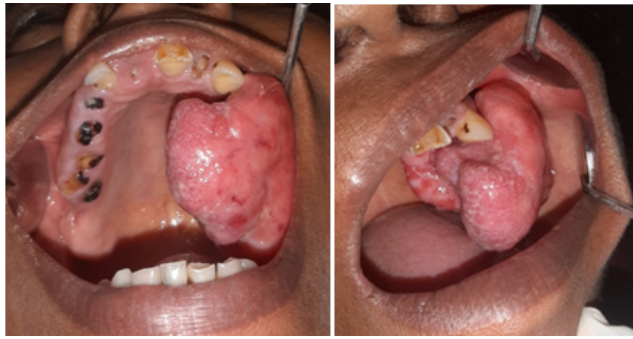E-mail address: [manishasherkhane321@gmail.com](mailto:manishasherkhane321@gmail.com) (M. T. Sherkhane).

of ear. Swelling was nontender and firm in consistency on palpation. Bilateral level I B lymph nodes were palpable and nontender.

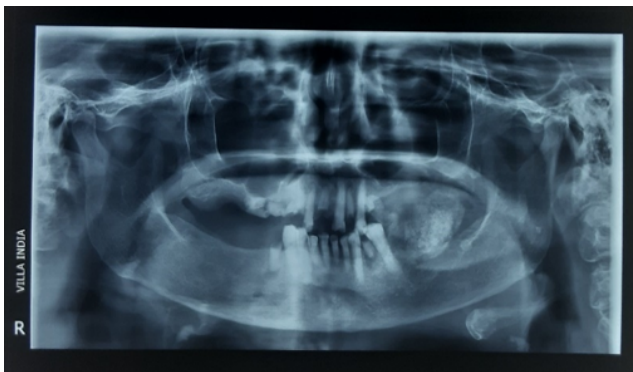On intraoral examination, oral hygiene was satisfactory. Single well-defined, pedunculated growth was noted arising from edentulous left posterior maxillary alveolar ridge, of size approximately 5 X 6 cm<sup>2</sup>. Growth was extending antero-posteriorly from 23 to 28 region and supero-inferiorly from left maxillary mucobuccal sulcus to the lower edentulous ridge. Medially growth was extending to the mid-palatal region and laterally to the buccal vestibule.



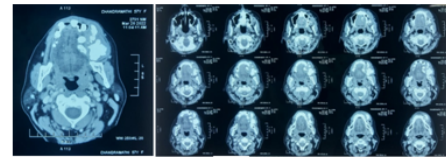
**Fig. 1:** Extraoral photographs showing facial asymmetry



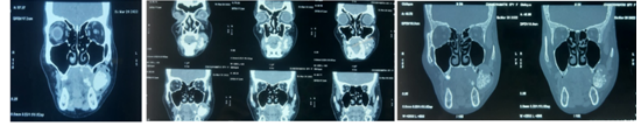
**Fig. 2:** Intraoral photographs showing large growth arising from left maxillary alveolus



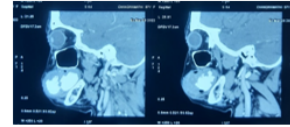
**Fig. 3:** Panoramic radiograph showing mixed radiopaque radiolucent lesion with varying density on left side between maxillary and mandibular edentulous alveolar ridge.



(a)

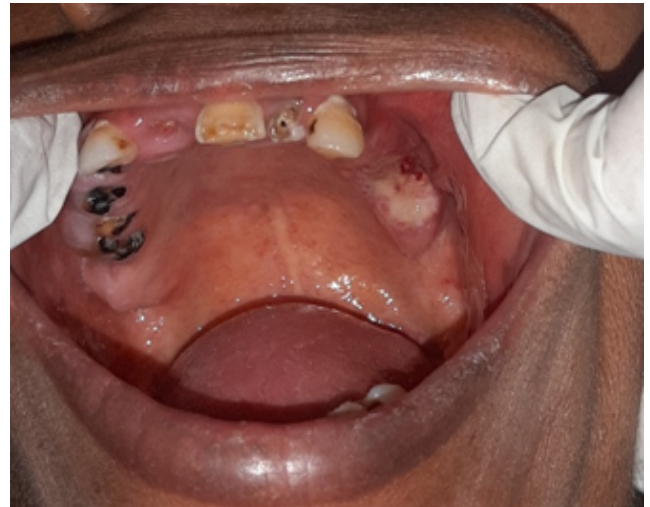

(b)



(c)

**Fig. 4:** CECT scan shows a) Axial section, b) Coronal section, c) Sagittal section showing expansile lesion epicentered in alveolar process of maxilla on left side with minimally enhancing soft tissue areas and areas of calcification.



**Fig. 5:** Post-surgical intraoral photograph showing healing surgical site in left maxillary edentulous ridge.

Overlying mucosa was smooth and erythematous with ulceration on anterior aspect due to trauma from 23. No visible discharge. On palpation, growth was nontender, firm in consistency, non fluctuant, nonreducible, and noncompressible. On hard tissue examination, multiple root stumps were noted. Based on clinical examination, diagnosis of benign connective tissue neoplasia was made.

Panoramic radiograph showed mixed radiopaque radiolucent lesion with varying density in left maxilla which was extending from alveolus distal to 24 to left maxillary tuberosity with coalesced radiopaque mass within it. Root

stumps were seen in relation to 11,13,14,16,22,24,34,45. Diagnosis was made as peripheral ossifying fibroma of left maxillary alveolus.

CECT scan of maxilla was advised for further radiographic evaluation which showed expansile lesion epicentered in alveolar process of maxilla on left side with minimally enhancing soft tissue areas and some areas of calcification-likely ossifying fibroma.

Excisional biopsy was advised. Histopathology reported as peripheral ossifying fibroma of left maxilla. Patient followed up for two months. Patient's esthetics and functions were improved.

### 3. Discussion

Menzel first described the lesion ossifying fibroma in 1872, but terminology was given by Montgomery in 1927.<sup>4</sup> Ossifying fibroma occurs more in craniofacial bones. POF is categorised into two types, central and peripheral variety. The central ossifying fibroma arises from periodontal ligaments adjacent to the root apex and expands from the medullary cavity of the bone. Peripheral ossifying fibroma shows a close relationship with periodontal ligament occurs solely on the soft tissues overlying the alveolar process. According to literature, POF is not the peripheral counterpart of the central ossifying fibroma, but instead POF is a reactive gingival lesion known under the entity of epulis.

According to literature, patient's age, site and size of the lesion is second decade, anterior maxilla and less than 2 cm respectively which was not consistent with our case. Clinically poor oral hygiene and displacement of teeth are common findings in POF but was absent in our case. Case series of 5 patient published by Kale L et al. (2013) showed similarity in clinical features as our case except in size. Two of their cases had no radiographic evidence of calcification.<sup>5</sup> A similar case of POF was reported by Bhasin M et al. (2013), in which a single, pale, painless, well-defined gingival swelling in maxillary anterior region was present, which gradually increased in size over a period of 3 years. Radiographically it showed irregular radiopacity with density almost similar to the bone interspersed in the soft tissue shadow.<sup>1</sup>

A POF is usually smaller in size and does not require any further imaging investigation in addition to plain radiographs. Radiographic changes may not be always seen in POF, but foci of radiopaque material may occasionally visible, mainly in large lesions or lesions with overt mineralisation, as in our case.<sup>6</sup> A mild cupping defect of alveolar bone adjacent to the lesion, migration of teeth, interdental bone loss can be seen in some cases but was not present in present case. In present case, the lesion had reached to large size over ten years and the origin could not be determined on clinical examination. Hence, CECT was advised which showed expansile lesion epicentered in alveolar process of maxilla on left side with minimally

enhancing soft tissue areas and areas of calcification.

Multicentric variety of POF can occur in the oral and maxillofacial region, and have been observed in association with nevoid basal cell carcinoma syndrome, multiple endocrine neoplasia type II, neurofibromatosis, Gardner syndrome.<sup>6</sup>

Histologically, POF shows non-encapsulated mass of cellular fibroblastic connective tissue of mesenchymal origin, covered with stratified squamous epithelium, it can be ulcerated in 23-66% of cases. POFs contains areas of fibrous connective tissue, endothelial proliferation, and mineralization. Endothelial proliferation is predominant in the areas of ulceration, which can mislead clinical diagnosis, as a pyogenic granuloma. The mineralized component of POF varies, occurring in approximately 23-75% of cases according to published reports. Mineralization can be in the form of cementum-like material, bone and dystrophic calcification.<sup>5</sup>

The differential diagnosis of POF includes traumatic fibroma, peripheral giant cell granuloma and pyogenic granuloma and peripheral odontogenic fibroma. Traumatic fibroma usually seen on buccal mucosa along the occlusal plane. Peripheral giant cell granuloma shares clinical features with POF however POF lacks purple or blue discoloration which is commonly associated with peripheral giant cell granuloma and radiographically shows flecks of calcification. Pyogenic granuloma present as a small, soft, friable nodule, with tendency of bleeding and may or may not show calcifications but tooth displacement and resorption of alveolar bone are absent. Peripheral odontogenic fibroma is an uncommon neoplasm, believed to be arising from odontogenic epithelial rests in PDL or attached gingiva.<sup>7</sup>

Without treatment, POF can increase in size and interfere with normal mastication, thereby necessitating early diagnosis and initiation of effective treatment. Close postoperative follow-up is required because of growth potential of incompletely removed lesions and high rate of recurrence reported in literature. Incidences of recurrence have been reported as 16–20% and is due to incomplete excision of POF and/or persistence of local irritants.

A soft tissue mass which is slowly growing with speckled calcification in the anterior region of oral cavity of children or young adults should suspect the possibility of a reactive gingival lesion such as POF. Hence the occurrence of POF in a 57-year old female patient with involvement of maxillary posterior alveolus can be considered a rarity.

### 4. Source of Funding

None.


### 5. Conflict of Interest


None.


## References


1. Bhasin M. Peripheral ossifying fibroma. *Case Rep Dent.* 2013;2013:497234. doi:10.1155/2013/497234.
2. Delbem A, Cunha RF, Silva JZ, Pires AM. Soubhiac Peripheral Cemento-Ossifying Fibroma in Child. A Follow-Up of 4 Years. Report of a Case. *Eur J Dent.* 2008;2:134–7.
3. Shetty DC, Urs AB, Ahuja P, Sahu A, Manchanda A, Sirohi Y. Mineralized components and their interpretation in the histogenesis of peripheral ossifying fibroma. *Indian J Dent Res.* 2011;22(1):56–61.
4. Sujatha G, Sivakumar G, Muruganandhan J, Selvakumar J, Ramasamy M. Peripheral ossifying fibroma-report of a case. *Indian J Multidiscip Dent.* 2012;2(1):415–8.
5. Kale L, Khambete N, Sodhi S, Sonawane S. Peripheral ossifying fibroma: Series of five cases. *J Indian Soc Periodontol.* 2014;18(4):527–57.
6. Kumar SK, Ram S, Jorgensen MG. Multicentric peripheral ossifying fibroma. *J Oral Sci.* 2006;48(4):239–82.
7. Neville BW, Damm DD, Allen CM, Bouquot JE. Oral and Maxillofacial Pathology. and others, editor. Elsevier; 1995. p. 912.

## Author biography


**Manisha Tanaji Sherkhane**, Post Graduate Student  
 <https://orcid.org/0000-0002-5933-4326>

**Antu Kizhaketodiyail**, Post Graduate Student  <https://orcid.org/0000-0001-8972-3085>

**Bindu Pekkodath**, Lecturer  <https://orcid.org/0000-0003-4122-3385>

**Divya Kallanchira Devraj**, Assistant Professor  <https://orcid.org/0000-0003-4260-370X>

**Lidiya Thomas**, Assistant Professor

**Nileena R Kumar**, Associate Professor  <https://orcid.org/0000-0003-2438-8575>

**Cite this article:** Sherkhane MT, Kizhaketodiyail A, Pekkodath B, Devraj DK, Thomas L, Kumar NR. A giant peripheral ossifying fibroma-A case report. *IP Int J Maxillofac Imaging* 2023;9(1):39-42.