

Content available at: <https://www.ipinnovative.com/open-access-journals>

IP International Journal of Maxillofacial Imaging

Journal homepage: <https://www.ijmi.in/>

Case Report

Langerhans cell histiocytosis mimicking necrotizing ulcerative periodontitis - A case report

Antu Kizhakeethodikayil^{1,*}, Manisha Tanaji Sherkhane¹, Bindu Pekkodath¹,
Divya Kallanchira Devraj¹, Lidiya Thomas¹, Nileena R Kumar¹

¹Dept. of Oral Medicine and Radiology, Govt Dental College, Kozhikode, Kerala, India



ARTICLE INFO

Article history:

Received 16-12-2022

Accepted 16-02-2023

Available online 18-04-2023

Keywords:

LCH

Histiocytosis X disease

Letterer Siwe

Han Schuller Christian disease

Eosinophilic granuloma

ABSTRACT

Langerhans cell histiocytosis (LCH) is a rare disease characterized by abnormal proliferation of bone marrow derived histiocytes followed by their deposition in tissues elsewhere in the body causing damage. Oral manifestations of LCH can sometimes be the only presenting symptoms or the first sign of a disseminated disease. Ulcerated lesions of oral mucosa are one of the common clinical manifestations and can help in early diagnosis of the disease when presented. Since the clinical features mimics several other diseases of oral and maxillofacial region it can be misdiagnosed easily as other pathologies. This article highlights the clinicopathological features of a case of LCH in an elderly patient who has reported to our outpatient department.

This is an Open Access (OA) journal, and articles are distributed under the terms of the [Creative Commons Attribution-NonCommercial-ShareAlike 4.0 License](https://creativecommons.org/licenses/by-nc-sa/4.0/), which allows others to remix, tweak, and build upon the work non-commercially, as long as appropriate credit is given and the new creations are licensed under the identical terms.

For reprints contact: reprint@ipinnovative.com

1. Introduction

LCH is an unusual pathologic entity characterised by abnormal proliferation of histiocytes and their infiltration into specific organ systems. It is common in children with a male predilection. Earlier designated as Histiocytosis X disease which included Letterer Siwe, Han Schuller Christian disease, and Eosinophilic granuloma. In jawbones, mandible, particularly the molar region is the more frequently affected site.¹⁻⁴ Swelling accompanied by dull aching pain are the classic symptoms of bone lesions and soft tissue extensions present as severe ulcerations. Because of its rarity, these can be misdiagnosed as other benign or malignant jaw lesions and hence their accurate diagnosis is challenging.

The pathophysiology is disturbed intercellular communication between T cells and antigen-presenting Langerhans cells which cause release of proinflammatory

mediators and leads to proliferation and accumulation of histiocytes causing tissue damage. However, the discovery of the clonal nature of LCH cells in 1994, followed by the discovery of a mutation in the BRAF oncogene in several neoplasms and in 50% of LCH cases suggests a neoplastic etiology.¹

The histiocytosis X classification was proposed by Lichtenstein in 1953 and included the following: (I) Acute disseminated histiocytosis X (Letterer-Siwe disease), with multiple systemic involvement; mostly seen in children younger than 3 years of age and is characterized by fever, haemorrhagic tendency, progressive anaemia, hepatosplenomegaly, lymphadenopathy, and gingival hyperplasia.(II) Chronic disseminated histiocytosis X (Hand-Schuller-Christian disease), with multiple osseous lesions, and extra skeletal lesions, especially in the lungs; most commonly occurs in children younger than 5 years of age characterised by the triad of bone lesions, diabetes insipidus, and exophthalmos and (III) Chronic, localized histiocytosis X (Eosinophilic Granuloma), with solitary

* Corresponding author.

E-mail address: antukt1993@gmail.com (A. Kizhakeethodikayil).

or multiple skeletal lesions and occasional extra skeletal involvement especially in the lungs.⁵⁻⁹

The Langerhans cells are believed to be of histiocytic origin and are dendritic mononuclear cells normally found in mucosa, lymph nodes, epidermis and bone marrow and their abnormal proliferation is diagnostic of histiocytosis. Most often patients have varied clinical presentations with overlapping features.

Bone lesions accompanied by dull aching pain are the most common clinical presentation. The jaws are affected in 10% to 20% of all cases. Both maxilla and mandible are affected with posterior mandible the most commonly involved site. Early lesions are usually well defined radiolucencies without cortication. Excessive bone destruction causes loosening of the teeth which appear as floating in air and can cause premature loss of teeth mimicking severe periodontitis. When soft tissue components are involved, they present often as ulcerations and or proliferative mucosal lesions.

Microscopy in Langerhans cell histiocytosis show a diffuse infiltration of large, pale-staining mononuclear cells that resemble histiocytes along with varying amounts of eosinophils and other inflammatory cells. Electron microscopic evaluation of Langerhans cells contain rod-shaped cytoplasmic inclusion known as Birbeck granules. Immunohistochemical procedures should identify CD-1a or CD-207 (langerin) markers specific for Langerhans cell histiocytosis or nonspecific antibodies such as protein S-100. Disease is fatal in infants and very young children with multisystem involvement and has a better prognosis in elderly with less visceral involvement.

The treatment varies, based on the clinical presentation and the time of diagnosis of the disease. Though a self-limiting disease in many of the cases, curettage, systemic and intralesional steroids, antibiotics, chemotherapeutic agents and low-dose radiation are also used.

2. Case Report

A 59-year-old male patient reported with the chief complaint of bleeding from gums since 8 months. There was associated mild pain and irritation while chewing food. There was no history of any fluid or pus discharge. He gave occasional history of fever and cough. He had no significant medical or family history. He was moderately built and nourished and well oriented. On extra oral examination no abnormal findings detected. Oral hygiene was very poor with halitosis. Intra oral examination revealed generalized gingival erythema with inflammatory hyperplasia and multiple ulcerations of varying sizes, covered with superficial pseudomembranous slough. Palatal gingiva and mucosa was granular in appearance. Proliferative gingival masses resembling granulomas were seen in the palate all of which were mimicking inflammatory periodontal disease. On palpation gingiva was non tender, soft in consistency,

and bleeding was present.

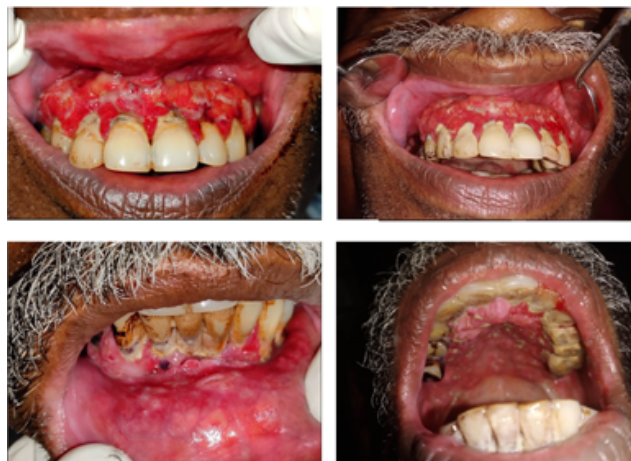

Fig. 1: Intraoral view showing, erythematous, hyperplastic gingiva with ulcerations

Multiple mobile teeth with periodontal pockets and gingival recessions were noted.

A panoramic radiograph was taken which showed relevant radiographic features like generalized severe alveolar bone loss with widened periodontal ligament space and floating tooth appearance of mandibular incisors. The patient was referred for biopsy which established the diagnosis of LCH. Immunohistochemistry was done which was positive for CD-1a and S100 protein and the patient was referred to surgical oncology department for further management.

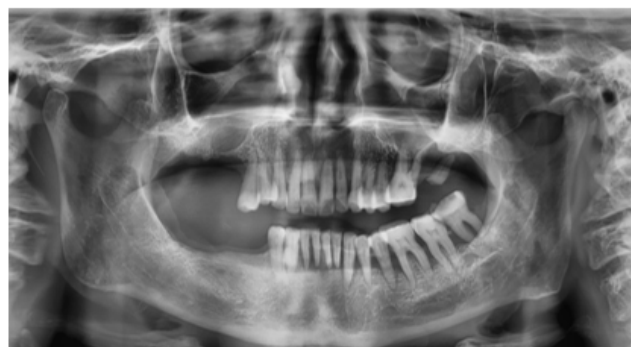

Fig. 2: Panoramic radiograph showing severe bone loss with widening of periodontal ligament space and floating tooth appearance of lower incisors, multiple missing teeth and a root stump.

3. Discussion

Langerhans cell histiocytosis, formerly called histiocytosis X, comprises a group of conditions that are characterized histologically by clonal proliferation of large mononuclear histiocytic cells. Lichtenstein classified LCH into three

clinical forms depending on the age of the patient when the lesions first appear and their distribution.² Chronic focal LCH (eosinophilic granuloma), Chronic diffuse LCH (Hand-Schuller-Christian disease), Acute disseminated LCH (Letterer-Siwe disease) and Congenital reticulohistiocytosis (Hashimoto-Pritzker syndrome) which is believed to be a purely cutaneous form, characterized by the appearance of dark nodules on the trunk, face and scalp. The mucosa is always involved, without implication of other organs. Lesions commonly occur between first and third decade of life though it can occur at any age with a male predilection. Possible aetiology includes a dysfunction of the immune system, with a resultant abnormal proliferation of the histiocytes macrophage system, mutation in BRAF oncogene, and viruses like Epstein Barr have been implicated.

Different types of lesions produced by LCH in the maxilla and mandible are described according to their radiological findings.²

1. Solitary intra-bony lesions: localized outside the alveolar process, these are the most frequent in the initial phases. The images are circular or elliptical, solitary or unifocal, found principally in the body and ramus of mandible. They may be obvious and painful, causing facial swelling, or they may be asymptomatic being an incidental radiographic finding.
2. Multiple alveolar lesions: normally present with well-defined though not corticated margins. However, 37.7% of alveolar lesions may have poorly-defined or invasive margins.
3. ‘Scooped-out’ alveolar lesions: formed by bone destruction beginning below the alveolar crest, either at furcal level or at half the tooth root height and normally a part of the coronal portion of the bone crest remains intact on the mesial and or distal margin of the damaged bone. This form of intra-bony destruction is not seen in periodontal disease, and may therefore be useful in a differential diagnosis.
4. Alveolar lesions with bone sclerosis: common in inflammatory lesions of the jaws, the fact that sclerosis appears in alveolar lesions in LCH may be explained by the communication of these with the oral cavity with added infection.
5. Alveolar lesions with bone neoformation: formation of new bone in lesions classified as intra-bony is observed in a high number of cases. This is a relevant characteristic when differentiating LCH lesions from those of periodontal disease.
6. Mucosal lesions: These are ulcerated, ovoid or round lesions, with erythematous, inflamed borders, painful on palpation. They are localized principally in the buccal mucosa and at the back of the vestibule. They are associated with cutaneous lesions such as the

typical eczematoid rash, that may be confused with a sebaceous dermatitis. Occasionally subcutaneous nodules present, therefore the initial evaluation of the patient should also include a meticulous skin examination.

Some unusual cases of oral soft tissue lesions in the absence of bone lesions have been described. The mucosal lesions are usually accompanied by enlargement of the lymph nodes which also reflects the degree of histiocytic infiltration. Thirty percent of patients with oral lesions present cervical lymphadenopathies.

Periodontal lesions- As new osteolytic areas develop, accompanying gingival ulceration and inflammation are observed, such that all the quadrants of the oral cavity are affected to a greater or lesser degree, even though the process began initially in only one quadrant. This pattern was almost similar to the case presented here with severe bone loss and all the quadrants were effected.

This article demonstrates the clinicopathological and radiographic features of a case of LCH and the difficulties encountered during diagnosis. The reasons for these cases being initially misdiagnosed as other mucosal or periodontal diseases could be the rarity of LCH, usual asymptomatic nature and the clinical presentations similar to these pathologies.

In some cases oral manifestations can be the only presentation as seen in this case. As there are no pathognomonic features diagnosis is confirmed after histopathology.

Histopathological examination revealing Langerhans cells accompanied with eosinophils and other inflammatory cells along with positive immunochemistry for CD-1a, CD-207 and S-100 protein along with clinical and radiographic features confirm the diagnosis. LCH should be differentiated from odontogenic cysts and tumours, brown tumour of hyperparathyroidism, osteomyelitis, metastatic diseases, severe periodontal and periapical inflammatory lesions, lymphoma, leukaemia and sarcoidosis due to overlapping clinical and radiographic features. In most cases it can be a self-limiting disease but is usually fatal in very young patients and has somewhat better prognosis in elderly with less visceral and multifocal involvement.

Bone curettage, antibiotics, chemotherapy, radiotherapy, systemic and intralesional corticosteroids are generally used for the management. Since the developing tooth buds are prone to get exposed during radiation and as there are chances of developing other tumours in the future radiotherapy is not usually considered in children.

4. Conclusion

Even though Langerhans cell histiocytosis is a rarity in the oral cavity it is an interesting site because of the different tissues that may be involved and the varying

clinical features of the disease process. Posterior mandible is the commonly effected site in jaw bones with lesions mainly presenting as swelling and those effecting soft tissues as ulcerations. A radiolucent lesion with ill-defined margins is the common imaging finding. Careful emphasis should be given to differentiate these lesions from other benign and malignant diseases affecting maxillofacial region because of similar clinicopathological and radiographic features and to diagnose the disease at the earliest.

5. Source of Funding

None.


6. Conflict of Interest


None.

References


1. Faustino I, Fernandes PM, Pontes H, Mosqueda-Taylor A, Santos-Silva AR, Vargas PA. Langerhans cell histiocytosis in the oral and maxillofacial region: An update. *J Oral Pathol Med.* 2021;50(6):565–71.
2. Martínez-Pereda CM, Rodríguez VG, Moya BG, Me C. Langerhans cell histiocytosis: Literature review and descriptive analysis of oral manifestations. *Med Oral Patol Oral Cir Bucal.* 2009;14(5):222–8.
3. Moghadam SA, Lotfi A, Piroozhashemi B, Mokhtari S. A Retrospective Analysis of Oral Langerhans Cell Histiocytosis in an Iranian Population: a 20-year Evaluation. *J Dent (Shiraz).* 2015;16(3):274–7.
4. Jezierska M, Stefanowicz J, Romanowicz G, Kosiak W, Lange M. Langerhans cell histiocytosis in children - a disease with many faces. Recent advances in pathogenesis, diagnostic examinations and treatment. *Adv Dermatol Allergol.* 2018;35(1):6–17.
5. Silva RN, Fernandes DT, Fonseca FP, Pontes R, Brasileiro HA, Santos-Silva BF. Oral manifestations of Langerhans cell histiocytosis: A case series. *Spec Care Dent.* 2018;38(6):426–59.
6. Difloe-Geisert JC, Bernauer SA, Schneeberger N, Bornstein MM, Walter C. Periodontal manifestations of Langerhans cell histiocytosis: a systematic review. *Clin Oral Investig.* 2021;25(6):3341–50.
7. Capodiferro S, Tempesta A, Limongelli L, Ingravallo G, Maiorano E, Sfasciotti GL. Primary Oro-Facial Manifestations of Langerhans Cell Histiocytosis in Pediatric Age: A Bi-Institutional Retrospective Study on 45 Cases. *Children (Basel).* 2020;7(9):104. doi:10.3390/children7090104.
8. Dagenais M, Pharoah MJ, Sikorski PA. The radiographic characteristics of histiocytosis X. A study of 29 cases that involve the jaws. *Oral Surg Oral Med Oral Pathol.* 1992;74(2):230–6.
9. Altay MA, Sindel A, Özalp Ö, Kocabalkan B, Özbudak İ, Erdem R. Langerhans Cell Histiocytosis: A Diagnostic Challenge in the Oral Cavity. *Case Rep Pathol.* 2017;(1691403.):1–6. doi:10.1155/2017/1691403.

Author biography


Antu Kizhaketodikayil, Post Graduate Student  <https://orcid.org/0000-0001-8972-3085>

Manisha Tanaji Sherkhane, Post Graduate Student  <https://orcid.org/0000-0002-5933-4326>

Bindu Pekkodath, Lecturer  <https://orcid.org/0000-0003-4122-3385>

Divya Kallanchira Devraj, Assistant Professor  <https://orcid.org/0000-0003-4260-370X>

Lidiya Thomas, Assistant Professor  <https://orcid.org/0000-0002-7583-4531>

Nileena R Kumar, Associate Professor  <https://orcid.org/0000-0003-2438-8575>

Cite this article: Kizhaketodikayil A, Sherkhane MT, Pekkodath B, Devraj DK, Thomas L, Kumar NR. Langerhans cell hystiocytosis mimicking necrotizing ulcerative periodontitis - A case report. *IP Int J Maxillofac Imaging* 2023;9(1):43–46.