

Content available at: <https://www.ipinnovative.com/open-access-journals>

IP International Journal of Maxillofacial Imaging

Journal homepage: <https://www.ijmi.in/>

## Case Report

# Oral epithelial dysplasia and smoker: A case report

Shikha Parihar<sup>1,\*</sup>, Viniti Goel<sup>1</sup>, Deepak Bala<sup>1</sup>, Deepak Grover<sup>1</sup>

<sup>1</sup>Dept. of Periodontology and Oral Implantology, Bhojia Dental College and Hospital, Baddi, Himachal Pradesh, India



### ARTICLE INFO

#### Article history:

Received 14-01-2023

Accepted 14-02-2023

Available online 18-04-2023

#### Keywords:

Whitish lesion

Dysplasia

Smokeless tobacco habit

Potentially malignant disorders (OMP)

Malignant transformation (MT)

### ABSTRACT

Whitish lesion present in oral mucosa may present with dysplasia in cases when there is association of smoking or smokeless tobacco habit as in tobacco abuse risk factor is increased for development of pre-malignant lesion which makes screening of oral cavity with proper diagnostic tool for definitive diagnosis very important. In this case report finding of severe dysplasia associated with a strong habit of smokeless tobacco and incisional biopsy is discussed.

This is an Open Access (OA) journal, and articles are distributed under the terms of the [Creative Commons Attribution-NonCommercial-ShareAlike 4.0 License](https://creativecommons.org/licenses/by-nc-sa/4.0/), which allows others to remix, tweak, and build upon the work non-commercially, as long as appropriate credit is given and the new creations are licensed under the identical terms.

For reprints contact: [reprint@ipinnovative.com](mailto:reprint@ipinnovative.com)

## 1. Introduction

Oral epithelial dysplasia is defined as an epithelial tissue in which prevalence of oral squamous cell carcinoma is higher than its healthy counterparts. It is a common pre-malignant condition affecting almost 2.5 – 5 per 1000 population.<sup>1</sup> World-wide its prevalence is 1-5%. In India OPMDs reported to have 80% of oral cancers preceded by OPMDs. The dysplastic abnormality observed in oral lesions is known as oral potentially malignant disorders (OPMDs)<sup>2</sup> which is a diverse category of oral lesions in relation to an enhanced chance of malignant transformation to infiltrating/invasive cancer. The most common OPMDs include leukoplakia, lichen planus, oral lichenoid lesions, oral submucous fibrosis etc. Leukoplakia is most commonly detected in dysplastic conditions in dental clinics.<sup>3</sup> Oral cancer is usually observed in individuals with habits (tobacco, areca nut and snuff) which may become malignant with time if not controlled.<sup>4</sup> The word dysplasia means abnormal growth. Histology is considered the gold standard in diagnosis of various dysplastic conditions. So, in this

case incisional biopsy was performed in aid for definitive diagnosis and histopathological study.<sup>5</sup> The MT of any dysplastic condition is measured by the presence and degree of epithelial dysplasia.<sup>3</sup> The dysplastic changes may reverse back to standard state once the primary agitating factor is eliminated. Dysplastic features in stratified squamous epithelium are distinguished by cellular atypia and loss of normal maturation and stratification. WHO in 1978 defined and graded characteristics of epithelial dysplasia as mild, moderate and severe depending on whether dysplastic features were confined to the lower third, middle third and the upper third of the epithelium, respectively and was published it in the “Histopathological typing of cancer and precancer of the oral mucosa,” in 1997. So, it is inferred that “Biopsy” is a best diagnostic tool in Periodontal diagnosis.<sup>2</sup>

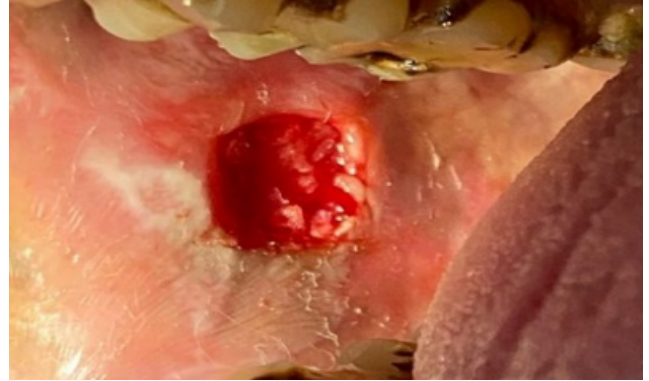
## 2. Case Report

A 37 years male patient reported to Department of Periodontology, Bhojia Dental College and Hospital, Baddi with the chief complaint of pain since 15 days in right lower back region. History of present illness revealed that patient had a burning sensation of mouth on consuming

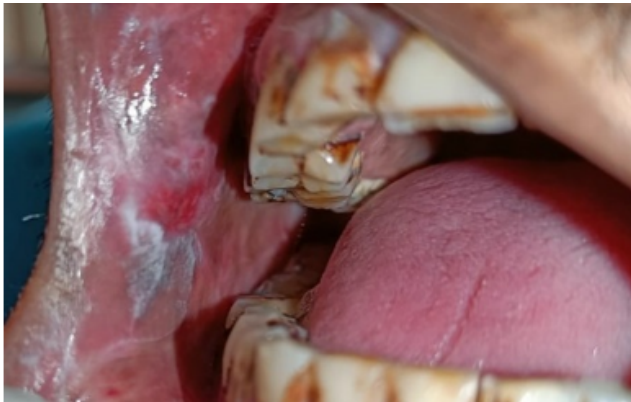\* Corresponding author.

E-mail address: [shikhaparihar933@gmail.com](mailto:shikhaparihar933@gmail.com) (S. Parihar).

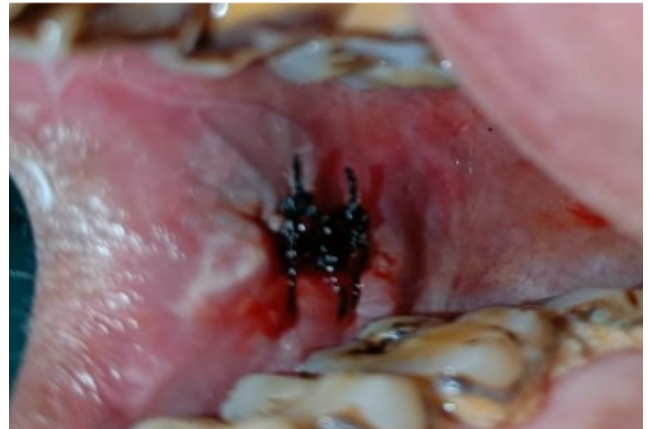hot & spicy food and restricted mouth opening. Personal history revealed tobacco, ghutka chewing and alcohol consumption since last 20 years. On intra-oral examination there was restricted mouth opening of about 25 mm, bilateral blanching of buccal mucosa, firm consistency, non-scrapable whitish lesion with irregular border was found on both right & left buccal mucosa extending from distal aspect of 13 to mesial aspect of 17 w.r.t. occlusal plane, similar lesion extending from mesial aspect of 34 to distal aspect of 37 was observed on contra-lateral side. Based on the clinical examination and prevalent habit of chewing tobacco & ghutka, a differential diagnosis of leukoplakia & oral submucous fibrosis was given. So, after initial examination, incisional biopsy was planned from right buccal mucosa to confirm the diagnosis. An informed consent was obtained, following which the surgical incisional biopsy was performed.



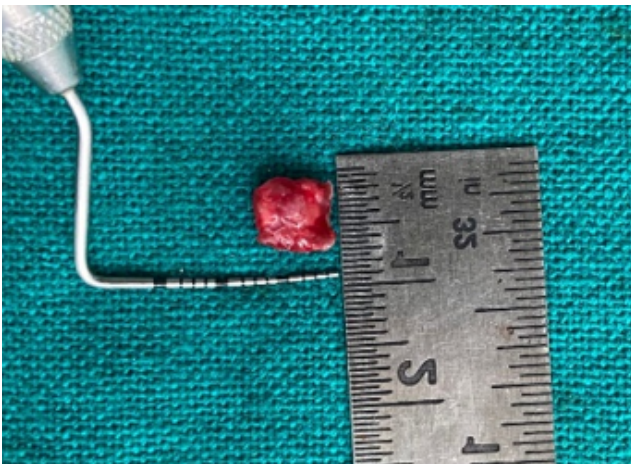
**Fig. 3:** Surgical site



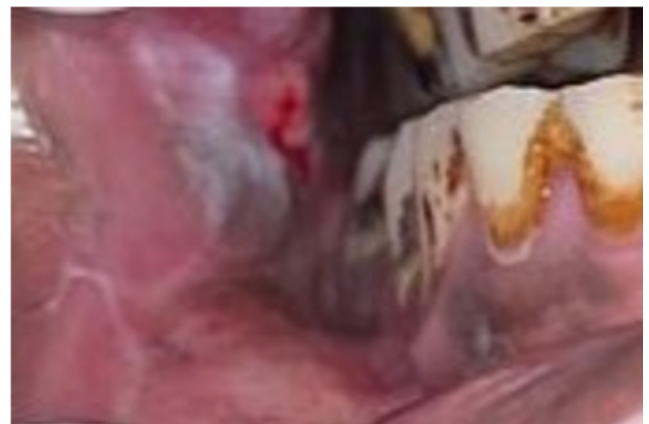**Fig. 1:** Pre-operative photograph



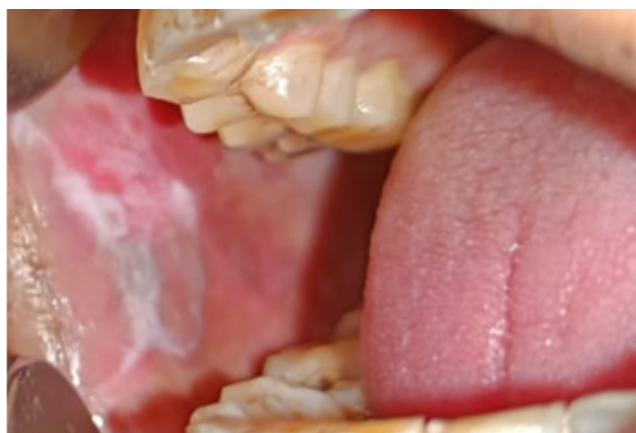**Fig. 4:** Interrupted sutures placed



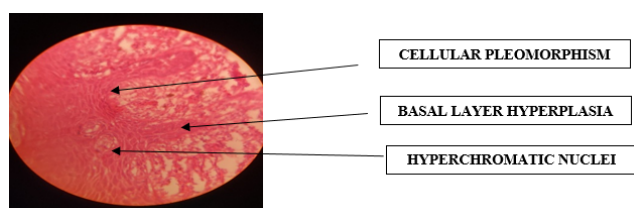
**Fig. 2:** Tissue excised for biopsy



**Fig. 5:** Post-operative photograph after 10 days



**Fig. 6:** Post-operative photograph after 1 month



**Fig. 7:** 40X histopathological picture depicting severe dysplasia

### 2.1. Surgical procedure

1. Proper aseptic conditions and proper sterilization protocol was followed.
2. Patient was advised to do oral rinse with chlorohexidine mouthwash 0.2%.
3. Surgical site was anesthetized by local infiltration with 2% lignocaine containing 1:80000 adrenaline.
4. Incisional biopsy under local anesthesia was performed to confirm the diagnosis and interrupted sutures were given to the patient.
5. 6×6×2mm lesion was taken after biopsy from the right-side buccal mucosa and sent to Department of Oral & Maxillofacial Pathology for needful diagnosis.

Post-operative instructions were given to the patient. The patient was discharged and given post-operative instructions especially to avoid spicy foods. Patient was recalled after 24 hours of surgery for the follow-up post-operatively and further instructions were given. The patient was strickly instructed to quit oral habit of consuming smokeless tobacco & alcohol. Patient was advised to maintain oral hygiene. Oral hygiene instructions were reinforced to the patient. Oral Antioxidant once daily was prescribed to patient for 1 month. Following which patient was instructed for a follow up after 8 days for suture removal. Sutures were removed following 8 days and irrigation was done. The patient was again advised for a follow-up after a month. Oral hygiene instructions were repeated. On post-operative follow up

after a month, healing was not found to be satisfactory. On examination patient revealed that he was still consuming alcohol and tobacco once a day which was obtained and patient was counselled for quitting of tobacco.

### 2.2. Histopathological report

On histological examination, the H and E stained section showed epithelium & connective tissue. The epithelium presented with ortho-keratinized stratified squamous epithelium.  $2/3^{rd}$  of the epithelium showed dysplastic features like basal layer hyperplasia and loss of basal polarity along with increased nuclear cytoplasmic ratio in the suprabasal layers. Hyperchromatic nuclei were observed with nuclear & cellular pleomorphism. The underlying connective tissue stroma showed collagen fibers with blood vessels & inflammatory infiltrate. The histopathological examination revealed severe dysplasia.

### 2.3. Clinical photographs

Treatment advised to patient was completely palliative and complete recall schedule was told and patient was advised to consult PGIMER, Chandigarh for tobacco & alcohol abuse so that further treatment could be done.

## 3. Discussion

Histopathology is widely used for diagnosis of epithelial tissues. Diagnosis by histopathology has been used as a diagnostic equipment as well as for its prognostic significance for epithelial diseases. Buccal mucosa is second most common area of oral epithelial dysplasia according to Dost F et al. (2004).<sup>6</sup> The success of histological grading of predecessor lesions as an index of malignant alteration has been listed in the literature. The present documentation recognizes carcinogenesis of epithelium as a multiphase, ongoing, accumulative process of genetic variation which conclude in tumour formation, and eventually infiltration/invasion and metastasis (N Gale et al.).<sup>7</sup> Oral squamous cell carcinoma (OSCC) is not linear in growth, however there is a consensus that it starts with simple epithelial hyperplasia and advances through oral epithelial dysplasia, with severe dysplastic changes representing large-scale variation in genetic.<sup>6</sup>

The initial diagnosis, treatment and monitoring of the precancerous lesions are prime variable in averting its development to oral dysplasia. Depending upon the severity of the cellular alterations and the thickness of the epithelium involved, oral lesions may be classified histopathologically as squamous hyperplasia, mild dysplasia, moderate dysplasia, severe dysplasia and carcinoma-in-situ (CIS). It is usually observed that subset of OPMDs may transform to cancerous lesion even after treatment and proper follow-up.<sup>8-11</sup> However, its transformation to cancer cannot be guessed due to lack of

proper parameters. It is observed that complete excision does not absolutely eradicate its risk of transformation but it does decrease the risk by removing visible characteristic of dysplastic mucosa.

Till today, there is no confirmation of treatment successful in averting malignant variation, as even after surgical excision and medical therapy, information on the risk of development to cancer differ greatly from 6% to 36%. Surgical excision has been found to have a high rate of recurrence of about 35%. Surgical therapy even though may be successful in the reduction of lesions: however, relapses and side effects are often noticed even after the therapy such as, loss of function, increased morbidity and need for reconstructive procedures.<sup>1</sup> Further research is required to detect non-invasive as well as constructive treatments. Due to certain controversies, no consensus over the treatment plan and follow-up regime for patients with oral dysplasia is present. The treatment plan differ from incisional to excisional biopsy.<sup>1</sup> Follow-up regime also differ depending on each case from immediate dismissal of the patient to life-long follow-up. All patients should be maintained for a follow-up for reappearance of the lesion. It is important to aware patients about the oral hygiene habits as well as the malignant transformation of these lesions. Along with awareness and reinforced oral hygiene habits combined with proper follow-up can help in reducing and/or monitoring of such conditions. Further, the modifications in treatment procedure such as, pathology tools, based on genetic profile/molecular markers, would assist in enhancing the management of OPMDs.<sup>3</sup>

#### 4. Conclusion

OPMDs are related with wavering rate of malignant development in which tissue biopsy of oral epithelium remains the hallmark of diagnosis. OSCC is often identified in the final stages which decreases chances of favorable outcomes. So, detection of a disease at initial stage is compulsory/ needed for proper therapy, thereby reducing morbidity & mortality in relation with progressed stages of cancer. So, for surgical excision and continued surveillance and compliance for follow-up especially for high-grade lesions and also to check upon tobacco & alcohol abuse is must.

#### 5. Source of Funding

None.

#### 6. Conflict of Interest

None.

#### References

1. Mehanna HM, Rattay T, Smith J, Mcconkey CC. Treatment and follow-up of oral dysplasia - a systematic review and meta-analysis. *Head Neck*. 2009;31(12):1600–9.
2. Ranganathan K, Kavitha L. Oral epithelial dysplasia: Classifications and clinical relevance in risk assessment of oral potentially malignant disorders. *J Oral Maxillofac Pathol*. 2019;23(1):19–27.
3. Iocca O, Sollecito TP, Alawi F. Potentially malignant disorders of the oral cavity and oral dysplasia: A systematic review and meta-analysis of malignant transformation rate by subtype. *Head Neck*. 2019;42(3):1–17.
4. Grady D, Greene J, Daniels TE, Ernster VL, Robertson PB, Hauck W. Oral mucosal lesions found in smokeless tobacco users. *J Am Dent Assoc*. 1990;121(1):117–40.
5. Pindborg JJ, Reichart P, Smith CJ. World Health Organization: Histological typing of cancer and precancer of the oral mucosa. Berlin: Springer Verlag; 1997. p. 1–95. Available from: [http://apps.who.int/iris/bitstream/handle/10665/43552/3540618481\\_eng.pdf;jsessionid=61CF933B2D03951EBC06F3AE8DC7A192?sequence=1](http://apps.who.int/iris/bitstream/handle/10665/43552/3540618481_eng.pdf;jsessionid=61CF933B2D03951EBC06F3AE8DC7A192?sequence=1).
6. Dost F, Cao L, Ford K, Ades P, Farah C. Malignant transformation of oral epithelial dysplasia: a real world evaluation of histopathological grading. *Oral Surgery, Oral Medicine, Oral Pathology and Oral Radiology*. 2014;117(3):343–52.
7. Gale N, Michaels L, Luzar B, Poljak M, Zidar N, Fischinger J. Current review on squamous intraepithelial lesions of the larynx. *Histopathology*. 2009;54(6):639–56.
8. Guneri P, Maghami E, Boyacioglu H, Ho AS, Epstein JB. Outcomes of surgical management of dysplastic oral mucosal lesions versus observation: A systematic analysis. *Otorhinolaryngol Head Neck Surg*. 2019;4:1–6.
9. Al-Dakkak. Oral dysplasia and risk of progression to cancer. *Evid Based Dent*. 2010;11(3):91–3.
10. Jaber MA. Oral epithelial dysplasia in non-users of tobacco and alcohol: an analysis of clinicopathologic characteristics and treatment outcome. *J Oral Sci*. 2010;52(1):13–21.
11. Huff KD, Garren KC, Huff MS. A novel, minimally invasive approach to managing mild epithelial dysplasia. *Gen Dent*. 2010;58(2):126–55.

#### Author biography

**Shikha Parihar**, Post Graduate Student

**Viniti Goel**, Professor and Head

**Deepak Bala**, Reader

**Deepak Grover**, Professor

**Cite this article:** Parihar S, Goel V, Bala D, Grover D. Oral epithelial dysplasia and smoker: A case report. *IP Int J Maxillofac Imaging* 2023;9(1):47-50.