

Content available at: <https://www.ipinnovative.com/open-access-journals>

IP International Journal of Maxillofacial Imaging

Journal homepage: <https://www.ijmi.in/>

## Original Research Article

## Secondary correction of the post-traumatic deformity: A clinical study

Abinandan Patel<sup>1</sup>, Girish G<sup>1</sup>, Ghana Shree S<sup>1,\*</sup>, Preethi Bhat<sup>1</sup>, Nikita Shabadi<sup>1</sup><sup>1</sup>Dept. of Facio-Maxillary Surgery, Sanjay Gandhi Institute of Trauma and Orthopaedics, Bangalore, Karnataka, India

## ARTICLE INFO

## Article history:

Received 07-01-2023

Accepted 20-07-2023

Available online 18-09-2023

## Keywords:

Posttraumatic

Secondary correction

Nonunion

Malocclusion

Secondary infection

## ABSTRACT

**Aim:** The current manuscript explores the outcome of treatment for post-traumatic secondary deformities using the re-fracture of segments by osteotomies of the bone either at the fractured site or by the orthognathic osteotomies with repositioning to its premorbid place followed by internal fixation.

**Materials and Methods:** A total of 14 patients were reported with post-traumatic secondary deformities of the craniofacial region to the Department of Facio-maxillary surgery from January 2019 - July 2022. All patients had varied clinical features including deranged occlusion, anterior open bite, difficulty in mastication, deviated nose, and depressed frontal bone. The radiological findings were mal-union, non-union, malocclusion, and failed implants. All patients were treated with osteotomies and internal fixation with titanium implants.

**Results:** The age range of patients with post-traumatic secondary deformity was from 17-45 years. The reasons for the secondary deformities that we experienced in our institute were excessive delay in initial treatment due to neurosurgical issues, financial issues and SARS-COVID-19, secondary infections due to the immunocompromised status of the patient, and failure of implants leading to non-union. At the end of 3 months follow-up, all patients had satisfactory results.

**Conclusion:** The treatment for post-traumatic secondary deformities by re-osteotomising at the existing previous fracture site and doing reduction with internal fixation and orthognathic osteotomies for chronic malocclusion yields sufficient aesthetic and functional outcomes when there is no loss of hard or soft tissue.

This is an Open Access (OA) journal, and articles are distributed under the terms of the [Creative Commons Attribution-NonCommercial-ShareAlike 4.0 License](https://creativecommons.org/licenses/by-nc-sa/4.0/), which allows others to remix, tweak, and build upon the work non-commercially, as long as appropriate credit is given and the new creations are licensed under the identical terms.

For reprints contact: [reprint@ipinnovative.com](mailto:reprint@ipinnovative.com)

## 1. Introduction

Secondary deformities of the face are a formidable challenge to the reconstructive surgeon. There remains a subset of patients who develop posttraumatic deformity of the craniofacial skeleton due to a variety of reasons such as those related to the fracture itself, viz., severe comminution, bone, and soft tissue loss, and those related to the treatment, viz., excessively delayed initial treatment, lack of definitive treatment, inadequate initial surgical repair, failure of hardware, secondary infection of the site.<sup>1</sup>

A meticulous physical examination that notes all asymmetries in a systematic fashion and proper radiological studies are the foremost steps in the correction of deformities. Along with it, pre-injury photographs if obtainable are prerequisites to compare with the post-operative treatment outcome.<sup>1,2</sup>

The skeletal deformities are predominately corrected by procedures employing extended craniofacial exposure, segmental osteotomies, and bony repositioning. A graduated approach to the correction of regional bony post-traumatic deformities has been formulated.

In our study, we delineate the procedure of re-fracture with segmental osteotomies of the bone with repositioning to its premorbid place.

\* Corresponding author.

E-mail address: [dentdocghana@gmail.com](mailto:dentdocghana@gmail.com) (Ghana Shree S).

## 2. Materials and Methods

This study presents a few challenging cases reported with post-traumatic secondary deformities of the craniofacial region to the Department of Facio-maxillary surgery from January 2020 - July 2022.

Initial evaluation of the patients included the history of primary treatment at the time of initial trauma and a thorough examination to evaluate the skeletal as well as soft tissue deficits.

The interval between the time of acute trauma and the time of secondary correction ranged from 4 weeks to 2 years with a mean of 8 months.

Examination patterns included the position of the globes, orbits, and zygomatic eminence, extra-ocular muscle movements, pupillary size and reaction to light, occlusion, mouth opening, facial asymmetry, contour, facial width, and height.

3D CT scans with axial, coronal, and sagittal views, orthopantomograms, and lateral cephalograms were the radiological investigations that were advised to thoroughly diagnose the issues. Along with it dental models were used as additional investigations and mock surgery was performed on the cast with occlusal splint fabrication when needed.

All patients had varied clinical features depending on the secondary deformities of the involved anatomical region. Patients with post-traumatic secondary deformities of the maxilla and mandible including deranged occlusion, anterior open bite, difficulty in mastication, deviated nose, depressed frontal bone, and malar eminence. The radiological findings were mal-union, non-union, malocclusion, and failed implants.

Osteotomy of bone at the fractured site itself was performed in all cases which underwent secondary corrections within 8-10 weeks since the trauma. In chronic malocclusion cases where the time elapsed from the actual trauma was more than 3 months, orthognathic osteotomies such as Le fort 1 for the maxillary jaw and vertical ramus osteotomy for mandibular correction were performed.

The standard access incisions used were bicoronal, infraorbital rim, lateral brow, upper and lower gingivobuccal sulcus, preauricular, and Risdon approaches according to the anatomical region involved. The deformity sites were exposed and refractured with new osteotomy cuts for proper anatomical alignment and occlusion followed by fixation with new implants.

All patients were followed up for a period of a minimum of 6 months. The intervals of the follow-up were immediate post-op, 1 month, 3 months, 6 months, and 1 year post-op.

Both clinical and radiological parameters were analyzed during the post-treatment period. All the patients were on long-term follow-up.

## 3. Case Report

### 3.1. Case 1

A 20-year-old male patient came to our OPD with a chief complaint of inability and difficulty chewing food. Gave a history of trauma 2 months back and was operated on for the same in rural Bangalore.

Clinical examination revealed deranged occlusion, with anterior open bite and arch bars. OPG revealed rigid fixation of bilateral angle fracture with mini plates (Figure 1).

Intraoperative - The fracture sites were exposed using Risdon's submandibular incision on either side (Figure 2). Careful dissection was done to avoid injury to the marginal mandibular nerve and its branches. The existing implants were removed (Figure 2) and impacted lower third molars were extracted. The fracture segments were mobilized by removing the immature callus and osteotomised at the fractured site with a chisel and mallet. The mandible was brought into accurate occlusion with MMF.

The fractures were fixed with 2.5mm titanium mini plates and 8mm long screws (Figure 2). Before the closure of all incisions, MMF was removed and the stability of fracture fixation and the occlusion were confirmed. Post-operative healing was satisfactory.

The patient had a good functional result and stable occlusion (Figure 1) with no injury to the marginal mandibular nerve as seen in the post-operative pictures (Figure 2).

### 3.2. Case 2

A 27 year-old man presented with untreated posttraumatic deviated nasal deformity and depressed frontonasal bone 2 months after the initial injury (Figure 2) CT revealed an unoperated FNOE (Fronto-nasal orbito ethmoid) fracture (Figure 3).

A bicoronal approach was used to expose the FNOE fractures, followed by elevation of the fractured segments of frontal and nasal bone followed by fixation with titanium implants (Figure 4).

The post-operative healing was good and the patient was completely satisfied with the aesthetic outcome (Figure 3).

### 3.3. Case 3

A 30-year-old male patient came to our OPD with a chief complaint of difficulty in chewing food. Gave a history of gunshot injury 2 years back and had been comatose for 3 months.

Clinical examination revealed deranged occlusion (Figure 5), and CT revealed a fracture of the bilateral condyle (Figure 5).

Intraoperative - Vertical Ramus osteotomy was planned on both sides and was performed with extra oral submandibular incision, As the fracture was 2 years old,

re-osteomisation at the fractured site or locating condyle in the fibrous healed tissue would be difficult hence vertical ramus osteotomy was planned. Careful dissection was done to avoid injury to the marginal mandibular nerve and its branches. Osteotomy was performed from the sigmoid notch to the lower border of the mandible. The mandible was brought into accurate occlusion with MMF.

The osteotomised segments were fixed with a 2 mm titanium 'T shaped' mini plate and screws (Figure 6). Before the closure of all incisions, MMF was removed and the stability of fracture fixation and the occlusion were confirmed. Post-operative healing was satisfactory and the submandibular incision wound was not very evident and correct occlusion was achieved. Post-operative OPG revealed implants on both sides of the angle (Figure 5).

#### 3.4. Case 4

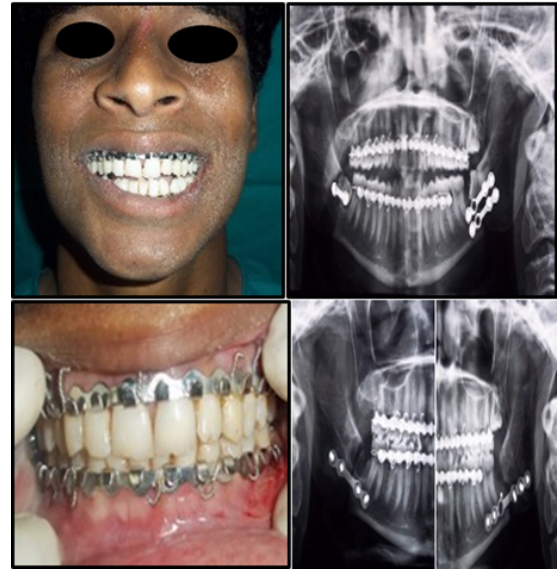
A 27-year-old male patient complained of alterations in his occlusion and retrusion of his midface post-trauma. Gave a history of trauma 2 years back and was operated on in rural Bangalore for his lower jaw. The upper jaw fractures were not addressed then.

Clinical examination revealed reverse overjet occlusion (Figure 7) and retrusion of the middle third of the face (Figure 7). Model analysis was done (Fig. 8) and the surgical plan was charted.

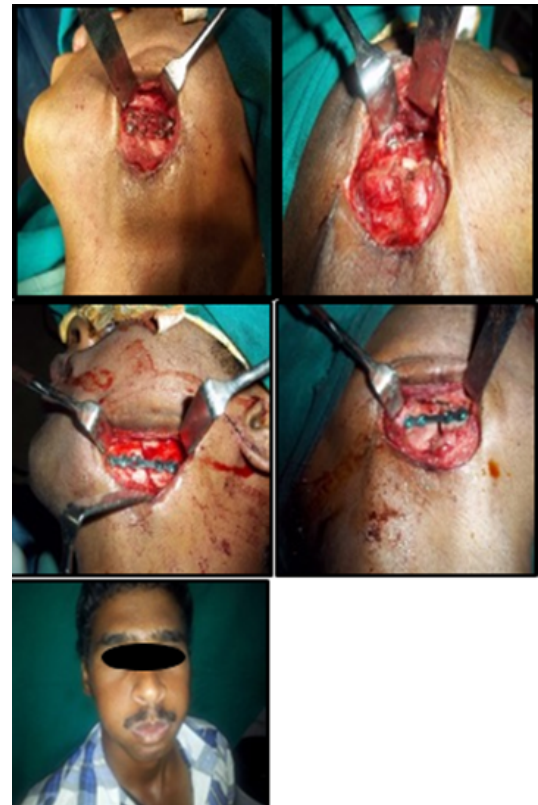Intraoperative, a bilateral maxillary vestibular incision was placed and le fort 1 osteotomy was performed, maxilla was pulled forward, class1 occlusion was obtained according to the splint made, and fixation was done with 2mm titanium mini plates and screws. The post-operative healing was good, class 1 occlusion was maintained (Figure 7) and the patient was completely satisfied with the esthetic outcome (Figure 7).

#### 4. Results

Of the 14 cases, 5 (36%) primary treatment was delayed because of neurosurgical issues. 4 (29%) patients underwent secondary correction due to improper primary treatment and lack of appropriate diagnosis. 3 (21%) patients had undergone secondary correction due to infected implants. 1 (7%) patient came to our center after 3 months of trauma due to financial constraints. One patient (7%) was diagnosed with SARS covid infection on admission and hence treatment was delayed for 3 weeks as the patient had severe respiratory symptoms. 9(64%) cases were operated by re-osteotomizing at the existing fractured site only if the time elapsed was within 8-10 weeks and in 5(36%) cases orthognathic osteotomy cuts such as Lefort1 for maxillary correction in 3 cases and intraoral vertical ramus osteotomy for mandibular correction in 2 cases for prolonged malocclusion with the time elapsed was longer of more than 10 weeks. According to sub-sites in the

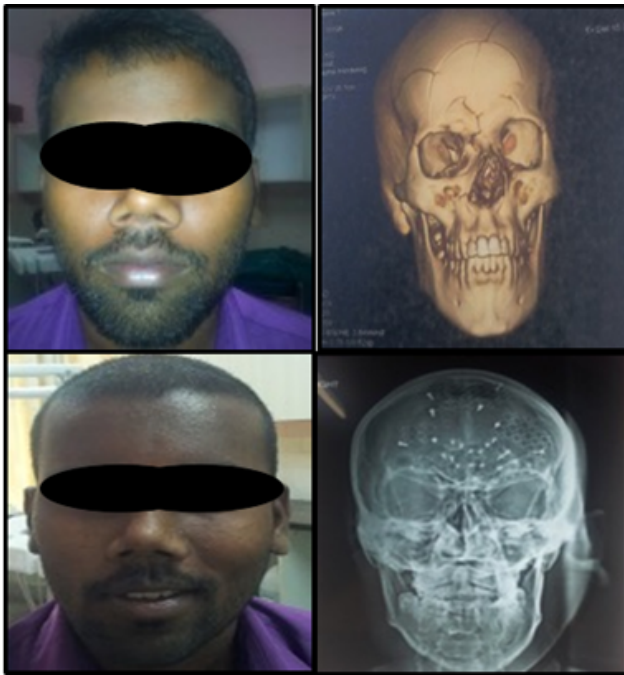

**Fig. 1:** Pre-operative occlusion and OPG (Up), Post-operative occlusion and OPG(Down) Case 1

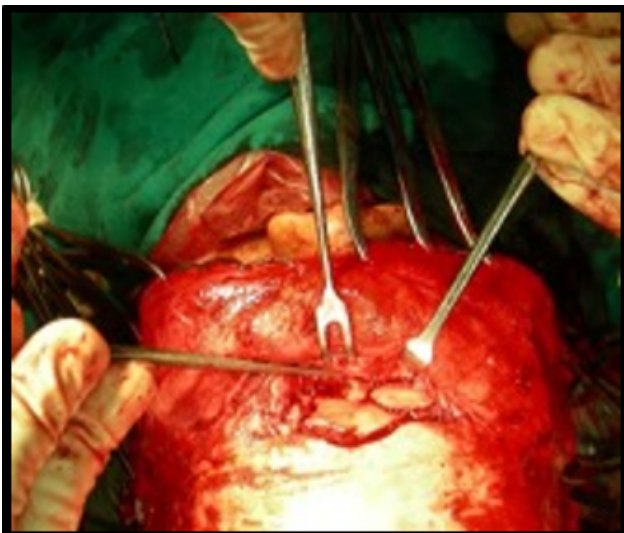

**Fig. 2:** Intraoperative pictures of submandibular incision to expose the fractured site, retrieval of old implants and fixation with new titanium plates (Up) post operative clinical picture showing intact marginal mandibualr nerve (Down) Case 1





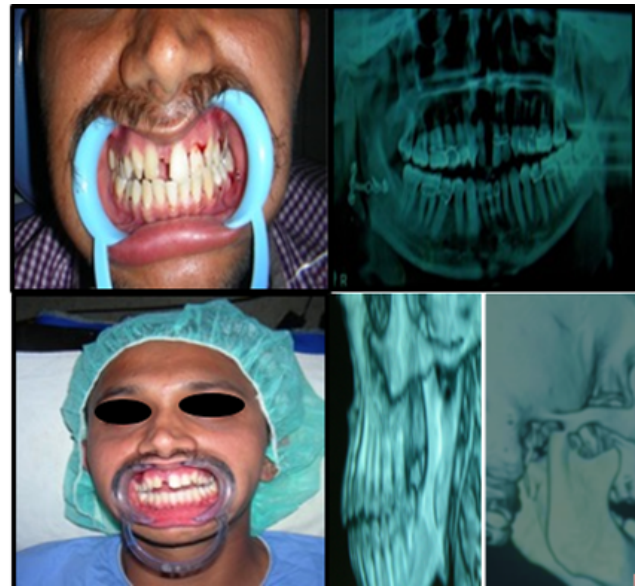**Fig. 3:** Pre-operative clinical picture and radiograph (Up) and Post-operative clinical picture and radiograph (Down) Case 2



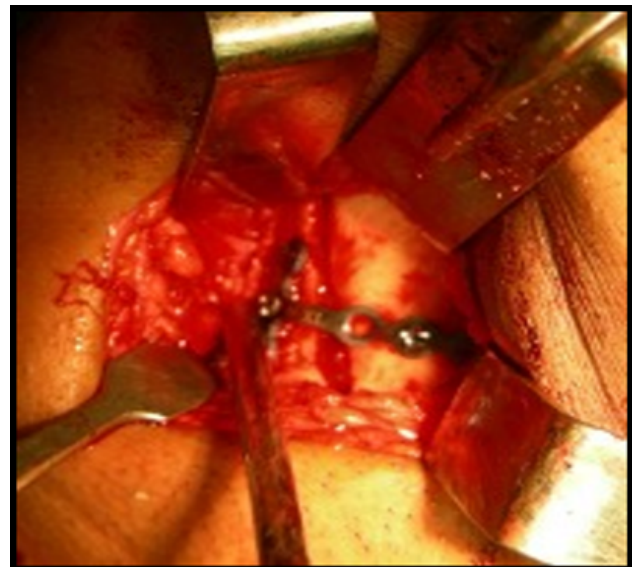
**Fig. 4:** Bicoronal flap to expose the FNOE fracture Case2

anatomical region, 7 (50%) patients underwent secondary correction of the mandible due to occlusal discrepancy, 5 (36%) patients of frontal and naso-orbito ethmoidal deformity underwent correction, 2 (14%) patients had retrusion of midface and underwent maxillary deformity correction.

Patients were followed up at 1 week; 1, 3, 6, and 12 months; and yearly thereafter. The aesthetic and functional outcomes were assessed postoperatively at 3 months.



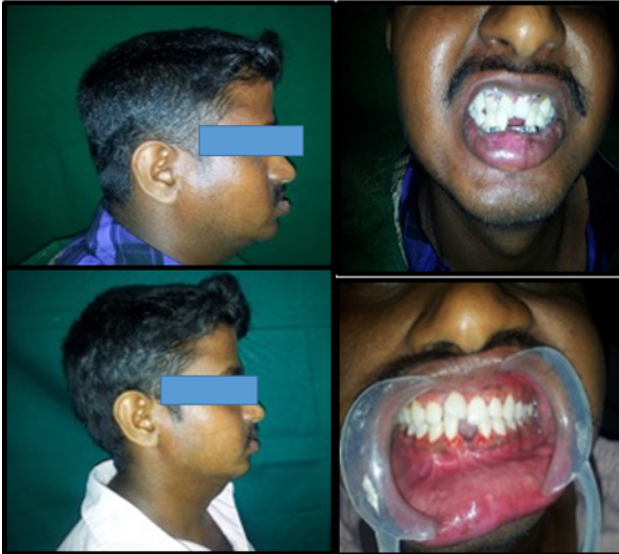**Fig. 5:** Pre-operative clinical picture and radiograph (Up) and Post-operative clinical picture and radiograph showing fixation of the vertical ramus osteotomy.(Down) Case 3



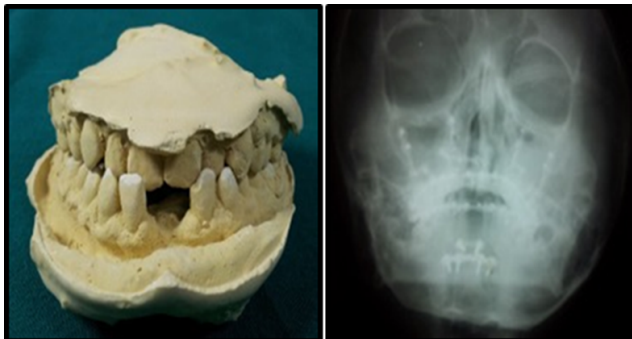**Fig. 6:** Submandibular incision to reach ramus followed by vertical ramus osteotomy Case 3

There was no significant early infection, hemorrhage, minor dehiscence, cerebrospinal fluid leak, eyelid retraction, scalp alopecia, unfavorable scar, facial nerve palsy, or any other late postoperative complications.

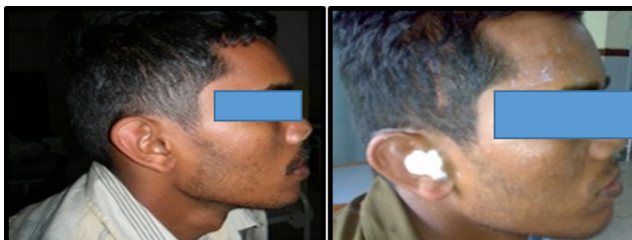The outcome of reosteotomising at the fractured site as well as the orthognathic osteotomies and doing reduction with internal fixation of the post-traumatic secondary deformity cases is satisfactory clinically and functionally when there is no soft or hard tissue loss.



**Fig. 7:** Pre-operative maxillary retrusion with class 3 malocclusion (Up), post-operative corrected maxillary retrusion and Class 1 occlusion (Down) Case 4



**Fig. 8:** Model analysis done pre-operatively (right), post-operative PNS Xray Case 4



**Fig. 9:** Saddle nose deformity correction done by augmentation of nasal dorsum with harvested auricular cartilage

## 5. Discussion

Secondary deformities are a formidable challenge to the surgeon and proper treatment will effectuate profuse positive changes in the person's social and psychological well-being as these surgical corrections along with the restoration of functions and supplement the facial aesthetics.

The tertiary hospital setups in metropolitan cities such as ours allow adequate and appropriate initial treatment of acute craniofacial fractures in a multidisciplinary set-up even with head injury patients using the latest technological advances and well-trained surgeons which is contrary to the other places in the outskirts of the city.<sup>1</sup>

The various other causes for residual secondary deformity are soft tissue infections, large gaps between fractured fragments, comminuted fractures, severe fractures in atrophic bones, osteomyelitis, movements during the healing phase, improper reduction, delayed treatment, teeth in the line of fracture, smoking and alcohol abuse, poor treatment planning, inadequate surgical skills, poor patient compliance.<sup>2</sup>

Management of secondary deformities of bony depressions are corrected by onlay grafts, rigidly fixed with lag screws. Augmentation or reduction procedures which are easier to perform can be undertaken to camouflage the contour deformities of anatomic regions such as malar/zygomatic prominence, nasal and frontal. A wide variety of autogenous tissues (costochondral grafts, free fat grafts, and temporoparietal fascia) and alloplasts such as porous polyethylene implants (Medpor), polymethylmethacrylate (PMMA), silicone are available for this purpose.<sup>2-4</sup>

Malposition of anatomically normal bone but intact skeletal fragments are best corrected by re-fracture osteotomies, accurate reduction of the displaced segment, and stable internal fixation with the appropriate hardware. The esthetic and functional predictable outcome is best achieved when the correction is performed within a few months of the initial trauma. With time delay, the bony remodeling of the malunited fracture occurs and therefore osteotomies different from the original fracture line will need to be placed. This is especially likely in fractures causing malocclusion of either the upper or lower jaws.<sup>1</sup> Anatomically abnormal bone is replaced with bone grafts.

In our cases, desired Class 1 occlusion and the improved aesthetic outcome were achieved when reosteotomising cuts were placed at the initial fractured site if the trauma was operated on within 8-10 weeks of time. Orthognathic osteotomies such as Le-fort 1 for maxillae and vertical ramus osteotomy for mandible were performed for long-standing malocclusion cases where the time elapsed was more than 10 weeks post-trauma.

In the established post-traumatic deformity, soft tissue distortion from contracted underlying scar tissue and adherence to bony depressions and defects is the limiting

factor in restoring the pre-injury appearance.<sup>5</sup>

Deformities secondary to bone loss are seen in fractures with severe comminution due to the resorption of poorly vascularized fragments or significantly displaced fractures with inadequate fixation of the fragments. The reliable method of treatment is to replace the bony gaps with similar bone tissue such as either from the calvarium or from the iliac crest. The bone grafts are held in place by spanning plates which have to be of the load-bearing type to provide rigid fixation during the period of its healing.<sup>6,7</sup>

The latest technological advancement is the patient-specific implant, created from 3D CT scan<sup>5,8</sup> reconstruction and steariolithic models, and requires no further moulding or manipulation. This is of great use for complex defects involving multiple skeletal areas.<sup>9–11</sup>

Correction of post-traumatic secondary deformities pertaining to specific subsites within the craniofacial skeleton such as frontal when there is a contour deficiency augmentation with titanium mesh or bone graft such as iliac bone split calvarial and split rib bone or alloplasts such as PEEK and medpor works sufficiently.<sup>10</sup> For bony frontal protuberances, reduction contouring is necessary. Obliteration of the frontal sinus is reserved for those cases with recurrent frontal sinusitis or mucocoele.<sup>4,10,12</sup>

In Naso-orbito-ethmoid deformities, correction of telecanthus depends on the medial canthal disattachment or attachment to the bigger or smaller bony fragment.<sup>13</sup> Transnasal cathopexy after the fixation of detached medial canthal tendon to the bone is performed. In late cases with significant displacement of the NOE, osteotomy with medial repositioning of the medial canthal-bearing segment is essential to correct it. Augmentation of the nasal dorsum with bone graft or implant also serves to camouflage the appearance of telecanthus. Nasal deviation can lead to airway obstruction and will require lateral nasal osteotomies sometimes with septoplasty if the septum is also deviated along with the rhinoplasty.<sup>1,10,14,15</sup> In one of our cases saddle nose deformity was secondarily corrected by harvesting auricular cartilage and the results were agreeable.

In orbito-zygomatic deformities with mild malar deficiency, augmentation or reduction procedures to contour or adjunctive soft tissue suspension which camouflages the asymmetry is followed. However severe deformity, will require refracturing, repositioning of the displaced bony segments and bone grafting to restore lost bony structure.<sup>16</sup>

Autogenous grafts or alloplasts such as porous polyethylene or titanium mesh are used for orbital reconstruction otherwise it causes enophthalmos when there is herniation of orbital fat, entrapment of periorbital or extraocular muscles, and fibrosis of soft tissues.<sup>12,17</sup>

Management consideration usually followed to treat secondary deformities in mandible with occlusal discrepancy are extra-oral approach option which allows good visualisation, followed by the debridement for

removal of any fibrous tissue, necrotic bone or failed hardware.<sup>18</sup>

Mandibular osteotomies to refracture for proper establishment of anatomy and occlusion followed by maxillo-mandibular fixation. A new rigid fixation is performed, occlusion is verified after the release of maxillo-mandibular fixation. Minor occlusal discrepancies may be treated with orthodontics, prosthetic rehabilitation, reconstruction, and occlusal adjustments if indicated.<sup>18,19</sup>

TMJ reconstruction may be indicated when the remaining ramus is short with multiple fragments and large movements are required to correct occlusion.<sup>20</sup> Orthognathic surgery may be indicated in long-standing malocclusions. Functional therapy can be done for up to 3 months for the management of malocclusion.<sup>21–23</sup>

Maxillary deformities following LeFort fractures most commonly demonstrate midface retrusion, decreased midfacial height, anterior open bite, and mandibular overclosure secondary to posterior displacement of the maxilla, anterior cephalad telescoping, and the inferior pull of the pterygoid musculature on the fractured pterygoid plates. LeFort I osteotomy and repositioning, regardless of the original midfacial fracture pattern, is generally the easiest solution to correct a malocclusion.<sup>4,10,18,24</sup>

## 6. Conclusions

The treatment for post-traumatic secondary deformities by open reduction with internal fixation yields sufficient aesthetic and functional outcomes when there is no loss of hard or soft tissue. Re-osteotomising at the fractured site for trauma within 8-10 weeks and re-osteotomizing at a different location or orthognathic osteotomies for chronic malocclusion and malunion cases.

## 7. Source of Funding

This research did not receive any specific grant from funding agencies in the public, commercial, or not-for-profit sectors.

## 8. Conflict of interest

We declare that we do not have any commercial or associative interest that represents a conflict of interest in connection with the work submitted.

## 9. Informed Consent

Informed consent was taken from all the individuals.

## References

1. Mokal NJ, Desai MF. Secondary correction of post-traumatic craniofacial deformities. *J Craniofac Surg*. 2014;25(5):1658–64.
2. Ranganath K, Kumar HH. *J Maxillofac Oral Surg*. 2011;10(1):20–4. doi:10.1007/s12663-010-0088-6.
3. Khorasani M, Janbaz P, Rayati F. Maxillofacial reconstruction with Medpor porous polyethylene implant: a case series study.




- J Korean Assoc Oral Maxillofac Surg.* 2018;44(3):128–35. doi:10.5125/jkaoms.2018.44.3.128.
4. Eski M, Sengezer M, Turegun M, Deveci M, Isik S. Contour restoration of the secondary deformities of zygomaticoorbital fractures with porous polyethylene implant. *J Craniofacial Surg.* 2007;18(3):520–5.
  5. Gruss JS. Craniofacial osteotomies and rigid fixation in the correction of post-traumatic craniofacial deformities. *Scand J Plast Reconstr Surg Hand Surg Suppl.* 1995;27:83–95.
  6. Mokal NJ, Desai MF. Secondary correction of post-traumatic craniofacial deformities. *Journal of Craniofacial Surgery.* 2014;25(5):1658–64.
  7. Imola MJ, Ducic Y, Adelson RT. The secondary correction of post-traumatic craniofacial deformities. *Otolaryngol Head Neck Surg.* 2008;139(5):654–60. doi:10.1016/j.otohns.2008.07.031.
  8. Bell RB, Markiewicz MR. Computer-assisted planning, stereolithographic modeling, and intraoperative navigation for complex orbital reconstruction: a descriptive study in a preliminary cohort. *J Oral Maxillofac Surg.* 2009;67(12):2559–70. doi:10.1016/j.joms.2009.07.098.
  9. Rudman K, Hoekzema C, Rhee J. Computer-assisted innovations in craniofacial surgery. *Facial Plastic Surgery.* 2011;27(04):358–65.
  10. Khader R, Wallender A, Van Sickels J, Cunningham LL. Secondary reconstruction of panfacial fractures. *Oral Maxillofac Surg.* 2014;18(1):99–109. doi:10.1007/s10006-013-0403-8.
  11. Bell RB, Markiewicz MR. Computer-assisted planning, stereolithographic modeling, and intraoperative navigation for complex orbital reconstruction: a descriptive study in a preliminary cohort. *J Oral Maxillofac Surg.* 2009;67(12):2559–70. doi:10.1016/j.joms.2009.07.098.
  12. Yavuzer R, Sari A, Kelly CP, Tuncer S, Latifoglu O, Celebi MC, et al. Management of frontal sinus fractures. *Plast Reconstr Surg.* 2005;115(6):79–93. doi:10.1097/01.prs.0000161988.06847.6a.
  13. Mathog RH, Archer KF, Nesi FA. Posttraumatic enophthalmos and diplopia. *Otolaryngol Head Neck Surg.* 1986;94(1):69–77. doi:10.1177/019459988609400112.
  14. Herford AS. Secondary Treatment of Naso-orbital Ethmoid Injuries. *Facial Plast Surg.* 2017;33(6):591–7.
  15. Potter JK, Muzaffar AR, Ellis E, Rohrich RJ, Hackney FL. Aesthetic management of the nasal component of naso-orbital ethmoid fractures. *Plast Reconstr Surg.* 2006;117(1):10–8. doi:10.1097/01.prs.0000195081.39771.57.
  16. Perino KE, Zide MF, Kinnebrew MC. Late treatment of malunited malar fractures. *J Oral Maxillofac Surg.* 1984;42(1):20–34. doi:10.1016/0278-2391(84)90391-4.
  17. Bussieres M, Tatum SA. Secondary craniofacial surgery for trauma. *Facial Plast Surg.* 2000;16(2):135–52. doi:10.1055/s-2000-12575.
  18. Patel AK, Rajanna R, Kumar R, Vidhya N, Khazilane A. Secondary Corrections Of Residual Deformities Of Mandible: A Retrospective Clinical Study. *Res J Pharm Biol Chem Sci.* 2018;9(5):856–62.
  19. Laine P, Kontio R, Salo A, Mesimäki K, Lindqvist C, Suuronen R, et al. Secondary correction of malocclusion after treatment of maxillofacial trauma. *J Oral Maxillofac Surg.* 2004;62(10):1312–20. doi:10.1016/j.joms.2004.02.014.
  20. Nilesh K, Vande A. Post-traumatic deformity of mandibular condyle: descriptive review and proposal of treatment algorithm. *J Stoma.* 2020;73(1):36–43. doi:10.5114/jos.2020.94176.
  21. Vega LG. Reoperative mandibular trauma: management of posttraumatic mandibular deformities. *Oral Maxillofac Surg Clin North Am.* 2011;23(1):47–61. doi:10.1016/j.coms.2010.12.003.
  22. Becking AG, Zijdeveld SA, Tuinzing DB. The surgical management of post-traumatic malocclusion. *Clin Plast Surg.* 2007;34(3):37–43. doi:10.1016/j.cps.2007.04.007.
  23. De Souza M, Oeltjen JC, Panthaki ZJ, Thaller SR. Posttraumatic mandibular deformities. *J Craniofac Surg.* 2007;18(4):912–6. doi:10.1097/scs.0b013e3180684377.
  24. Steidler NE, Cook RM, Reade PC. Residual complications in patients with major middle third facial fractures. *Int J Oral Surg.* 1980;9(4):259–66. doi:10.1016/s0300-9785(80)80032-9.


### Author biography

**Abinandan Patel**, Professor and HOD

**Girish G**, Assistant Professor

**Ghana Shree S**, Fellow  <https://orcid.org/0000-0002-8482-4706>

**Preethi Bhat**, Consultant  <https://orcid.org/0000-0002-5427-1194>

**Nikita Shabadi**, Fellow  <https://orcid.org/0000-0001-7799-7476>

**Cite this article:** Patel A, Girish G, Ghana Shree S, Bhat P, Shabadi N. Secondary correction of the post-traumatic deformity: A clinical study. *IP Int J Maxillofac Imaging* 2023;9(3):156–162.