

Content available at: <https://www.ipinnovative.com/open-access-journals>

IP International Journal of Maxillofacial Imaging

Journal homepage: <https://www.ijmi.in/>

## Case Report

# Immediate implants” an elegance in anterior maxilla: Case report

V. Shakuntala Soujanya<sup>1\*</sup>, P Prabhakar Rao<sup>1</sup>, M Vinuthna<sup>2</sup>, Dilip<sup>2</sup>,  
N Abhishek Reddy<sup>3</sup>, K. Kranthi<sup>4</sup>

<sup>1</sup>Dept. of Oral Medicine and Radiology, Sun Dental Care Hospital, Malkajgiri, Hyderabad, India

<sup>2</sup>Dept. of Conservative Dentistry and Endodontics, Government Medical College, Nizamabad, Telangana, India

<sup>3</sup>Dept. of Oral and Maxillofacial Surgery, Meghna Institute of Dental Sciences, Nizamabad, Telangana, India

<sup>4</sup>Dept. of Periodontics, Meghna Institute of Dental Sciences Nizamabad Telangana/estd 2005/Best Dental College In Telangana, Nizamabad, Telangana, India



## ARTICLE INFO

### Article history:

Received 07-11-2023

Accepted 11-12-2023

Available online 01-01-2024

### Keywords:

Immediate implants  
Extraction  
Osseointegration  
esthetics  
Primary stability  
Anterior teeth

## ABSTRACT

Esthetics and psychological distress are the propounding factors which comes into effect when somebody loses the anterior teeth. The compensation of it is of long-drawn-out and demands for an immediate regimen. In these circumstances, it's the immediate implants placement which offers a simple choice for replacing the lost tooth immediately and hence it is currently considered as a golden treatment modality for replacing a missing tooth. The added benefits of it are less time consuming, involves few steps of surgical procedures and minimal bone resorption as it helps in preserving the vitality of bone receptors immediately after extraction thereby helps in gaining high rates of success of dental implants placed. Here in this article, we are reporting a successful case of immediate implant placed at maxillary anterior canine region which rendered a complete satisfaction to the patient and as well as professionally.

This is an Open Access (OA) journal, and articles are distributed under the terms of the [Creative Commons Attribution-NonCommercial-ShareAlike 4.0 License](https://creativecommons.org/licenses/by-nc-sa/4.0/), which allows others to remix, tweak, and build upon the work non-commercially, as long as appropriate credit is given and the new creations are licensed under the identical terms.

For reprints contact: [reprint@ipinnovative.com](mailto:reprint@ipinnovative.com)

## 1. Introduction

“Immediate implants” is one of the recent advancements in the field of implant dentistry and it becomes snappier as it replaces the lost tooth immediately after the extraction making early loading a possibility. Its peculiarity lies in that it not only reduces the over-all treatment time but also includes fewer surgical interventions, prevents extensive soft and hard tissue loss and provides psychological satisfaction to the patient.<sup>1</sup> As we all know that “osteointegration” and “intensity of bone loss” are the two key factors which play a crucial role for the success of any dental implant. Owing to “Immediate implants” it achieves the above two key factors successfully as it keeps the

extraction socket away from the contamination favoring osteointegration and preserves bony receptors by preventing extensive bone resorption.<sup>2</sup> Thus, Immediate implantation proved that it not only reduces the over-all treatment time but also prevents the loss of gummy tissues and helps in gaining esthetic success. Not an exception to this is the maxillary anterior teeth and here we report a successful case of immediate implant placed at maxillary canine region.

## 2. Case Report

A 29yrs young male patient reported to the dental clinic with the chief complaint of missing tooth at upper left front teeth region for 3 months and gives a history of tooth extraction done due to a broken tooth over there. On Intra-oral examination, an edentulous region i.r.t. missing 23 was noted which further on radiographic examination with IOPA

\* Corresponding author.

E-mail address: [shakuntalasoujanya@gmail.com](mailto:shakuntalasoujanya@gmail.com) (V. Shakuntala Soujanya).

and OPG has revealed a retained root of canine measuring around 14mm approximately. Then the patient was well explained about all the available treatment options that can be done to him and about the possible drawbacks of each. He was very much concerned about his esthetics and wants to get his tooth replaced to the earliest possibility without disturbing the adjacent teeth and hence opted for immediate implants. Later, further analysis for implant placement was done using care stream dental CT scan. Finally, after a thorough radiographic examination and evaluation considering approximating landmarks, vital structures and bone density an ostium dental implant (TSIV SA fixture) measuring 4.0x11.5mm was selected and inserted into the socket immediately after the extraction. For this initially, atraumatic extraction was done under the administration of 2% lignocaine local anesthetic solution where the patient was premedicated with 2 g amoxicillin, 1h before surgery. While placing the implant all the aseptic procedures were followed which includes debridement of extraction socket, osteotomy of the site using sequential drills and insertion of dental implant where a torque of 40Ncm was attained enough for the primary stability. Then the postoperative evaluation was done using intraoral periapical radiograph to confirm the accuracy of implant placed followed by placing the cover screw and suturing. The patient was recalled after 1½ month to place the gingival former and then after 2 weeks where final abutment was placed and impressions were taken.

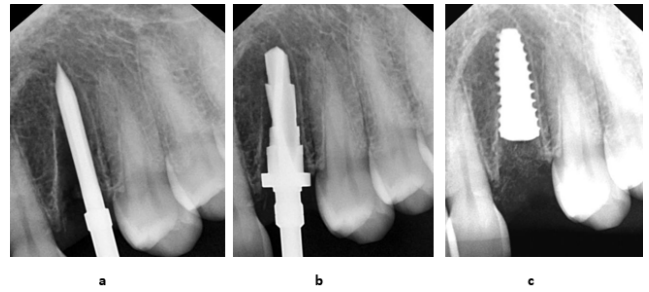


Figure 3: a,b,c: Immediate implant placement

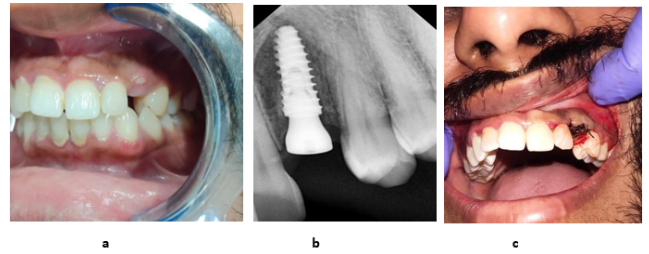


Figure 4: a,b,c Placement of gingival former

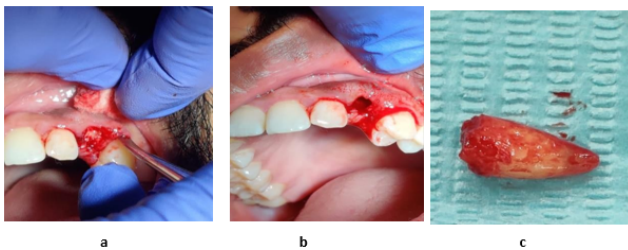


Figure 1: a,b,c; Atraumatic

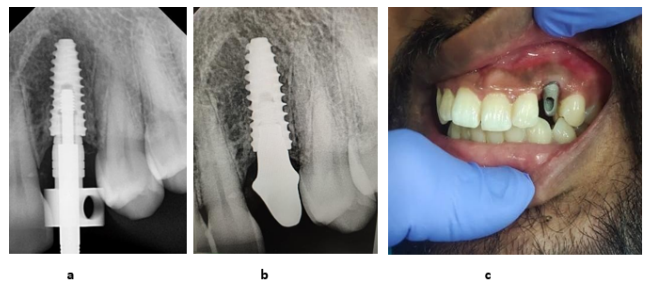


Figure 5: Placement of customized abutment prepared

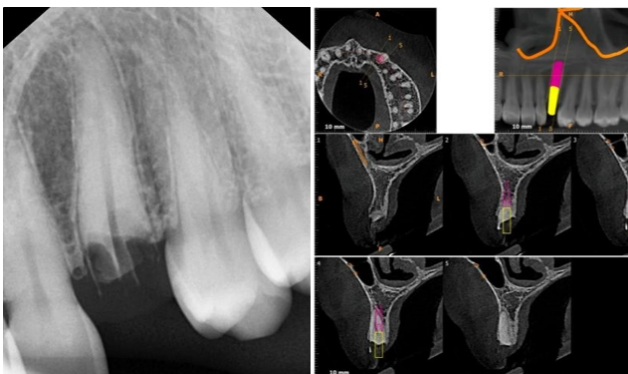


Figure 2: Radiographic

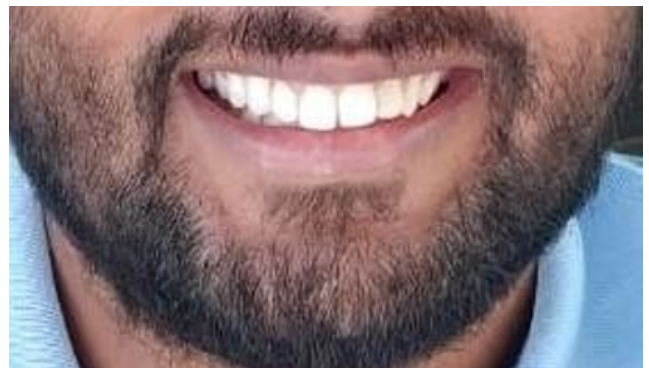

Figure 6: Zirconia crown placed

The impression was made with closed tray technique using light body and putty polyvinyl siloxane rubber base material. Finally, esthetically satisfied Zirconia crown was

fabricated and cemented to the abutment that satisfied the patient. (Figures 1, 2, 3, 4, 5 and 6)

### 3. Discussion

The “Per-Ingvar Branemark”, a Swedish physician and research professor, acknowledged as the “Father of Modern Dental Implantology” defined osseointegration in 1952 as a “Direct structural and functional connection between the ordered, living bone and the surface of load carrying implants”. It means a direct connection between implant surface and live bone cells.<sup>3</sup> Actually, it refers to a phenomenon where an implant become so fused with bone that once the implant surface gets Osseo integrated with the bone there is no longer progressive relative movement between it and the bone with which it has direct contact. Thus, osseointegration plays a crucial role in achieving implant stability and aids in the success of the implant placed.<sup>4</sup>

Ideally, the actual time taken for the successful osseointegration of dental implants varies from 6 to 8 months where it is 6 months for the upper jaw and 3 months for the lower jaw. Hence, till 1990s implants were placed in completely healed bone tissue after the extraction.<sup>5</sup> However, today this approach has been replaced by the revolutionary concept of immediate implants with the availability of newer implants. These newer implants are thus externally modified in its shape and surface to get high rates of successful osseointegration.<sup>6</sup>

Even though the available literature and case studies conducted confirms 90-100% of the success rates with the immediate implants placed.<sup>7</sup> It's the osseointegration, intensity of bone and primary stability of the implant at the extraction socket which has a priority in the success of dental implants. Immediate implants placement thus ensures in achieving these factors indeed as the implant is placed into the fresh socket immediately after the extraction preserving the vitality of osteogenic receptors over there.<sup>8</sup> It is further best accomplished by grafting the extraction socket with graft materials that can be used with or without plasma-rich materials like Plasma Rich Fibrin (PRF) capable of osteogenic regeneration.

#### 3.1. Advantages

1. Shortens number of surgeries and over-all treatment time.
  1. 2. Preserves the integrity of bone and soft tissues at the extraction socket thereby gains esthetic success.
  2. 3. Increased patient satisfaction.<sup>9-11</sup>

#### 3.2. Disadvantages

1. Associated with high risk of implant failure.
  2. Difficulty in achieving primary stability while placing implant.

3. Difficulty in predicting hard and soft tissue levels.
4. More often requires bone graft.<sup>12,13</sup>

The lead factor for the success of any treatment modality depends on proper case selection. The pre-requisite ideal clinical conditions required for immediate implant placement includes gingival type, facial bone wall, level of smile line, hard and soft tissue levels. These factors should be properly evaluated before implant placement.<sup>14</sup> The implant placement in a socket with intact facial bone and thick gingiva is associated with low risk of gingival recession. If an implant is placed within a thin biotype, there is a higher risk of thread explosion due to the higher frequency of gingival recession occurring at the neck of the implant prosthesis. Hence, these sites with thin tissue biotype are unrecommended areas for immediate placement.<sup>15,16</sup>

#### 3.3. Indications

1. Systemically healthy patients.
2. Atraumatic extractions<sup>17</sup>
3. Extraction socket with intact periodontium and sufficient labial bone without acute infection.<sup>18</sup>

#### 3.4. Contraindications

1. Acute or purulent infection at extraction socket.
2. In case of chronic infections and peri-apical lesions, immediate implant placement is not contra-indicated as long as the infection is removed totally and primary stability is achieved<sup>19</sup>
3. Uncontrolled diabetes<sup>20</sup>
4. Uncontrolled hypertension<sup>21</sup>
5. Uncontrolled periodontitis: The health of the periodontium and its dimensions effects the esthetic outcome of a dental implant placed. If there is sufficient amount of apical and palatal bone at the site of the extraction enough for the 3D positioning of the dental implant and then to get primary stability then periodontitis is not a contra-indication for placing immediate implant.<sup>22,23</sup>
6. Under bisphosphanates therapy<sup>24</sup>

Osseointegration is a complex phenomenon which includes a dynamic interaction between the implant body and the tissue interface. It's a phenomenon where an initial interlock between the alveolar bone and the implant body gets later turned up into a biological fixation through a continuous process of bone apposition and remodeling.<sup>25,26</sup> In the immediate implants, we have a customized socket for implant placement thereby helps in attaining excellent initial balance and high success rates as reported by Krump and Barnett.<sup>27</sup> In the review of literature done by Elias and Sheiham, it was found that most of the patients are more of esthetic concern and willing for replacement of missing anterior tooth than a posterior tooth.<sup>28</sup>

### 3.4.1. Kois Five Diagnostic Factors for Immediate Implant Placement

1. Relative tooth position
2. Form of the periodontium
3. Biotype of the periodontium
4. Tooth shape and
5. Position of the osseous crest.

These factors play a very crucial role in preserving the integrity of periodontium. Integrity of periodontium is better achieved by minimizing the gingival recession and bone loss at the site of implant placed. For this the implant should be placed at an adequate depth into the extraction socket where the distance between implant shoulder and mid-facial alveolar crestal bone is at least 0.5 to 1mm approximately.<sup>29</sup> Furthermore, wherever it is possible it's better to opt for flapless surgery method over the open flap method as the former results in less gingival recession causing less morbidity to the patient. Apart from this at least 2mm of distance between implant shoulder and internal surface of facial bone should be maintained so as to create a sufficient space for the blood clot formation to aid in laying down of connective tissue matrix formation and new woven bone formation. This is best site for placement of bone grafts which further reduce post-surgical bone resorption.<sup>30</sup>

### 4. Source of Funding

None.

### 5. Conflict of Interest

None.

### References

1. Lazzara RM. Immediate implant placement into extraction sites: Surgical and restorative advantages. *Int J Periodont Restor Dent.* 1989;9(5):333–43.
2. Parel SM, Triplett RG. Immediate fixture placement: A treatment planning alternative. *Int J Oral Maxillofac Implants.* 1990;5(4):337–45.
3. Branemark PI. *The Osseointegration Book: From Calvarium to Calcaneus.* Quintessence, Berlin: Quintessence Publishing Co Ltd; 2005. p. 512.
4. Padmanabhan S. Osseointegration: An update. *J Indian Prosthodont Soc.* 2013;13(1):3602536.
5. Pandey C, Rokaya D, Bishwa P. Contemporary Concepts in Osseointegration of Dental Implants: A Review. *BioMed Res Int.* 2022;p. 6170452. doi:10.1155/2022/6170452.
6. Smeets R, Stadlinger B, Schwarz F, Beck-Broichsitter B, Precht JO, Kloss C, et al. Impact of Dental Implant Surface Modifications on Osseointegration. *Biomed Res Int.* 2016;p. 6285620.
7. Mahesh L, Castro B, Bhasin A. The Survival Rate of Posterior Immediate Implants in the Maxilla and Mandible: An Observational Retrospective Study of 158 Dental Implants. *Cureus.* 2023;15(9):45579.
8. Zhao R, Yang R, Cooper PR, Khurshid Z, Shavandi A, Ratnayake J, et al. Bone Grafts and Substitutes in Dentistry: A Review of Current Trends and Developments. *Molecules.* 2021;26(10):3007. doi:10.3390/molecules26103007.
9. Werbitz MJ, Goldenberg PV. The immediate implant: Bone preservation and bone regeneration. *Int J Periodont Restorative Dent.* 1992;12:207–17.
10. Lindeboom JA, Tjiook Y, Kroon FH. Immediate placement of implants in periapical infected sites: A prospective randomized study in 50 patients. *Oral Surg Oral Med Oral Pathol.* 2006;101(6):705–10.
11. Agliardi E, Panigatti S, Clerico M, Villa C, Malo P. Immediate rehabilitation of the edentulous jaws with full fixed prostheses supported by four implants: Interim results of a single cohort prospective study. *Clin Oral Imp Res.* 2010;21(5):459–65.
12. Koh RU, Rudek I, Wang HL. Immediate implant placement: Positives and negatives. *Implant Dent.* 2010;19(2):98–108.
13. Esposito M, Grusovin MG, Chew YS, Coulthard P, Worthington HV. Interventions for replacing missing teeth: 1-versus 2- stage implant placement. *Cochrane Database Syst Rev.* 2009;3:6698.
14. Koh RU, Rudek I, Wang HL. Immediate implant placement: positives and negatives. *Implant Dent.* 2010;19(2):98–108.
15. Gher ME, Quintero G, Assad D, Monaco E, Richardsson AC. Bone grafting and guided bone regeneration for immediate dental implants in humans. *J Periodontol.* 1994;65(9):881–91.
16. Boticelli D, Berglundh T, Lindhe J. Hard tissue alterations following immediate implant placement in extraction sites. *J Clin Periodontol.* 2004;31(10):820–8.
17. Giri D, Singh VP, Kundapur PP. Immediate implants in dentistry: a review. *Pak Oral Dent J.* 2013;p. 1–6.
18. Kumar AG. Criteria for immediate placement of oral implants - a mini review. *Biol Med.* 2012;4(4):188–92.
19. Koh RU, Rudek I, Wang HL. Immediate implant placement: Positives and negatives. *Imp Dent.* 2010;19(2):98–108.
20. Ayele S, Sharo N, Chrcanovic BR. Marginal bone loss around dental implants: comparison between diabetic and non-diabetic patients-a retrospective clinical study. *Clin Oral Invest.* 2023;27(6):2833–41.
21. Nikolopoulou F, Chrysostomidis A. Hypertension and Dental Implants: A Review. *Surg Med Open Acc J.* 2019;3(1):1–3.
22. Kan JY, Rungcharassaeng K, Umezaki K, Kois JC. Dimensions of peri-implant mucosa: An evaluation of maxillary anterior single implants in humans. *J Periodontol.* 2003;74(4):557–62.
23. Buser D, Chappuis V, Belser UC, Chen S. Implant placement post extraction in esthetic single tooth sites: When immediate, when early, when late? *Periodontology.* 2000;73(1):84–102.
24. Cartos VM, Zhu S, Zavras AI. Bisphosphonate use and the risk of adverse jaw outcomes: a medical claims study of 714,217 people. *J Am Dent Assoc.* 2008;139(1):23–30.
25. Zarb CA, Albrektsson T. Tissue-integrated prostheses osseointegration in clinical dentistry. Branemark P, Zarb C, editors. Chicago: Quintessence Publishing Co; 1985. p. 88–98.
26. Zarb GA, Albrektsson T. Osseointegration: a requiem for periodontal ligament? *Int J Period Restor Dent.* 1991;11:88–91.
27. Elias AC, Sheiham A. The relationship between satisfaction with mouth and number and position of teeth. *J Oral Rehabil.* 1998;26(1):649–61.
28. Chen ST, Darby I. The relationship between facial bone wall defects and dimensional alterations of the ridge following flapless tooth extraction in the anterior maxilla. *Clin Oral Imp Res.* 2017;28(8):931–7.
29. Buser D, Chappuis V, Belser UC, Chen S. Implant placement post extraction in esthetic single tooth sites: When immediate, when early, when late? *Periodontology.* 2000;73:84–102.
30. Chen ST, Darby IB, Reynolds EC. A prospective clinical study of non-submerged immediate implants: Clinical outcomes and esthetic results. *Clinical Oral Implants Research.* 2007;18:552–62.

### Author biography

V. Shakuntala Soujanya, Director

P Prabhakar Rao, Director

**M Vinuthna**, Assistant Professor

**Dilip**, Oral and Maxillofacial Surgeon

**N Abhishek Reddy**, Reader

**K. Kranthi**, Reader

**Cite this article:** Shakuntala Soujanya V, Prabhakar Rao P, Vinuthna M, Dilip, Abhishek Reddy N, Kranthi K. Immediate implants” an elegance in anterior maxilla: Case report. *IP Int J Maxillofac Imaging* 2023;9(4):189-193.