

Content available at: <https://www.ipinnovative.com/open-access-journals>

IP International Journal of Maxillofacial Imaging

Journal homepage: <https://www.ijmi.in/>

Original Research Article

Location of mandibular foramen in dry mandibles in relation to various anatomical landmarks

Sowjanya Bandlamudi¹, Pavithra M², Manickam Subramanian^{3*}, Arathi Senthappan Mariappan⁴, Janani Yoganandham⁵¹Dept. of Anatomy, Shri Sathya Sai Medical College and Research Institute, Sri Balaji Vidyapeeth, Nellikkuppam, Tamil Nadu, India²Chettinad Dental College and Research Institute, Kelambakkam, Tamil Nadu, India³Dept. of Anatomy, Karpaga Vinayaga Institute of Medical Sciences & Research Centre, Maduranthakam, Tamil Nadu, India⁴Dept. of Anatomy, Chettinad Hospital and Research Institute, Chettinad Academy of Research and Education, Kelambakkam, Tamil Nadu, India⁵Dept. of Anatomy, Bharath Institute of Higher Education and Research, Chennai, Tamil Nadu, India

ARTICLE INFO

Article history:

Received 04-01-2024

Accepted 23-02-2024

Available online 14-05-2024

Keywords:

Mandibular foramen

Inferior alveolar nerve block

Gonial angle

Morphometry

Accessory mandibular foramen

ABSTRACT

Background: To localize the mandibular foramen in dry mandibles of adult and old age groups of South Indian origin by estimating its average distance from different anatomical landmarks and to provide a specific and precise site for inferior alveolar nerve block.**Materials and Methods:** A total of 51 mandibles were taken for the study and the distance between the mandibular foramen and the various anatomical landmarks were measured using a digital vernier caliper. Presence of accessory mandibular foramen was observed and recorded. Difference between the sides and the correlation between the gonial angle and various distances were carried out.**Results:** Distance of mandibular foramen from anterior border was 16.41 ± 2.44 mm and 16.85 ± 2.55 mm, from posterior border was 10.28 ± 2.08 mm and 10.13 ± 2.02 mm, from mandibular incisure 22.5 ± 3.13 mm and 21.9 ± 3.08 mm, from mandibular base 23.72 ± 3.37 mm and 24.5 ± 3.27 mm, from third molar 15.27 ± 11.99 mm and 16.85 ± 11.60 mm, from apex of retro molar trigone 18.28 ± 3.02 mm and 19.79 ± 3.18 mm on right and left side respectively. There was no significant difference between the measurements of right and left sides. The measurements had a negative association with gonial angle. Accessory foramina were found to be present in 21 and 23 mandibles on right and left side respectively.**Conclusion:** Precise localization of mandibular foramen is clinically very important to achieve effective inferior alveolar nerve block prior to dental surgeries in the lower jaw. The present study establishes the presence of bilateral symmetry in the position of mandibular foramen with respect to various anatomical landmarks and the utility of gonial angle in localizing the mandibular foramen.This is an Open Access (OA) journal, and articles are distributed under the terms of the [Creative Commons Attribution-NonCommercial-ShareAlike 4.0 License](https://creativecommons.org/licenses/by-nc-sa/4.0/), which allows others to remix, tweak, and build upon the work non-commercially, as long as appropriate credit is given and the new creations are licensed under the identical terms.For reprints contact: reprint@ipinnovative.com

1. Introduction

Mandibular foramen is located on the medial surface of the ramus of the mandible. Inferior alveolar vessels and nerve pass through this foramen. Inferior alveolar nerve

is a branch from posterior division of mandibular nerve, which gives off nerve to mylohyoid just before it enters the mandibular canal through the mandibular foramen. It forms a plexus called inferior alveolar plexus and supplies to all the lower teeth and comes out as mental nerve through mental foramen.¹ For any procedure on the lower teeth, the commonly used local anaesthetic technique is

* Corresponding author.

E-mail address: gandhiayu@hotmail.com (M. Subramanian).

inferior alveolar nerve block.² Precise localization of the mandibular foramen is necessary for insertion of anaesthetic needle during nerve block. Identifying the exact location of mandibular foramen with respect to different anatomic landmarks determines the success rate of the block.

The position of the foramen was found to be variable. However, it is predominantly located at the midpoint between the anterior and posterior borders of the ramus present halfway between the mandibular notch and the lower border of the mandible or two thirds of the line joining the coronoid process to the angle of the mandible.³

Many techniques of inferior alveolar nerve block have been described. Inferior alveolar nerve block failure is common and it occurs even with experienced hands. Failure with this procedure could be as high as 45per cent.⁴⁻⁶ Correct anatomical location plays an important role in successful inferior alveolar nerve block. The mandibular foramen is often selected as a reference point with the base of the mandible to establish racial difference.^{7,8}

Accessory mandibular foramen is any opening in the mandible other than the mandibular foramen, mental foramen, lingual foramen, and sockets of teeth.⁹ The presence of accessory foramina and additional branches of inferior alveolar nerve may lead to increased rates of failure as all the branches may not be anaesthetized.¹⁰

The aim of the present study is to locate the mandibular foramen with respect to different anatomic landmarks for accurate inferior alveolar nerve block and to find the presence of accessory foramina.

2. Materials and Methods

A total number of 51 dry adult human mandibles consisting of 102 mandibular foramina of unknown sex and age were studied from the collection available in the Department of Anatomy. Abnormal and damaged mandibles were excluded from the study. A Digital vernier calliper of 0.01mm accuracy was used for taking the measurement. Irrespective of shape of lingula, the centre of mandibular foramen was taken as the reference point. The distances between various anatomic landmarks mentioned below and the mandibular foramen (Figure 1) were measured by two independent observers and the mean value of those two observations were taken up for the study.

1. Anterior border of ramus of mandible
2. Posterior border of ramus of mandible
3. Mandibular incisure
4. Mandibular base
5. Distance from middle of socket of III molar in edentulous and middle of occlusal surface of third molar in dentulous mandible
6. Apex of retromolar trigone

Width of the mandibular foramen was also measured. The location of the mandibular foramen in relation

to the occlusal plane of the molar teeth was also observed. The angle of the mandible was measured with a goniometer. Further observation regarding the presence of accessory mandibular foramen was done. Observations were tabulated.

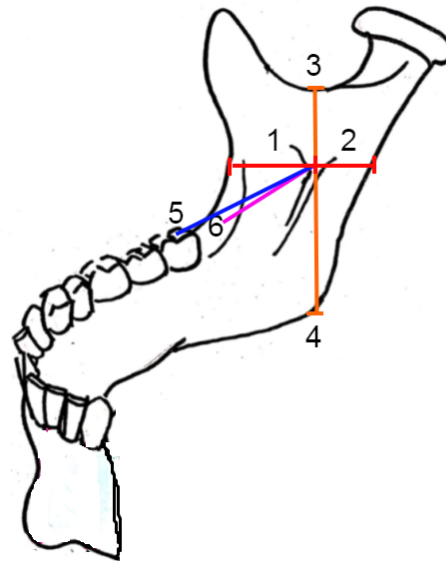


Figure 1: Diagram showing the various measurements made from mandibular foramen 1: Mandibular foramen to anterior border of ramus, 2: Mandibular foramen to posterior border of ramus, 3: Mandibular foramen to mandibular incisure, 4: Mandibular foramen to base of mandible, 5: Mandibular foramen to middle of occlusal surface of 3rd molar tooth, 6: Mandibular foramen to Apex of retromolar trigone.

Statistical analysis: All the measurements were expressed as mean \pm standard deviation (S.D.) along with their range. The difference between the right and left side measurements were analysed using paired t test. The correlation between the gonial angle and other distances was analysed by the Pearson linear correlation test using SPSS Version 17.0 for Windows (SPSS Inc, Chicago, IL). The level of significance adopted was 95%, or $p < 0.05$.

3. Results

A total of 51 mandibles were assessed of which 16 were dentulous and 35 were edentulous.

The distance between mandibular foramen and various landmarks and other measurements are summarized in Table 1.

Gonial angles are almost similar on the right and left sides respectively. Width of the mandibular foramen was $4.56 \pm 0.74\text{mm}$ and $4.43 \pm 0.93\text{mm}$ on right and left side respectively. There was no significance difference in these measurements between right and left side except

Table 1: Distance between mandibular foramen and different anatomic landmarks and other measurements

Measurement	Side	Mean ± S.D. (mm)	Range (mm)	95% Confidence Interval		t	Significance (2-tailed)
				Lower	Upper		
AB-MF	R	16.41 ± 2.44	12.39 - 22.65	-0.99	0.12	-1.59	0.12
	L	16.85 ± 2.55	12.59 - 23.58				
MF-PB	R	10.29 ± 2.08	7 - 17.61	-0.39	0.69	0.54	0.59
	L	10.14 ± 2.02	6.22 - 14.83				
MI-MF	R	22.58 ± 3.14	16.25 - 30.22	-0.22	1.49	1.48	0.15
	L	21.94 ± 3.09	16.08 - 31.14				
MF-MB	R	23.72 ± 3.38	15.93 - 30.15	-1.82	0.25	-1.53	0.13
	L	24.51 ± 3.27	17.49 - 31.33				
3 rd Molar-MF	R	22.99 ± 3.86	14.21 - 35.92	-1.44	0.25	-1.41	0.16
	L	23.59 ± 3.59	14.93 - 35.41				
Apex of RMT-MF	R	18.29 ± 3.03	11.44 - 24.94	-2.13	-0.89	-4.87	0.00*
	L	19.79 ± 3.18	13.18 - 28.82				
AB-PB	R	29.98 ± 3.20	23.47 - 39.46	-0.29	0.75	0.89	0.38
	L	29.75 ± 3.46	22.33 - 38.41				
F Width	R	4.56 ± 0.74	2.57 - 6.37	-0.08	0.34	1.25	0.22
	L	4.43 ± 0.93	1.31 - 6.78				
Go (in degree)	R	122.67 ± 5.18	114 - 132	-3.01	0.15	-1.82	0.07
	L	124.10 ± 5.99	108 - 137				

R: Right side; L: Left side; Ab: Anterior border of ramus; Pb: Posterior border of ramus; MI: Mandibular incisure; MB: Mandibular base; RMT: retromolar trigone, Go: Gonial angle; MF: Mandibular foramen; F: Foramen; * Correlation is significant at the 0.05 level

Table 2: Correlation between Gonial angle and different measurements on the right and left sides

Parameters	Right side		Left side	
	Pearson Correlation	Significance (2-tailed)	Pearson Correlation	Significance (2-tailed)
AB-MF	-0.27	0.05	-0.32*	0.02
MF-PB	-0.44**	0.001	-0.52**	0.001
MI-MF	-0.04	0.77	-0.07	0.65
MF-MB	-0.347*	0.01	-0.49	0.001
3 rd Molar-MF	-0.01	0.97	-0.12*	0.42
Apex of RMT-MF	-0.22	0.11	-0.17**	0.24
AB-PB	-0.47**	0.001	-0.63	0.001
F Width	-0.08	0.58	-0.27	0.06

R: Right side; L: Left side; Ab: Anterior border of ramus; Pb: Posterior border of ramus; MI: Mandibular incisure; MB: Mandibular base; RMT: retromolar trigone; MF: Mandibular foramen; F: Foramen; ** Correlation is significant at the 0.01 level; * Correlation is significant at the 0.05 level

the distance between mandibular foramen and apex of retromolar trigone.

The association between gonial angle and various measurements are tabulated in Table 2. Gonial angle was found to have a negative correlation with all the measurements bilaterally. Of these, the negative correlation between gonial angle and the distance between posterior border and mandibular foramen (both sides), distance between apex of retromolar trigone and mandibular foramen (left side) and antero-posterior distance of the ramus (right side) were highly significant. Whereas, significant negative correlation was observed between gonial angle and distance between anterior border of ramus and mandibular foramen, distance between mandibular base and mandibular foramen, distance between 3rd molar and mandibular foramen. This indicates that as the gonial angle increases, the distance between mandibular foramen and various

anatomical landmarks decreases. and vice-versa.

Accessory foramina were found bilaterally in 14 mandibles (27.4%) and only on the right side in 7 mandibles (13.7%) and only on left side in 9 mandibles (17.6%).

In relation to the occlusal plane of molar teeth, the location of mandibular foramen was above in 11 mandibles, at the same level in 17 mandibles and below in 23 mandibles on the right side. Whereas, on the left side 13 were above, 17 were at the same level and 21 were below the level of the occlusal plane. This indicates that in the present study, the location of mandibular foramen was predominantly below the level of the occlusal plane of molar teeth.

4. Discussion

Locating the mandibular foramen for inferior alveolar nerve block is of great importance for many procedures in dentistry. Accurate location enables a more effective

Table 3: Comparison of distances between mandibular foramen and various landmarks with other studies

Author, year	Year	Side	AB-MF (mm)	MF-PB (mm)	MI-MF (mm)	MF-MB (mm)	3 rd Molar-MF (mm)	Apex of RMT-MF (mm)	AB-PB (mm)	F Width (mm)
Nicholson ML. ³	1985	R L	16.0±2.1 16.8±2.2	14.9±2.1 14.6±1.9	23.6±3.5 23.3±3.5	23.9±3.7 23.3±3.3	19.6±3.8 19.3±3.6	-	29.8±3.2 29.8±3.0	-
Kilarkaje N et al. ¹¹	2005	R L	18.5±1.9 18.5±2.0	-	21.6±3.1 21.6±3.4		-	-	-	-
Ennes JP & Medeiros RM. ¹²	2009	R L	14.6±2.9 14.6±3.2	12.1±2.3 12.3±2.3	24.3±3.3 24.4±3.6	22.3±4.8 22.4±5.1	-	-	29.2±3.9 29.4±4.0	-
Prado FB et al. ¹³	2010	R L	19.2±3.6 18.8±3.8	14.2±8.4 13.0±2.6	23.6±3.1 23.1±3.0		-	-	-	-
Thangavelu K et al. ¹⁴	2012	R L	18.9±2.1 18.8±2.3	14.3±1.8 14.3±1.7		27.6±4.2 27.3±4.1	-	-	-	-
Shenoy V et al. ¹⁵	2012	R L	16.1±2.0 16.3±1.8	11.6±2.1 11.3±1.9	23.5±3.1 23.5±3.1	23.5±2.8 22.8±2.7	-	-	30.7±2.7 30.7±2.7	-
Samanta PP & Karb P. ¹⁰	2013	R L	15.7±2.9 16.2±2.8	13.2±1.7 12.7±2.0	22.7±3.0 22.2±2.9	-	-	-	-	-
Padmavathi G et al. ¹⁶	2014	R L	16.8±2.8 16.9±2.5	11.7±2.0 12.1±2.4	22.0±3.0 22.3±3.4	-	-	-	-	-
Sultana Q et al. ¹⁷	2015	R L	17.6±2.7 17.9±2.7	11.3±2.0 11.4±1.9	22.9±3.5 22.3±3.1	-	17.9 17.6	-	-	-
Gopalakrishna K et al. ¹⁸	2016	R L	14.6±3.1 15.3±3.1	12.3±3.1 13.5±3.9	21.2±4.5 21.1±3.1		14.3±3.1 14.2±2.5	-	-	-
Shalini R et al. ¹⁹	2016	R L	17.1±2.7 17.4±3.0	10.4±2.1 9.6±2.0	21.7±2.7 21.9±3.3	22.3±3.3 25.3±4.5	22.8±3.9 23.2±4.2	12.2±2.1 12.1±2.3	31.7±3.8 31.4±3.9	4.1±1.5 4.3±1.6
Rajkumari K et al. ²⁰	2017	R L	16.7±1.9 16.9±1.9	11.0±1.2 11.2±1.4	22.9±3.8 23.1±3.6	24.9±3.2 24.6±3.2	-	-	-	-
Sahu R et al. ²¹	2017	R L	17.2±1.8 17.0±2.6	16.1±1.7 16.0±2.3	20.8±3.4 21.3±3.6	-	-	-	-	-
Sandhya K et al. ²²	2019	R L	16.0±3.5 16.2±3.9	10.2±2.3 10.2±5.2	20.4±3.8 20.1±3.8	24.1±4.9 24.8±4.0	-	-	-	-
Present Study	2019	R L	16.4±2.4 16.8±2.5	10.2±2.0 10.1±2.0	22.5±3.1 21.9±3.0	23.7±3.3 24.5±3.2	22.9±3.8 23.5±3.5	18.2±3.0 19.7±3.1	29.9±3.2 29.7±3.4	4.5±0.7 4.4±0.9

R: Right side; L: Left side; Ab: Anterior border of ramus; Pb: Posterior border of ramus; MI: Mandibular incisure; MB: Mandibular base; RMT: retromolar trigone; MF: Mandibular foramen; F: Foramen

Table 4: Comparison of the presence of accessory mandibular foramen

Author	Bilateral (%)	Unilateral (%)	Absent (%)
Sultana Q et al. ¹⁷	13	R-24 L-23	40
Gopalakrishna K et al. ¹⁸	0	18	82
Shalini R et al. ¹⁹	10.3	R-12.2 L-9.8	67.6
Rajkumari K et al. ²⁰	18	10	72
Present study	27.4	R-13.7 L-17.6	41.1

anaesthesia and better comfort to patient. Many studies have been carried out to locate the mandibular foramen using distances from different anatomical landmarks (Table 3).

The mean distance of mandibular foramen from the anterior border of ramus of mandible was 16.4 mm on right side and 16.8 mm on left side which was similar to the studies done by Padmavathi G et al.,¹⁶ Sandhya K et al.,²² Shenoy V et al.¹⁵ Rajkumari K et al.²⁰ and Nicholson ML.³

The mean distance of mandibular foramen from the posterior border of ramus of mandible was 10.2 mm on the

right side and 10.1 mm on left side which was comparable to the studies done by Sandhya K et al.²² and Shalini R et al.¹⁹

The mean distance of mandibular foramen from the mandibular incisure was 22.5 mm on right side and 21.9 mm on left side which was similar to the studies done by Sultana Q et al.,¹⁷ Padmavathi G et al.¹⁶ and Samanta PP et al.¹⁰

The mean distance of mandibular foramen from the Mandibular base was 23.7 mm on right side and 24.5 mm

on left side, which was comparable to the studies done by Shenoy V et al.,¹⁵ Shalini R et al.¹⁹ and Nicholson ML.³

The average distance of mandibular foramen from the third molar was 22.9 mm on right side and 23.5 mm on left side which was analogous to the study done by Gopalakrishna K et al.¹⁸ but less when compared to the studies done by Shalini R et al.,¹⁹ Nicholson ML³ and Sultana Q et al.¹⁷

The mean distance of mandibular foramen from the apex of retromolar trigone was 18.2 mm on right side and 19.7 mm on left side which was more when compared with the study done by Shalini R et al.¹⁹

The anterior posterior distance of ramus of mandible was found 29.9 mm on right side and 29.7 mm on left side which was matching with the studies done by Ennes JP & Medeiros RM¹² and, Nicholson ML.³

The foramen width was observed to be 4.5 mm and 4.4 mm on right and left side respectively which was corresponding to the study done by Shalini R et al.¹⁹

Accessory foramen are found bilaterally in 14 mandibles (27.4%) which is more when compared to studies done by Sultana Q et al.,¹⁷ Shalini R et al.,¹⁹ and Rajkumari K et al.²⁰ Unilaterally it was found in 13.7% and 17.6% on the right and left side respectively, which was lower when compared to study done by Sultana Q et al.¹⁷ and higher when compared to studies done by Shalini R et al.¹⁹ and Rajkumari K et al.²⁰

Gonial angles were 122.6° and 124.1° on the right and left sides respectively which corresponds to the study done by Singh S et al.²³ It was comparatively higher than study done by Nicholson ML³ and lower when compared to studies done by Shenoy V et al.¹⁵ and Ennes JP & Medeiros RM.¹²

In the present study mandibular foramen was predominantly below the occlusal plane of molar teeth was in accordance to the study done by Nicholson ML.³

Present study mainly concentrated on precise location of mandibular foramen by measuring the mean distances from various bony landmarks on the mandible. It was found that the location was almost similar on both sides of ramus indicating bilateral symmetry. Further, it is clear that there is a negative correlation between gonial angle and distance between mandibular foramen and anatomical landmarks. Therefore, the gonial angle can be used to infer the distance between various landmarks and mandibular foramen.

The dentist should be well informed about the common occurrence of accessory mandibular foramina as it may interfere with the inferior alveolar nerve block and prevents complete anaesthesia in the field of interest.

Precise localization of mandibular foramen is clinically very important to achieve effective inferior alveolar nerve block prior to dental surgeries in the lower jaw. This is important for planning and conducting dental procedures such as osteotomy, orthognathic reconstruction surgeries of

mandible, and dental implant procedures. This knowledge will be useful for effective management, better result and prognosis of dental procedures and for avoiding injury to neurovascular contents passing through mandibular foramen.

5. Limitations

The small sample size and lack of details about the age and sex of mandibles are the major limitations of the study.

6. Conclusion

The present study established the bilateral symmetry existing in distances between mandibular foramen and various anatomical landmarks in the mandible. It clearly identified the negative correlation existing between gonial angle and the distances between mandibular foramen and various anatomical landmarks. It also documents the common presence of accessory mandibular foramina. This information will be of paramount importance to the dental surgeons to understand the location of mandibular foramen in relation to various anatomical landmarks and will enable them to obtain better outcomes in inferior alveolar nerve block.

7. Source of Funding

None.

8. Conflict of Interest

The authors have no conflict of interest to declare.

9. Data Availability Atatement

The data supporting this study are available with the corresponding author and will be provided on request.

Acknowledgments

The authors thank Chettinad Hospital and Research Institute, Kelambakkam – 603 103, Tamil Nadu, India for permitting us to carry out the work.


References


1. Standring S. Gray's Anatomy: The Anatomical Basis of Clinical Practice. Netherlands: Elsevier; 2016.
2. Malamed SF. Handbook of Local Anesthesia. 6th ed. India: Elsevier; 2012.
3. Nicholson ML. A study of the position of the mandibular foramen in the adult human mandible. *Anat Rec*. 1985;212(1):110–2.
4. Potocnik I, Bajrović F. Failure of inferior alveolar nerve block in endodontics. *Endod Dent Traumatol*. 1999;15(6):247–51.
5. Vinckier F. What is the cause of failure of local anesthesia? *Rev Belge Med Dent*. 1984;55(1):41–50.
6. Madan GA, Madan SG, Madan AD. Failure of inferior alveolar nerve block: exploring the alternatives. *J Am Dent Assoc*. 2002;133(7):843–6.


7. Neiva RF, Gapski R, Wang HL. Morphometric analysis of implant-related anatomy in Caucasian skulls. *J Periodontol.* 2004;75(8):1061–7.
8. Komar D, Lathrop S. Frequencies of morphological characteristics in two contemporary forensic collections: implications for identification. *J Forensic Sci.* 2006;51(5):974–8.
9. Sutton RN. The practical significance of mandibular accessory foramina. *Aust Dent J.* 1974;19(3):167–73.
10. Samanta PP, Kharb P. Morphometric analysis of mandibular foramen and incidence of accessory mandibular foramina in adult human mandibles of an Indian population Revista Argentina De Anatomía Clínica. *Rev Argentina Anat Clini.* 2013;5(2):60–6.
11. Kilarkaje N, Nayak SR, Narayan P, Prabhu LV. The location of the mandibular foramen maintains absolute bilateral symmetry in mandibles of different age-groups. *Hong Kong Dent J.* 2005;2:35–7.
12. Ennes JP, Medeiros RMD. Localization of mandibular foramen and clinical implications. *Int J Morphol.* 2009;27(4):1305–11.
13. Prado FB, Groppo FC, Volpato MC, Caria PH. Morphological changes in the position of the mandibular foramen in dentate and edentate Brazilian subjects. *Clin Anat.* 2010;23(4):394–8.
14. Thangavelu K, Kannan R, Kumar NS, Rethish E, Sabitha S, Sayeeganesh N. Significance of localization of mandibular foramen in an inferior alveolar nerve block. *J Nat Sci Biol Med.* 2012;3(2):156–60.
15. Shenoy V, Vijayalakshmi S, Saraswathi P. Osteometric Analysis of Mandibular Foramen in Dry Human Mandibles. *J Clin Diagn Res.* 2012;6(4):557–60.
16. Padmavathi G, Tiwari S, Varalakshmi K, Roopashree R. An Anatomical Study of Mandibular and Accessory Mandibular Foramen in Dry Adult Human Mandibles of South Indian Origin. *IOSR J Dent Med Sci.* 2014;13:83–8.
17. Sultana Q, Shariff M, Avadhani R. Study of surgical landmarks of mandibular foramen for inferior alveolar nerve block: An Osteological study. *Indian J Clin Anat Physiol.* 2016;3(1):37–40.
18. Gopalakrishna K, Deepalaxmi S, Somashekara S, Rathna B. An anatomical study on the position of mandibular foramen in 100 dry mandibles. *Int J Anat Res.* 2016;4(1):1967–71.
19. Shalini R, Ravivarman C, Manoranjitham R, Veeramuthu M. Morphometric study on mandibular foramen and incidence of accessory mandibular foramen in mandibles of south Indian population and its clinical implications in inferior alveolar nerve block. *Anat Cell Biol.* 2016;49(4):241–8.
20. Rajkumari K, Nongthombam S, Chongtham R, Huidrom S, Tharani P, Sanjenbam S. A morphometric study of the mandibular foramen in dry adult human mandibles - A study in RIMS, Imphal. *IOSR J Dent Med Sci.* 2017;16(12):39–45.
21. Sahu RK, Panigrahi S, Rath B, Rath S. Location of the Mandibular Foramen in Dry Mandibles: A Study in Southern Odisha. *IOSR J Dent Med Sci.* 2017;16:32–5.
22. Sandhya K, Singh B, Lugun N, Prasad R. Localization of mandibular foramen relative to landmarks in East Indian mandibles. *Indian J Dent Res.* 2015;26(6):571–5.
23. Singh S, Kumar P, Sinha P, Sushobhana, Passey J, Singh R. Location of mandibular foramen in correlation with the gonial angle In Indian population: A morphometric study for surgical practices. *Int J Anat Res.* 2015;3(3):1345–50.


Author biography

Sowjanya Bandlamudi, Professor  <https://orcid.org/0000-0002-0944-9432>

Pavithra M, Intern  <https://orcid.org/0009-0000-2460-9572>

Manickam Subramanian, Associate Professor  <https://orcid.org/0000-0001-8277-9975>

Arathi Senthappan Mariappan, Professor  <https://orcid.org/0000-0002-1423-7995>

Janani Yoganandham, Associate Professor  <https://orcid.org/0000-0002-4173-2828>

Cite this article: Bandlamudi S, Pavithra M, Subramanian M, Mariappan AS, Yoganandham J. Location of mandibular foramen in dry mandibles in relation to various anatomical landmarks. *IP Int J Maxillofac Imaging* 2024;10(1):14–19.