

Content available at: <https://www.ipinnovative.com/open-access-journals>

IP International Journal of Maxillofacial Imaging

Journal homepage: <https://www.ijmi.in/>

## Case Report

# Ranula– A case report and literature review

Surya Krishnakumar<sup>1</sup>, Divya VC<sup>1\*</sup>

<sup>1</sup>Dept. of Oral Medicine and and Radiology, SRM Kattankulathur Dental College and Hospital, Kattankulathur, Tamil Nadu, India



### ARTICLE INFO

#### Article history:

Received 01-01-2024

Accepted 16-03-2024

Available online 14-05-2024

#### Keywords:

Cystic swelling

Ranula

Submental region

Sialography

Plexiform neurofibromas

Marsupialization

### ABSTRACT

Ranula, a salivary gland disorder, manifests as a cystic swelling on the floor of the mouth and can arise from various etiologies such as trauma, obstruction, or inflammation. This article explores the diversity of treatment modalities proposed for ranula, including incision and drainage, marsupialization, and sublingual gland removal. The recurrence of ranula is discussed in relation to treatment types, with reported rates varying significantly. This article discusses a case study of intraoral swelling in a 19-year-old male patient, emphasizing the importance of understanding and managing ranula in clinical practice.

This is an Open Access (OA) journal, and articles are distributed under the terms of the [Creative Commons Attribution-NonCommercial-ShareAlike 4.0 License](https://creativecommons.org/licenses/by-nc-sa/4.0/), which allows others to remix, tweak, and build upon the work non-commercially, as long as appropriate credit is given and the new creations are licensed under the identical terms.

For reprints contact: [reprint@ipinnovative.com](mailto:reprint@ipinnovative.com)

## 1. Introduction

A ranula is a swelling filled with mucus that typically occurs on the floor of the mouth. It typically appears as a distinct, soft, bluish swelling covered by a thin layer of epithelium.<sup>1</sup> Ranulas can develop from accumulated mucin resulting from the rupture of acini in the sublingual gland or a ruptured Rivinus duct. As ranulas are lined with granulation tissue rather than epithelium, they are classified as a type of pseudocyst.<sup>2,3</sup> There are two main types of ranulas: the simple (intraoral) type and the plunging (cervical) type. The simple ranula involves a localized mucus collection in the floor of the mouth and is more common than the plunging type. In the plunging ranula, the mucus collection is found in the submandibular and submental spaces of the neck, sometimes with an associated intraoral collection.<sup>1</sup> This article details a case involving a nineteen-year-old male patient who reported an intraoral swelling.

## 2. Case Report

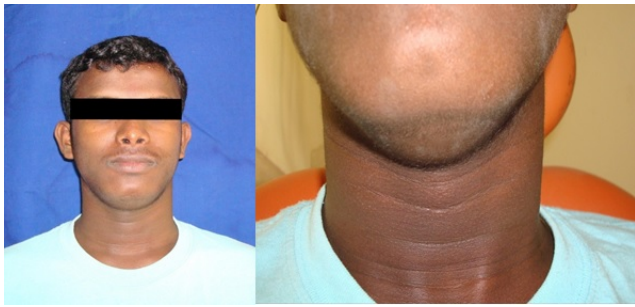A 19-year-old male patient visited the department of oral medicine and radiology seeking tooth replacement. The patient reported a swelling below his chin persisting for the past year, maintaining a consistent size. Remarkably, he remained asymptomatic, and there were no significant contributions from family, personal, or previous medical history. During the examination, the patient demonstrated good general condition with stable vital signs.

On extra-oral examination, in the submental region, a swelling was identified, measuring approximately 5×4 cm. It presented a round shape with indistinct margins, extending 2 cm anteriorly from the Mandible's anterior border, 4 cm posteriorly, and 2.5 cm on either side of the midline. The surface was smooth and matched the colour of the surrounding mucosa. Palpation revealed a non-tender, soft, mobile, fluctuant swelling that was compressible but not reducible, affirming the initial observations of its site, size, shape, and extent.

On intraoral examination, a solitary, well-defined hemispherical swelling, measuring approximately 4×3 cm,

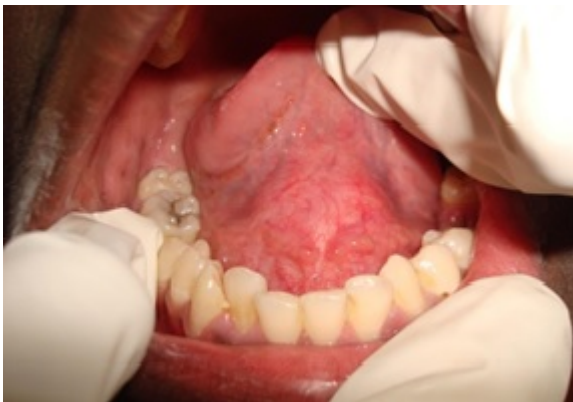\* Corresponding author.

E-mail address: [divyav@srmist.edu.in](mailto:divyav@srmist.edu.in) (Divya VC).



**Figure 1:** Extraoral photograph showing swelling in the submental region

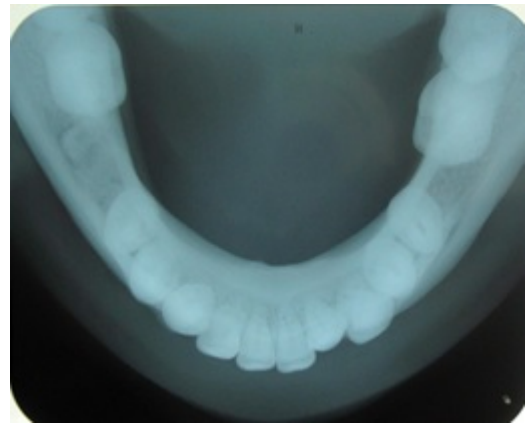was located in connection with the floor of the mouth. It extends anteriorly from the lingual surface of the alveolar process of teeth 31 and 41 to the base of the tongue posteriorly. From the lingual surface of the alveolar process of teeth 34 and 35 region, it crosses the midline to the region of teeth 44 and 45. The surface appears smooth and matches the colour of the surrounding mucosa. Upon palpation, the swelling is non-tender, soft, mobile, fluctuant, and compressible but not reducible. These findings confirm the initial observations related to the site, size, shape, and extent of the swelling.



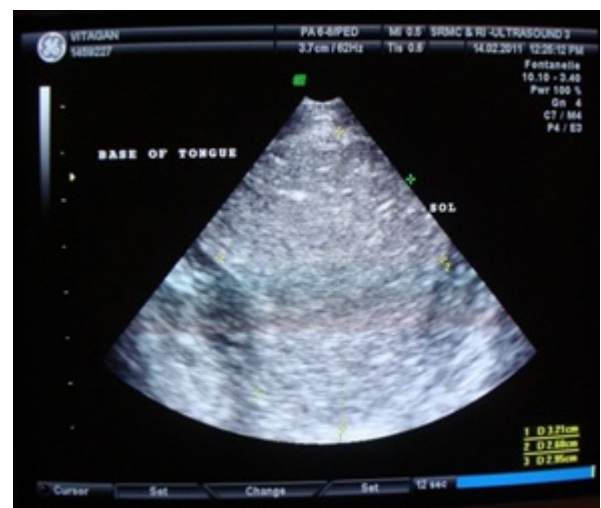**Figure 2:** Intraoral photograph showing swelling on floor of mouth

Based on history and clinical features, a provisional diagnosis of “ranula” was considered.

Radiographic examination with mandibular cross-sectional occlusal radiograph reveals missing 36 and loss of crown structure in 46 region suggestive of root stump 46. Ultrasonography, reveals a well-defined lesion, a solid echoic area with internal echoes seen within size 3.2×2.6×2.9 cm, seen posterior to the tongue. Features suggestive of an infected ranula. Following thorough examination and investigation, surgical excision was performed. Additionally, we also obtained consent from the patient to share his clinical and radiographic photographs for the purpose of academic interest and publication.



**Figure 3:** Mandibular occlusal radiograph



**Figure 4:** Ultrasonography of base of tongue

### 3. Discussion

A "ranula" gets its name from the Latin word "rana," meaning "frog," owing to its resemblance to a frog's translucent underbelly or air sacs. These swellings are typically sizable (>2 cm) and manifest as tense, fluctuant dome-shaped vesicles, often displaying a blue hue. Ranulas stem from the leakage and buildup of saliva from the sublingual gland. When a salivary duct is obstructed, the pressure causes a rupture, forcing mucus into surrounding tissues. In the case of a cervical or plunging ranula, mucin is dissected through a perforation in the mylohyoid muscle in the submandibular space.<sup>4-6</sup>

Bhaskar et al.<sup>7</sup> investigated the pathogenesis of ranula histopathologically and experimentally, concluding that it results from saliva extravasation from a damaged sublingual gland and lacks an epithelial lining. Ranulas are rare, with a reported male-to-female ratio of 1:1.3.<sup>8</sup> They typically present unilaterally, appearing as bluish, well-circumscribed, painless, fluid-filled swellings in the mouth.

Usually, observed in children and young adults, ranulas peak in frequency during the second decade.<sup>3</sup>

However, ranulas have been documented as early as the 21st week of gestation<sup>9</sup>, with a prevalence of congenital ranulas estimated at 0.74%.<sup>10</sup> A study conducted in Zimbabwe revealed that 88.5% of children diagnosed with ranulas were found to be HIV seropositive.<sup>11</sup> Several etiological factors have been associated with the occurrence of a ranula. Damage to one or more ducts due to trauma, obstruction, or inflammation can result in the leakage of salivary contents into the surrounding tissue. This, in turn, triggers a fibroblastic reaction that encapsulates the mucus within a connective tissue sac, known as an extravasation pseudocyst. The most prevalent form of ranula is attributed to such incidents. In fewer than 10% of all ranula cases, a retention cyst forms due to congenital obstruction, either from an imperforate salivary duct or an ostial adhesion.<sup>12</sup> Additionally, iatrogenic factors have been reported as contributing to such conditions.<sup>12</sup> During infancy, duct agenesis, hypoplasia, or birth trauma are proposed as primary causes.<sup>13</sup>

While it typically remains asymptomatic, there are instances where patients may report difficulties in speech, chewing, swallowing, and breathing.<sup>12,14,15</sup> Typically, the swelling exhibits a smaller size in the early morning and enlarges just before meals. This phenomenon is attributed to heightened secretory activity during periods of gustatory stimulation, coupled with water absorption from the accumulated mucous during inactive intervals. Notably, the swelling cannot be alleviated through digital pressure, and it presents as a fluctuant, brilliantly translucent mass, particularly evident during trans-illumination.

The diagnosis of ranula is primarily based on its clinical presentation. Still, various imaging modalities, including Computed Tomography (CT), Magnetic Resonance Imaging (MRI), Ultrasonography, Sialography, and nuclear imaging, have been employed to delineate lesion borders and assess their relationship with adjacent structures.<sup>12,14,16,17</sup> Ultrasonography is the preferred initial evaluation method,<sup>18</sup> providing information on the location and size of the lesion. Although it offers fewer details compared to CT and MRI, ultrasonography reveals ranulas as thin-walled cystic lesions, visualized either extra orally or trans-orally with a small probe. In cases of infection, thickened walls and increased echogenicity of fluid content may be observed due to debris from prior inflammation episodes. For plunging ranulas, where a significant portion of the cystic collection is situated in the submandibular region with a smaller part visible in the sublingual space,<sup>18</sup> additional details on the extent of the mass can be obtained through computed tomography.

The characteristic appearance of a ranula on CT is that of a thin-walled, ovoid-shaped cystic lesion with central homogeneous fluid attenuation (10–20 Hounsfield units).

In instances of infection or prior interventions, increased attenuation of the content and thickened walls may be evident.<sup>18</sup> In the case of plunging ranulas, a distinctive feature known as the "TAIL SIGN" becomes prominent, resembling a tail extending beyond the mylohyoid muscle from the sublingual gland.<sup>13</sup>

Magnetic resonance imaging is considered the most preferred imaging technique for cystic lesions, offering detailed information on lesion extension and its relationship with surrounding normal structures.<sup>17</sup> Magnetic resonance imaging (MRI) is particularly valuable due to its excellent soft tissue resolution, making it highly effective in cases involving extension through multiple anatomical spaces. In MRI, ranulas typically exhibit low signal intensity on T1-weighted sequences and high signal intensity on T2-weighted sequences. Notably, when the cystic fluid has a higher protein content, it appears hyper-intense on the T1-weighted sequence.<sup>18</sup> Conversely, sialography, while a useful imaging modality, provides fewer details regarding ranulas.<sup>12</sup> Specifically, a sialogram of the submandibular duct typically reveals no communication with the cyst.<sup>19</sup>

Fine needle aspiration cytology (FNAC) plays a supplementary role in confirming the diagnosis. FNAC reveals mucin with muciphages and provides information on the increased levels of amylase and protein concentration.<sup>12</sup> In cases of extravasated mucous, elevated levels of matrix metallo-proteins, TNF- $\alpha$ , type IV collagenase, plasminogen activators, and proteolytic enzymes contribute to the invasive nature of extravasated mucous.<sup>17</sup>

Histopathological examination further supports the diagnosis, depicting a cyst characterized by the absence of lining epithelium, loose vascularized connective tissue, and the presence of inflammatory cells, histiocytes, and a foreign body giant cell reaction. Importantly, signs of malignancy are usually absent in the histopathological findings.<sup>14,16</sup>

The differential diagnosis for ranula encompasses various conditions, including vascular lesions, superficial non-keratotic cysts, muco-epidermoid tumours, and mucinous adenocarcinoma. Differentiation becomes essential when the lesion is not superficial, presenting with a thicker wall exhibiting a pinkish rather than bluish appearance, and the consistency is soft to rubbery, fluctuant but not emptiable. This scenario warrants distinguishing from superficial cysts, lipomas, plexiform neurofibromas, deep cavernous hemangiomas, lymphangiomas, and mucous-producing salivary gland tumours. Furthermore, the differential diagnosis extends to swellings occurring in the floor of the mouth and submandibular space, such as dermoid and epidermoid cysts, branchial cleft cysts, thyroglossal duct cysts, cystic hygromas, lipomas, abscesses, and malignant neoplasms. Aspiration becomes a crucial diagnostic tool, especially when it yields sticky, viscous, clear mucous-like fluid, helping eliminate various

swellings except for salivary gland tumours that secrete mucous, albeit these are relatively uncommon. Additionally, consideration should be given to tissue reactions to foreign bodies. There are reported cases where intraoperative identification of a foreign body (such as a spray cover) initially diagnosed and operated as a sublingual ranula highlighted the importance of careful consideration and examination in such scenarios.<sup>20</sup>

Several treatment options have been suggested for ranula, encompassing procedures such as incision and drainage, marsupialization, irradiation, sclerosing agent injection, cyst excision, and removal of the sublingual gland along with the lesion.<sup>3,21–23</sup> Additionally, alternative treatments involve the use of botulinum toxin type A injections for ranula management.<sup>24</sup>

The likelihood of ranula recurrence is influenced by the chosen treatment method. Crysdale et al.<sup>25</sup> observed that the recurrence rates varied: 100% for cases treated with incision and drainage, 61% for simple marsupialization, and 0% for cases where ranula excision, with or without sublingual gland excision.

Damage to one or more ducts due to trauma, obstruction, or inflammation can result in the leakage of salivary contents into the surrounding tissue. This, in turn, triggers a fibroblastic reaction that encapsulates the mucus within a connective tissue sac, known as an extravasation pseudocyst. The most prevalent form of ranula is attributed to such incidents. In fewer than 10% of all ranula cases, a retention cyst forms due to congenital obstruction, either from an imperforate salivary duct or an ostial adhesion.<sup>26–28</sup>

Complications associated with sublingual gland excision include the risk of injury to Wharton's duct (2%), bleeding (1–2%), infection (1–2%), or paresthesia of the lingual nerve (2–12%).<sup>16</sup> In a study conducted by Zhao YF et al., which followed 415 patients, recurrence rates were observed to be 66.6% after marsupialization, 57.69% after ranula excision, and notably lower at 1.2% after sublingual gland excision.<sup>13</sup> These findings underscore the importance of considering the potential complications and recurrence rates associated with different treatment approaches for ranula management. Successful treatment of salivary gland disorders hinges on accurate diagnosis aided by advancements in imaging technology.

#### 4. Conclusion

Our case report explores the manifestation of a ranula without a clear or known history of trauma, making it challenging to pinpoint the exact cause. This presentation, without a definitive aetiology, can evoke anxiety in patients, emphasizing the necessity for healthcare professionals to provide comprehensive information on the likelihood of frequent recurrence if inadequately managed and the potential complications associated with the condition. It is crucial to reassure the patient by offering detailed insights

into the condition's recurrence patterns and associated complications. The varied clinical and radiographic appearances of ranulas may sometimes lead diagnosticians astray, potentially overlooking other possible differential diagnoses. Despite its seemingly straightforward nature, a ranula can undergo a malignant transformation in the cystic lining, underscoring the importance of vigilant scrutiny in its assessment.<sup>29</sup>

#### 5. Source of Funding

None

#### 6. Conflict of Interest

None


#### References

- Lloyd DA, Elgabrun M, Carty H. Plunging (cervical) ranula. *Pediatr Surg Int*. 1995;10:144–5.
- Zhi K, Gao L, Ren W. What is new in management of pediatric ranula? *Curr Opin Otolaryngol Head Neck Surg*. 2014;22(6):525–9.
- Zhao YF, Jia Y, Chen XM, Zhang WF. Clinical review of 580 ranulas. *Oral Surg Oral Med Oral Pathol Oral Radiol Endod*. 2004;98(3):281–7.
- Langlois NE, Kolhe P, 1992 Nov;23(11):1306-8 doi: 10.1016/0046-8177(92)90300-r PMID: 1427758 . Plunging ranula: a case report and a literature review. *Hum Pathol*. 1992;23(11):1306–8.
- De Visscher J, Van Der Wal K, De Vogel P. The plunging ranula. Pathogenesis, diagnosis and management. *J Craniomaxillofac Surg*. 1989;17(4):182–5.
- Skouteris CA, Sotereanos GC. Plunging ranula: report of a case. *J Oral Maxillofac Surg*. 1987;45(12):1068–73.
- Bhaskar SN, Bolden TE, Weinmann JP. Pathogenesis of mucocoeles. *J Dent Res*. 1956;35(6):863–74.
- Chidzonga MM, Mahomva L. Ranula: experience with 83 cases in Zimbabwe. *J Oral Maxillofac Surg*. 2007;65(1):79–82.
- Onderoglu L, Saygan-Karamursel B, Deren O, Bozdag G, Teksam O, Teksam G. Prenatal diagnosis of ranula at 21 weeks of gestation. *Ultrasound Obstet Gynecol*. 2003;22(4):399–401.
- Soni A, Suyal P, Suyal A. Congenital ranula in a newborn: a rare presentation. *Indian J Otolaryngol Head Neck Surg*. 2012;64(3):295–7.
- Kinshuck AJ, Schober M, Kokai G, Clarke R. Oral ranula in an HIV-positive patient: case report and literature review. *BMJ Case Rep*. 2012;2012(10):620114407.
- Chauhan RS, Chauhan VS, Shirol D, Lele G. Ranula in an adolescent patient. *J Dent Allied Sci*. 2014;3(2):105–12.
- Arunachalam P, Priyadarshini N. Recurrent plunging ranula. *J Indian Assoc Pediatr Surg*. 2010;15(1):36–44.
- Albsoul NM, Obeidat FO, Altaher RN, Jubouri SA, Hadidy AM. Recurrent right sublingual ranula, concomitant with ipsilateral submandibular salivary gland aplasia. *Int J Surg Case Rep*. 2013;4(2):229–31.
- Bahnassy M. A huge oral ranula. *Oman Med J*. 2009;24(4):306–7.
- Dietrich EM, Vasilios B, Maria L, Styliani P. Antoniadis Konstantinos. Sublingual-plunging ranula as a complication of supraomohyoid neck dissection. *Int J Surg Case Rep*. 2011;2(6):90–2.
- Ghani NA, Ahmad R, Rahman RA, Yunus M, Putra SP, Ramli R. A retrospective study of ranula in two centres in Malaysia. *J Maxillo Oral Surg*. 2009;8(4):316–25.
- Mittal MK, Malik A, Sureka B, Bsheshanthukral B. Cystic masses of a neck: a pictorial review. *Ind J Radiol Imag*. 2012;22(4):334–43.
- La'porte SJ, Juttla JK, Lingam RK. Imaging the Floor of the Mouth and the Sublingual Space. *RadioGraphics*. 2011;31(5):1215–45.

20. Shehata E, Moussa K, and AAG. A foreign body in the floor of the mouth. *Saudi Dent J*. 2010;22(3):141–4.
21. Anastassov GE, Haiavy J, Solodnik P, Lee H, Lumerman H. Submandibular gland mucocele: diagnosis and management. *Oral Surg Oral Med Oral Pathol Oral Radiol Endod*. 2000;89(2):159–63.
22. Yuca K, Bayram I, Cankaya H, Caksen H, Kiroglu AF, Kiris M. Pediatric intraoral ranulas: an analysis of nine cases. *Tohoku J Exp Med*. 2005;205(2):151–5.
23. Zhao YF, Jia J, Jia Y, 2005 Jan;63(1):51-4 doi: 10.1016/j.joms.2004.02.018 PMID: 15635557 . Complications associated with surgical management of ranulas. *J Oral Maxillofac Surg*. 2005;63(1):51–4.
24. Chow TL, Chan SW, Lam SH. Ranula successfully treated by botulinum toxin type A: report of 3 cases. *Oral Surg Oral Med Oral Pathol Oral Radiol Endod*. 2008;105(1):41–2.
25. Crysedale WS, Mendelsohn JD, Conley S. Ranulas mucoceles of the oral cavity: experience in 26 children. *Laryngoscope*. 1988;98(3):296–8.
26. Gupta A, Karjodkar FR. Plunging ranula: a case report. *ISRN Dent*. 2011;2011:806928.
27. O'connor R, Mcgurk M. The plunging ranula: diagnostic difficulties and a less invasive approach to treatment. *Int J Oral Maxillofac Surg*. 2013;42(11):1469–74.
28. Sharma P, Sharma R, Nagrath S. Plunging ranula treated by combination of intra oral and extra oral approach: a rare case report. *Int J Res Dev Pharm L Sci*. 2015;4(5):1766–9.
29. Ali MK, Chaiancone G, Knox GW. Squamous cell carcinoma arising in a plunging ranula. *J Oral Maxillofac Surg*. 1990;48(3):305–8.

### Author biography

Surya Krishnakumar, Intern

Divya VC, Associate Professor  <https://orcid.org/0000-0001-7042-6435>

**Cite this article:** Krishnakumar S, Divya VC. Ranula– A case report and literature review. *IP Int J Maxillofac Imaging* 2024;10(1):30-34.