

Content available at: <https://www.ipinnovative.com/open-access-journals>

IP International Journal of Maxillofacial Imaging

Journal homepage: <https://www.ijmi.in/>

Case Report

Insights into Stafne's bone cyst: A case report of an accidental finding

Mahendra Ramdas Patait¹, Kartikee Vinit Bhoir^{1*}, Kishor Kashinath Patil²,
Shriya Ravindra Maknikar¹

¹Dept. of Oral Medicine & Maxillofacial Radiology, SMT Dental College, Hospital & Research Institute, Sangamner, Maharashtra, India

²Dept. of Oral Pathology, SMT Dental College, Hospital & Research Institute, Sangamner, Maharashtra, India



ARTICLE INFO

Article history:

Received 18-04-2024

Accepted 27-04-2024

Available online 14-05-2024

Keywords:

Stafne bone cyst

Pseudocysts

Cone beam computed tomography

Radiographic findings 1

ABSTRACT

Stafne Bone Cysts (SBC) represent pseudocysts of the jaw, typically characterized by their presence at the lingual cortical surface and involvement of normal salivary gland tissue. These cysts, devoid of an epithelial lining, exhibit a diverse composition, comprising blood vessels, muscle, fat, connective tissue, lymphatic tissue, nerve bundles, or air. Commonly, SBCs manifest without clinical symptoms or signs, necessitating radiographic methods for diagnosis. They are usually discovered incidentally on routine radiographs of the jaw. We here present a 50-year-old male with pain in the mandibular left side and a routine panoramic radiograph showed impacted mandibular third molars on both sides and a well-defined radiolucency below the inferior alveolar canal on the left side. An incidental finding of Stafne's bone cyst was made on further investigation on Cone Beam Computed Tomography (CBCT). While conventional X-rays serve as the primary diagnostic tool, complex cases may require more precise imaging modalities, such as CBCT. This case study offers a comprehensive analysis of a unilateral SBC identified in a male patient with an emphasis on the radiographic features.

This is an Open Access (OA) journal, and articles are distributed under the terms of the [Creative Commons Attribution-NonCommercial-ShareAlike 4.0 License](https://creativecommons.org/licenses/by-nc-sa/4.0/), which allows others to remix, tweak, and build upon the work non-commercially, as long as appropriate credit is given and the new creations are licensed under the identical terms.

For reprints contact: reprint@ipinnovative.com

1. Introduction

In 1942, Edward Stafne published the first description of the Stafne bone cavity (SBC), also referred to as the static bone cavity, salivary inclusion cyst, latent cyst, and lingual bone defect.^{1,2} It is an asymptomatic bony deformity that is usually located just above the inferior border of the mandible and beneath the mandibular canal. In rare cases, it is observed in the apical region of the premolars or canines in the anterior mandible.³ Between 0.10% and 6.06% of cases have been reported to have the posterior variant SBC.^{4,5} It usually affects one side of the mandible, though it can potentially happen on the other side.⁶ It is known that the submandibular gland, adipose tissue, connective tissue,

lymphatic tissue, muscle, or veins may be the contents of the SBC.⁷ Panoramic radiography is the method used in clinical settings to inadvertently find most cases of SBC. Being an asymptomatic bone cavity that does not require treatment, it is relatively hard to find a real bony defect without radiographic imaging. This report's objective is to demonstrate a fresh case of an SBC and highlight its unique characteristics.

2. Case History

A 50-year-old male patient was referred to the outpatient department by his general dentist regarding consultation of pain and radiolucent lesion on the lower left side of the jaw. (Figure 1) The patient had intermittent, dull aching pain in the lower left side of the jaw since 1 month. The pain

* Corresponding author.

E-mail address: dr.kartikeebhoir@gmail.com (K. V. Bhoir).

precipitated on mastication of food. Whereas the lesion was detected on a panoramic radiograph that was performed as a routine control. The patient did not have any significant medical history, although the patient did his root canal treatment with 25, 26, 36, 37, 44, and 45, two to three years ago. On clinical examination, all teeth were present except the third molars and ceramic crown prosthesis was noticed with 36 and 37 teeth. On further examination, the patient did not give any history of extraction of third molars. (Figure 2)

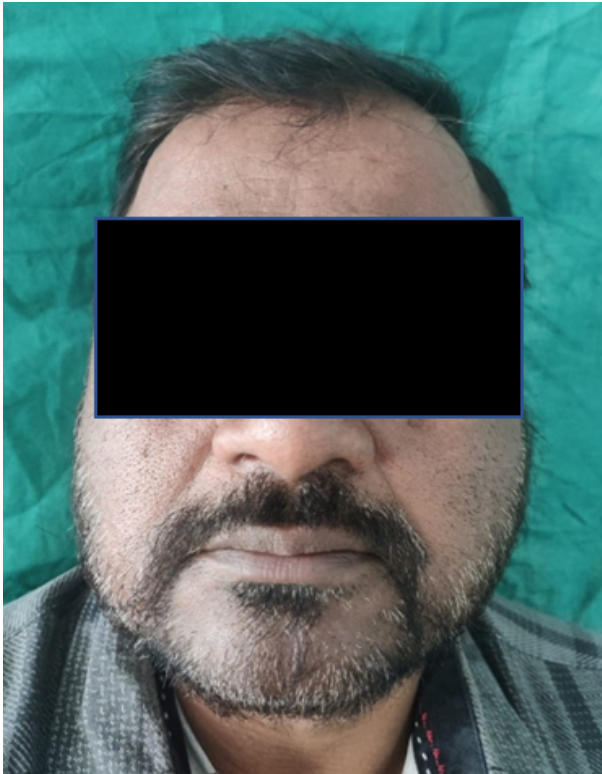

Figure 1: Extraoral presentation of the patient

The panoramic radiograph which was taken, revealed impacted 38 and 48 tooth and unilocular periapical radiolucency below the third molar on the left side. A well-defined oval radiolucency was seen below and in contact with the inferior alveolar canal. (Figure 3) For further assistance, it was decided to examine the lesion using cone beam computed tomography (CBCT), to evaluate the relationship of the lesion with surrounding tissues and to predict its pathological possibilities. The CBCT scan revealed mesioangularly impacted 38 tooth which was in close proximity to the inferior alveolar nerve of the left side. Whereas, a well-defined oval radiolucency was seen just below the inferior alveolar nerve of the left side in the 38 tooth region which was not in relation with the tooth itself and had an approximate size of 9.48 X 8.51 mm. (Figure 4) In coronal slices, we could notice the loss of lingual cortical plate in the same region, which confirmed our radiographic diagnosis to be Stafne's Bone Cyst. (Figure 5) Clinical

and Radiographical examination revealed that there was no relation between the symptoms and the lesion. The pain that the patient was experiencing might have been due to the mesioangularly impacted 38 and the radiolucency was in no relation with the tooth. The patient was then advised for extraction with 38 if necessary.

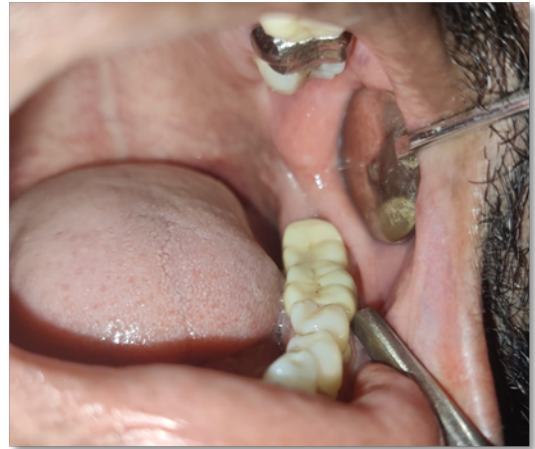

Figure 2: Intraoral presentation of left mandibular arch

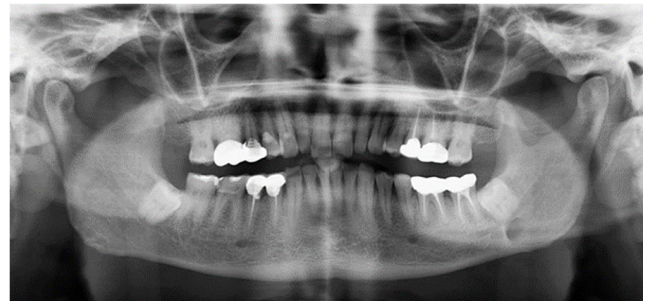

Figure 3: Orthopantomogram showing well-defined oval radiolucency seen below the inferior alveolar canal on left side

3. Discussion

SBCs often manifest in the fifth or sixth decades of life and are 3:1 more common in males than females. However, females begin to have symptoms in their third or fifth decade.⁸ Based on its location, SBC is comparatively simple to identify radiographically, particularly if usual radiographic characteristics are present. These features include a round to oval radiolucency with loss of lingual cortical plate and intact buccal cortical plate, as well as continuity with the base of the mandibular canal.^{8,9} In some atypical cases of SBC, further diagnostic techniques should be used to rule out any pathology.

Though several explanations have been proposed in the literature, the etiopathogenesis of SBCs is still poorly understood. Stafne¹⁰ and several other researchers^{11–14}

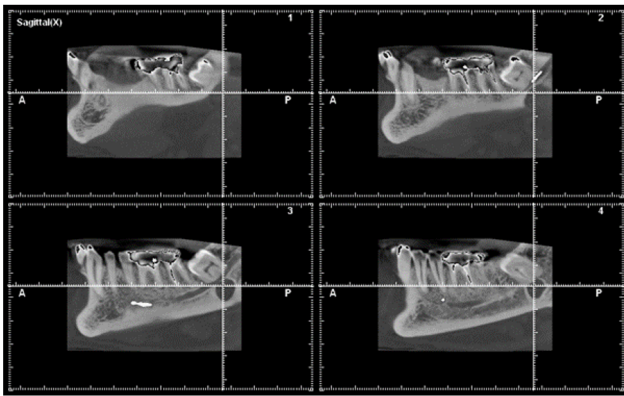


Figure 4: CBCT scan (Sagittal view) showing well defined radiolucency in 38 tooth region

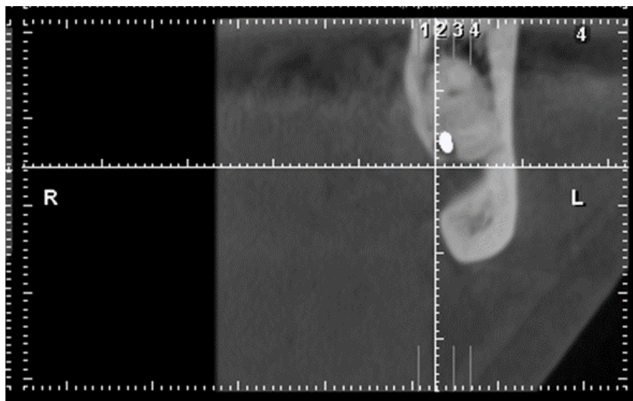


Figure 5: CBCT scan (Coronal view) showing loss of lingual cortical plate in 38 tooth region

claim that this cavity developed as a result of Meckel's cartilage being replaced by bone tissue throughout the mandibular development process. Another explanation put out by Philipsen et al.¹¹ to explain the etiology of SBCs is the pressure of the salivary gland tissue.

If doubts persist, a differential diagnosis based on the lesion's site for mandibular radiolucency should be taken into account. The posterior, anterior, ramus and buccal ramus areas are the four anatomic sites close to the main salivary glands where SBCs are observed.^{11,15} The symphyseal and/or para symphyseal area is related to the anterior kind of SBC, which can be mistaken for other jaw diseases such as giant cell granuloma, radicular cyst, simple bone cyst, traumatic bone cyst, and residual cyst.^{16,17} Younger individuals are typically diagnosed with traumatic bone cysts, which are characterized by a scalloped contour between the dental roots on radiographs. Whereas the radicular cyst is related to the overlying tooth structure and the radiolucency arises from the roots of the tooth itself.¹⁸ Additionally, residual cysts are typically seen on radiographs in the edentulous area of previously extracted

teeth, mainly above the inferior alveolar canal. These cysts are the result of partial excision of radicular or other inflammatory cysts.¹⁹ Furthermore, diseases like brown tumor (dependent on hyperparathyroidism), basal cell nevus syndrome, eosinophilic granuloma, benign salivary gland tumors, neurogenic tumors, odontogenic keratocyst, hemangioma, myxoma, or vascular malformation should be considered for posterior SBCs.¹¹ Eosinophilic granuloma is a disease caused by the proliferation of Langerhans cells. It is present with symptoms such as pain and swelling which is not seen in our case and radiographically it presents as a "scooped out" appearance. Whereas Odontogenic keratocyst is usually associated with an impacted tooth and it may cause inferior displacement of the Inferior alveolar canal.¹⁵

Due to its asymptomatic nature, SBC can be discovered by accident during standard 2D imaging. The diagnosis will be difficult in less evident situations, though, where the lesion will be found in the anterior region. Several methods have been used, as documented in the literature, to validate the defect's diagnosis. These methods include Sialography, Magnetic Resonance Imaging (MRI), Computerised Tomography, and Cone Beam CT.^{20,21} Because of its excellent spatial resolution and ability to detect the bone border, CBCT is regarded as one of the most useful diagnostic methods for the diagnosis of SBC. By identifying the bone border, we can rule out the possibility of any other intraosseous true cystic or tumor lesions, such as traumatic cysts or odontogenic tumors, respectively.²⁰

A CBCT scan was recommended in our situation in addition to the panoramic imaging, as it provides an accurate three-dimensional image that aided in the diagnosis of SBC. CBCT clarifies a well-defined lingual radiolucency with a thin cortical border in the area where the lesion is seen in the axial or coronal view. Whereas the sagittal view offers a view of the lesion where the shape is differentiated as well as we can appreciate the location of the lesion concerning the inferior alveolar canal.¹⁹ From a therapeutic standpoint, surgery shouldn't be an option, especially since SBC is a pseudocyst and is static and benign by nature. As such, a "wait and watch" strategy is preferable in almost all situations, including ours, with frequent follow-up that occasionally involves radiographic surveillance.

4. Conclusion

SBC is an uncommon condition that is discovered randomly during radiographic evaluation. Its etiopathogenesis remains debatable. Dental practitioners should be knowledgeable about this anatomic variance, be able to differentiate SBCs from other conditions and be able to make treatment or follow-up decisions based on their diagnosis.

5. Source of Funding

None.


6. Conflicts of Interest

The authors declare no conflicts of interest.

References

- Rushton MH. Solitary bone cysts in the mandible. *Br Dent J*. 1946;81(2):37–49.
- Stafne EC. Bone cavities situated near the angle of the mandible. *J Am Dent Assoc*. 1942;29(17):1969–72.
- Daniels JS, Albakry I, Samara MI, Braimah RO. Stafne bone cyst: Report of a case and review of the literature. *Saudi J Health Sci*. 2020;9(1):71–3.
- Bayrak NB. A rare presentation of stafne bone cyst. *Oral and Maxillofacial Surgery*. 2020;121(1):80–83.
- Quesada-Gómez C, Valmaseda-Castellón E, Berini-Aytés L, Gay-Escoda C. Stafne bone cavity: a retrospective study of 11 cases. *Med Oral Patol Oral Cir Bucal*. 2006;11(3):277–80.
- Deotale K, Lanjekar A, Madne I, Tayade C, Akhtar Z, Jaiswal R. Stafne bone cyst of mandible A case report with comprehensive imaging features using cone beam computed tomography and literature review. *Arch Dent Res*. 2022;12(2):127–33.
- Etöz ME, Etöz OA, Şahman H, Şekerci AE, Polat HB. An unusual case of multilocular Stafne bone cavity. *Dentomaxillofac Radiol*. 2012;41(1):75–8.
- Aps JKM, Koelmeyer N, Yaqub C. Stafne's bone cyst revisited and renamed: the benign mandibular concavity. *Dentomaxillofac Radiol*. 2020;49(4):20190475.
- Ozdede M. An unusual case of double stafne bone cavities. *Surg Radiol Anat*. 2020;42:543–549.
- Stafne EC. Bone cavities situated near the angle of the mandible. *J Am Dent Assoc*. 1942;29(17):1969–72.
- Philipsen HP, Takata T, Reichart PA, Sato S, Sueti Y. Lingual and buccal mandibular bone depressions: a review based on 583 cases from a world-wide literature survey, including 69 new cases from Japan. *Dentomaxillofac Radiol*. 2002;31:281–90.
- Ariji E, Fujiwara N, Tabata O, Nakayama E, Kanda S, Shiratsuchi Y, et al. Stafne's bone cavity: classification based on outline and content determined by computed tomography. *Oral Surg Oral Med Oral Pathol*. 1993;76(3):375–80.
- Barker GR. Xeroradiography in relation to a Stafne bone cavity. *Br J Oral Maxillofac Surg*. 1988;26:32–7.
- Minowa K, Inoue N, Sawamura T, Matsuda A, Totsuka Y, Nakamura M. Evaluation of static bone cavities with CT and MRI. *Dentomaxillofac Radiol*. 2003;32(1):2–7.
- Aoki EM, Abdala-Júnior R, Nagano CP, Mendes EB, Oliveira JXD, Lourenço SV, et al. Simple bone cyst mimicking Stafne bone defect. *J Craniofac Surg*. 2018;29(6):570–1.
- Sisman Y, Etöz OA, Mavili E, Sahman H, Ertas ET. Anterior Stafne bone defect mimicking a residual cyst: a case report. *Dentomaxillofac Radiol*. 2010;39(2):124–6.
- Lee KC, Yoon AJ, Philipone EM, Peters SM. Stafne bone defect involving the ascending ramus. *J Craniofac Surg*. 2019;30(4):301–3.
- Abbud MU, Ramada KR, Soares RV, Souki BQ, Spyrides KS, Antunes FL. The Importance of Cone Beam Computed Tomography for the Diagnosis of Stafne Bone Defect. *Oral Surg Oral Med Oral Pathol Oral Radiol*. 2020;129(1):50.
- Berberi A. Stafne's Bone Defect Correlated with Submandibular Glands: A Case Report and CBCT and MRI Analysis. *Case Rep Dent*. 2024;2024:1173783.
- Manigandan T, Rakshanaa TR, Dornadula P. Atypical variant of Stafne bone defect mimicking odontogenic cyst of the jaw. *J Oral Maxillofac Pathol*. 2023;27(1):91–4.
- Chen MH, Kao CT, Chang JY, Wang YP, Wu YH, Chiang CP. Stafne bone defect of the molar region of the mandible. *J Dent Sci*. 2019;14(4):378–82.

Author biography

Mahendra Ramdas Patait, Professor and HOD  <https://orcid.org/0000-0002-9046-9587>

Kartikee Vinit Bhoir, MDS 3rd Year

Kishor Kashinath Patil, Associate Professor

Shriya Ravindra Maknikar, MDS 3rd Year

Cite this article: Patait MR, Bhoir KV, Patil KK, Maknikar SR. Insights into Stafne's bone cyst: A case report of an accidental finding. *IP Int J Maxillofac Imaging* 2024;10(1):38–41.