

Ultrasonography in maxillofacial Imaging – a review

Karthik R^{1,*}, Mohan N², Ravikumar PT³, Saramma Mathew Fenn⁴, Sabitha Gokulraj⁵, Cicilia Subbulakshmi⁶

^{1,3}Reader, ²Professor & HOD, Dept. of Oral Medicine & Radiology, ^{4,5,6}Senior Lecturer, Dept. of Oral Medicine, Diagnosis & Radiology, Vinayaka Missions Sankarachariyar Dental College, Salem

***Corresponding Author:**

Email: drkarthik17@gmail.com

Abstract

Ultrasonography is being currently used in imaging of various head and neck pathologies owing to its non-invasive nature and has gained wider acceptance in maxillofacial imaging. In this paper we will take a relook of Ultrasonographic imaging in areas such as its historical Background, basic principles, wide array of applications in Maxillofacial pathologies and advantages, disadvantages, Newer techniques in Ultrasonographic Imaging.

Key words: Piezoelectric, Transducer, Fresnel zone, Fraunhofer zone, Reverberation artefact.

Historical Background

The principles and application of ultrasound was discovered by Curie brothers in 1880. The Dussik brothers in Austria (1937) were the first to describe the use of ultrasound imaging, and later in 1972, Kossoff in Australia and others introduced gray scale ultrasonography.¹ The first recorded evidence referring to the use of sound waves for the spatial orientation in bats dates back to 1794 by Lazaro Spallanzani, who discovered the phenomenon of echo-location. Not long after that, in 1877, Jacques, and Pierre Curie described the piezoelectric and the inverse piezoelectric effect. This path-breaking discovery led to the conceptualization of ultrasonography.²

Ian Donald introduced the Ultrasound in diagnostic medicine in 1956, when he used one-dimensional Amplitude mode (A-mode) to measure the fetal head. The commercial use of US devices began in 1963 when “brightness mode” (B-mode) devices were constructed.

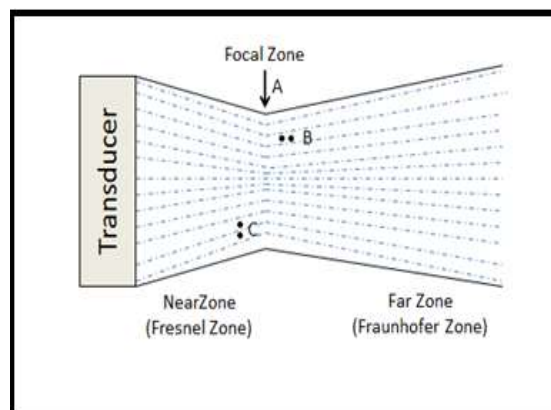
In 1955, Satomura and Nimura were credited for Doppler effect based visualization of blood circulation. The first use of diagnostic Ultrasonographic Imaging in dentistry appears to have been by Baum et al in 1963, to image the internal structures of teeth using 15 MHz wave. The clinical applications in dentistry were studied actively afterward, the most noteworthy being the work of Palou et al. (1987) in the measurement of periodontal bone morphology.⁴ The late 1990s to early 2000 saw an expanded the research focusing on the dental hard tissues and soft tissues. Hinders and co-workers (1998) developed the US periodontal probe at NASA Langley Research Center.

Principle

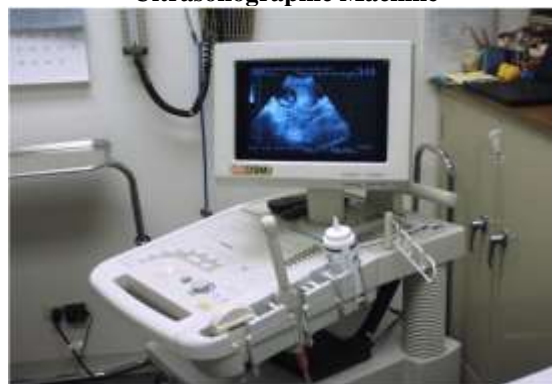Ultrasonography is a tomographic imaging technique that uses ultrasonic sound waves generally in the range of 2 million – 20 million cycles per second (20-20,000 Hz or 2- 20 MHz), well above the frequencies audible to Humans or animals.

The Ultrasound wave is a longitudinal pressure wave made of areas of compression and rarefaction. When transmitted through a medium, it causes the molecules to oscillate in the course of wave propagation.

Simplest manner of depicting a US beam is in the form of a parallel bundle for a certain distance beyond which it disperses. This parallel component is referred to as the Fresnel zone (near-field) and diverging portion is called the Fraunhofer zone (far-field).



Ultrasonographic Machine



A Handheld transducer is applied to the body. The transducer is made up of a special kind of piezoelectric crystal made up of Lead zirconate titanate, which vibrates when stimulated by Electricity. Consequently, an ultrasound transducer converts an electrical signal into mechanical motion and mechanical motion into ultrasound. This transducer both sends ultrasound waves into the body and receives reflected sound waves. The transducer information is communicated through a fibre optic cable to the ultrasound scanner and the data are rendered on a monitor.

A coupling gel is used to help to transmit the ultrasound waves to and from the transducer. Reflection of sound waves occurs at interfaces where there is a difference in the speed of propagation of sound waves and as sound/ ultrasonic waves travel relatively slowly through air, the air-skin interface has the potential to reflect a great deal of the waves used for imaging, Placing ultrasound coupling gel between the skin and transducer greatly reduces the effect and the system is designed so that both the transducer face and the coupling gel have acoustic impedances similar to that of skin.

Commonly used ones are linear probes (bandwidth 3-12 MHz) for small parts, curvilinear or convex probes (1-5 MHz) for obstetrics and abdominal usage and sector or phased-array (3.5-5 MHz) for echocardiography and gynecological uses.

Certain new and more specialized variants are also available now such as the intracavity probes (transesophageal, transrectal, transvaginal), biplane probe, and intravascular probes.

Sound waves encountering a tissue can be attenuated, reflected or transmitted by the tissue. Reflected sound waves returning to the transducer are used by the computer to make an image. Sound is generally reflected when waves travelling in one kind of tissue encounter a different kind of tissue, which has different properties of ultrasound waves propagation. These are called acoustic interfaces.

Regions with many acoustic interfaces reflect a lot of sound returning to the transducer: These are termed echogenic or Hyperechoic and by convention are viewed as Bright areas. Regions with few acoustic interfaces do not reflect many sound waves. These are termed Hyperechoic or dark areas.

Tissue	Reflectiveness (Echogenicity)	Appearance in Ultrasonographic Image
Bone, Cartilage	Hyper echoic	Bright or White
Glandular tissue	Moderately echoic	Moderately Bright
Muscles, Blood Vessels	Hypoechoic	Fairly Dark
Air, Fluids	Anechoic	Dark or Black

Different Imaging Mode Displays available in Ultrasound

A-mode -displays the amplitude of the reflected sound. It is used for measuring the boundaries of tissues of different acoustic properties.

B-mode produces different echogenicity and shows the texture and tissue borders as black and white images. As Ultrasound wave passes through tissues of different acoustic impedance, some are reflected back, and some penetrate deeper. Owing to the wide grey scale used, even very small differences in echogenicity can be visualized.

Motion mode - it is a two-dimensional image that allows recording the motion. It has a high temporal resolution and is valuable in the accurate evaluation of rapid movement's example in the heart.

Doppler mode (D Mode) - this mode is based on the "Doppler effect" which is defined as "the observed changes in the frequency of transmitted waves when relative motion exists between the source of the wave and an observer." This enables the examination of blood flow in vessels on the basis of backscatter from erythrocytes.

Swellings of head and neck region US can be used in establishing the differential diagnosis of cystic or solid masses of the neck, cervical lymphadenopathy. It serves to differentiate benign from malignant masses and intra glandular and extra glandular anomalies of the salivary glands.

Inflammatory swellings

Siegert et al (1987) had initially classified the US appearances of inflammatory swellings into five types edema, infiltrate, pre-abscess, echo-poor abscess, and echo-free abscess.¹³

Edematous changes: The echogenicities of the tissues were isoechoic, similar to the normal or uninfected side but with increase in the fluid contents.

Cellulitis: The echogenicities of the tissues were higher (hyperechoic) than normal because of massive inflammatory infiltration to the infected region.

Pre-abscess stage: The echogenicities of the tissues were mixed (hypoechoic and hyperechoic) at the end of cellulitis stage and the beginning of abscess formation stage.

Abscess stage: The echogenicities of the tissues were absent (anechoic) because of the abscess cavity, which can be solitary or multiple well defined foci of pus.¹³

Assessment of Maxillofacial Space Infections

Cellulitis: Cellulitis is characterised by the diffuse swelling of subcutaneous layer due to edema amidst the fat and connective tissue. The edema in sonographic image of cellulitis appears as well defined hypoechoic septa between fat and connective tissue having a characteristic "cobblestone appearance"

Abscess: The ultrasonographic appearance of abscess is quite variable. It ranges from anechoic to irregularly

Hyperechoic, internal echoes, Hyperechoic sediment, septae or even gas.

Ranges from round and generally well-defined to irregular, lobulated. Squish sign with compression is seen. Ability to induce motion in the material with Palpation/Pressure.¹¹

Necrotising Fasciitis: Layer of anechoic fluid measuring > 4mm, adjacent to the deep fascia. Subcutaneous gas (Acoustic shadowing or reverberation Artifact may be Present. Reverberation artifact occurs when an ultrasound beam encounters two strong parallel reflectors.

When the ultrasound beam reflects back and forth between the reflectors ("reverberates"), the ultrasound transducer interprets the sound waves returning from the reverberation as deeper structures since it took longer for the wave to return to the transducer.^{11,13}

Peritonsillar Abscess (Quinsy): Usually appears as a hypoechoic or heterogeneous mass, though appearance may be variable, Posterior enhancement is commonly seen.

A study conducted by Shankar et al established the reliability and diagnostic efficiency of Ultrasound in head and neck swellings.⁹

The sensitivity and specificity of US in inflammatory swellings was found to be 96.5% and for cystic swellings, swellings of muscular origin, lymphadenopathies, it was 100%. In addition, sensitivity and specificity for benign and malignant neoplasms were 92.86% and 100% respectively.¹¹

For Establishment of Differential Diagnosis of Neck swellings

Cysts appear as an anechoic area due to its fluid/air/gas filled nature. Since liquids are homogeneous, and there are no structures to produce internal echoes, there is little or no attenuation of Ultrasound, which creates enhanced transmission of sound at the distal aspect of cystic mass. If the cyst becomes infected, then the content of the lesion can produce some echoes leading to a hypoechoic area.

For example, branchial cyst and sebaceous cyst classically appear as well defined, homogenous, anechoic, and hypoechoic areas respectively with posterior acoustic enhancement.¹⁶

For evaluation of benign solid neoplasms in the Floor of the mouth

Benign neoplasms of the floor of the mouth include lipomas, benign mixed tumors (pleomorphic adenomas) of the sublingual gland and minor salivary glands, and neural sheath tumors.

Lipomas: The floor of the mouth is the third most common location for lipomas of the oral cavity (after the cheek and tongue). On Ultrasonographic images, lipomas typically appear as oval or ellipsoid, well-defined masses that are usually hyperechoic in comparison with muscle and that usually contain linear

echogenic striations parallel to the skin surface. The absence of calcifications and cystic spaces in these lesions aids in their differentiation from dermoid cysts.⁹

Pleomorphic adenoma appears as rounded, circumscribed and hypoechoic with distal acoustic enhancement.⁹

Hemangioma appears as multiple hypoechoic areas with some amount of vascularity on Doppler study.⁹

Malignant neoplasms: The Ultrasonographic features depend on the grade of the tumor. Low-grade malignant neoplasms appear similar to pleomorphic adenoma and larger lesions present with apparent malignant features such as irregular, poorly defined margins, and heterogeneous internal structure.

In diagnosis of Oral submucous fibrosis

US can be used to demonstrate the number, length and thickness of the fibrotic band.

OSMF shows the increased hyperechoic areas representing the fibrous bands or diffuse fibrosis.

Krithika et al characterized the Ultrasonographic features of the buccal mucosa in the patients with OSMF and observed that the submucosa which appeared hypoechoic in the control group had a significantly increased echogenicity in the case group. Hence concluding that the increased submucosal echogenicity and reduced echo differentiation was present in submucosa and muscle layer in OSMF cases.¹⁰

Color Doppler and spectral Doppler shows the decreased vascularity and peak systolic velocity in the lesional area.

For assessment of muscle thickness

Masticatory muscle hypertrophy is also seen in OSMF patients who can be assessed with US. Chakarvarty et al measured the thickness of masseter muscle by ultrasonography (5-11 MHz) and found it to be increased in OSMF as compared to a control group. Also, the thickness was more during contraction as compared to relaxation in both OSMF patients and normal individuals.¹¹

In the inflammatory muscle, the echogenic bands, which correspond to the internal fascia or tendon of the muscle, are frequently diminished or disappeared.¹¹

For diagnosing Salivary gland diseases

Examination of salivary glands is done by 5-12 MHz wide band Linear Transducers (median frequency 7-7.5MHz or more) is used. In assessment of large tumors and lesions located in deep portions of the glands, 5-10 MHz transducers may be useful. Probes with a median frequency above 10 MHz may be useful in evaluation of internal structure of salivary glands.

Entire salivary glands and all lesions have to be evaluated in at least two perpendicular planes during an ultrasonographic Examination.⁹

Various parameters that can be studied using US includes salivary gland volume, the degree of homogeneity (homogeneous, non-homogeneous), and echogenicity (isoechoic or hypoechoic). A structurally normal salivary gland has a medium gray scale homogeneous echo pattern and the level of echogenicity is higher than that of the surrounding muscles. Multiple anechoic areas are characteristically seen in Warthin's Tumour.⁹

To differentiate the inflammatory, cystic or neoplastic swellings of salivary glands

Submandibular sialadenitis was seen as duct dilation proximal to an obstruction. Acute parotitis was seen as an enlarged hypoechoic gland with coarsening of gland texture and chronic parotitis presented as a coarse, reticulated pattern with multiple, rounded, hypoechoic foci seen within the gland parenchyma.

To detect sialolith or strictures in salivary glands

Salivary gland obstruction presenting with the pain and swelling is found to be commonly associated with sialoliths or strictures. Sialoliths within the gland parenchyma or the duct appear as intense hyperechoic foci with distal acoustic shadowing, except for small stones (<2 mm) that present as a shadow. The duct proximal to the stone sometimes shows the visible dilatation, and even small sialolith can be visualized using Ultrasonographic Imaging.

Obstruction in the absence of sialolithiasis can be attributed to the ductal strictures which can be seen in Ultrasonographic imaging as hypoechoic ducts with tapering along with an enlarged gland.⁹

For Diagnosing Primary Sjogrens syndrome

SGUS also has been used for diagnosing primary Sjogren's syndrome (SS). Cornec et al studied the echo structure of the parotid and submandibular glands bilaterally and graded it from 0 to 4. The gland size was measured, and blood flow to the parotid gland was calculated using Doppler study. Based on their findings, they concluded that the addition of Salivary gland Ultrasonic imaging to the American-European Consensus Group classification criteria for SS increased the sensitivity to 87.0%.¹¹

Evaluation of the size and Vascularity of lymph nodes

Kagawa et al quantitatively evaluated the relationship between vascularity within the lymph nodes and lymph node size on Doppler US images of patients with oral cancer. They conclude that an increase in vascularity was a characteristic Doppler US finding in small metastatic lymph nodes, and as the size increased, blood flow signals got scattered and the scattering index increased.⁷

Assessment of cervical lymph nodes

Pre-operative Ultrasound imaging plays an important role in delineating the surgical treatment plan in malignancies. Normally, the lymph node appears as a homogeneous hypoechoic area with a thin cortex and shows hilar vascularity or largely avascular areas in color Doppler mode.

Reactive lymph nodes are hypoechoic with or without the presence of echogenic hilus whereas neoplastic nodes have indefinite internal or hilar echoes.⁷

In Predicting Metastases from Papillary thyroid carcinoma in the Neck

In a study by Hwang and Orloff, the sensitivity and specificity of US in predicting papillary thyroid carcinoma metastasis in the central neck was estimated to be 30.0% and 86.8%, respectively and in the lateral neck 93.8% and 80.0%, respectively.⁵

For diagnosing erosions of the condylar Head of TMJ

Ultrasonography is of diagnostic value in assessing the erosions of condylar head of TMJ which appears as interruption of echogenicity of condylar surface. Razek et al pointed the importance of realtime High resolution ultrasonic imaging in the diagnosis of extent of anterior disc displacement of articular disc in internal Derangement of TMJ.⁶

To determine Enamel Thickness

Culjat et al (2003) used pulsed Ultrasonic waves that are targeted at Cemento enamel junction to determine the enamel thickness.⁸

Periodontal assessment

Ultrasonographic imaging has emerged as a non-invasive periodontal assessment tool that yields real time information regarding clinical features such as pocket depth, attachment level, tissue thickness, histological change, calculus and bone morphology as well as tooth structure for fracture cracks.^{12,17}

For diagnosis of Mixed Odontogenic lesions of Jaw

Chronic Mixed (solid and cystic) lesions such as ameloblastoma and calcifying Epithelial Odontogenic Tumor (CEOT) can be identified by ultrasonographic imaging as such lesions can cause expansion of the cortical plates causing thinning of cortex that aids in penetration of ultrasonic waves during Ultrasonographic imaging. Keratocystic odontogenic tumors are hypoechoic, because of their dense and thick content. Radicular cysts exhibited anechoic internal echo pattern, with homogeneously distributed internal echoes.

The dentigerous cysts exhibited anechoic to focal hyper-echogenicity with heterogeneously distributed internal echoes.¹⁶

For clinical assessment of squamous cell carcinoma of the base of the tongue

US has gained an importance for squamous cell carcinoma (SCC) involving the base of the tongue which is difficult to assess clinically. US based measurement of Tumor thickness can guide the surgical resection by giving an indication of grade of malignancy.

Yesuratnam et al investigated the correlation between Tumour thickness of SCC of the tongue, obtained by USG and MRI with the histological specimens. They concluded that a high correlation existed thus establishing the utility of Ultrasonic imaging to ascertain pre-operative Tumour thickness.¹⁴

In Phonological research studies for assessment of tongue shape and movements

Ultrasonographic imaging based quantitative assessment of tongue shape and movements has been used in phonological research to aid the speech therapy in compromised patients.¹⁴

For Diagnosis of Vascular anomalies of Head and Neck

Colour Doppler Ultrasonography has also gained popularity in the diagnosis of vascular anomalies of head and neck by obviating the need for biopsies and decreasing the associated risks. It can be used in imaging of vascular tumors such as hemangiomas, lymphangiomas or slow-flow and high-flow vascular malformations.¹⁴

Low-Flow Lesions: Low-flow venous malformations (e.g., cavernous hemangiomas) in the head and neck occur most frequently in the buccal space or the floor of the mouth. The lesions are compressible and have a hypoechoic, heterogeneous appearance with multiple anechoic sinusoidal spaces on Ultrasonographic images. The slowing of flow in a lesion is often undetectable at power Doppler imaging.¹⁴

A common color Doppler presentation of arteriovenous malformation of the tongue is described as a hypoechoic area with lobulated margins with the depiction of feeder vessels as well.¹⁴

Detection of Foreign objects in soft tissues

Ultrasonographic Imaging helps in visualization of the size and form of well-shaped materials such as wood, composite, amalgam and glass.¹⁸

In Implant Dentistry

Ultrasonography proves to be a valuable diagnostic tool for locating submerged dental implants and intraoral measurements of the inferior alveolar canal and floor of the maxillary sinus before dental implant placement¹⁴

Advantages of ultrasound Imaging

1. It is safe as it is free from Ionising radiations.
2. Non-invasive

3. Painless
4. High Patient compliance
5. Cheapest Imaging modality compared to CT, MRI
6. Provides Real time images
7. It is useful to guide several diagnostic and Interventional procedures such as Fine Needle aspiration cytology, aspiration and drainage Procedures.

Disadvantages of ultrasound Imaging

1. Operator dependent. It requires highly trained Persons to operate the equipment and interpret the images. Since, specific, reproducible scan planes aren't available for Ultrasonic imaging, the images are difficult to orient and interpret. The images also suffer from anatomic noise accompanying the inherent noise due to the signal returned to the transducer which makes interpretation of the static and dynamic images challenging.
2. It is of Limited value in the diagnosis of Bowel, chest and smaller intraosseous Bone lesions and diseases of Maxillary sinus as both air and calcium are acoustic obstacles for ultrasound beams to pass through.
3. The Deeper portion of the Parotid gland is difficult to visualize and only partly visualised by ultrasonic imaging because of the acoustic shadow caused by the mandibular ramus lies over the deep lobe of the Parotid gland.
4. Inferiorly Located abscesses can be missed by failure to scan in longitudinal plane.
5. Ultrasound imaging is not helpful in assessing the tumour thickness of the base of the tongue as the Ultrasound Probes cannot contact the lesion when the tumor is located at base of tongue.
6. Ultrasonography do not provide reliable data for detecting infections in the deeper fascial spaces, such as the deeper compartment of the parapharyngeal spaces.
7. Inability of the ultrasound to penetrate bone, therefore it is difficult to visualize the articular disk due to its position i.e. between two hard tissues - temporal bone and condylar Head.
8. Metallic implants, dental fillings and restorations may cause blurring of the image due to artefacts generated by the metal. Reverberations generally occur with strong, superficial reflectors such as calcified structures and metallic objects. A reverberation is two or more equally spaced echo signals at increasing depths, twice the distance as the original signal

Newer Techniques in Ultrasonographic Imaging

Ultrasound – Elastography: US-elastography, a newly developed technique evaluates tissue elasticity by measuring the degree of tissue deformation in response to the application of an external force. This measurement of elasticity is used to differentiate between metastatic

and reactive LN enlargement, as a hypothesis suggests that solid tumor cells differ in their consistency from adjacent normal cells.^{19,20}

3D Ultrasonographic Imaging is another technical advancement that was proposed and patented first in 1987. It involves the transmission of sound waves at different angles and reconstruction of the returning echoes using the complex software to obtain a 3D volume data. Fourdimensional (4D) US is further modified the version of 3D US, in which the fourth dimension of time is added. That is, the images are produced in “real time” thus avoiding the time lag observed with the computer-based reconstructions as is the case with 3D US. 3D/4D US is principally used in obstetrics for fetal anomaly detection, echocardiography for congenital heart defects and neurology to assess the brain development.^{18,19,20}

Colour Doppler Flow Ultrasound Imaging

This technique used to scan blood flow and Blood flow mapping in clinical imaging. Changing Frequency with changing velocity-Doppler effect is used for this purpose. This technique helps to predict tumour vascularity, a parameter to predict active tumor proliferation.¹⁵

Based on the Doppler shift, it uses color coding to delineate the feeder vessels, namely red color for arteries and blue for veins. The arterial or venous nature is defined with a spectral wave pattern that is plotted with time on the X-axis and Doppler frequency on the Y-axis. It is especially of use in vascular tumors and vascular malformations. Other techniques in use are continuous wave Doppler, pulsed wave Doppler, Doppler duplex, and power Doppler.¹⁹

Conclusion

Ultrasonographic imaging is still useful for diagnosing various maxillofacial diseases. The sensitivity and specificity of Ultrasonographic imaging have been proved to an acceptable degree in different situations thus, reinstating the position of Ultrasonography as the imaging modality of choice in a number of clinically perplexing situations. Ultrasonographic Imaging is a continuously progressing technology, and further research should be focused on its clinical applications in the dentomaxillofacial region.

References

1. Vincent LM. Ultrasound of soft tissue abnormalities of the extremities. *Radiol Clin North Am.* 1988;26:131-44.
2. Pach R, Legutko J, Kulig P. History and future directions in ultrasonography. *Pol Przegl Chir* 2012;84:535-45.
3. Baum G, Greenwood I, Slawski S, Smirnow R. Observation of internal structures of teeth by ultrasonography. *Science* 1963;139(3554):495-6.
4. Palou ME, McQuade MJ, Rossmann JA. The use of ultrasound for the determination of periodontal bone morphology. *J Periodontol* 1987;58(4):262-5.
5. Hwang HS, Orloff LA. Efficacy of preoperative neck ultrasound in the detection of cervical lymph node metastasis from thyroid cancer. *Laryngoscope* 2011;121:487-91.
6. Razeq AA, Al Mahdy Al Belasy F, Ahmed MW, Haggag MA. Assessment of articular disc displacement of temporomandibular joint with ultrasound. *J Ultrasound* 2015;18:159-63.
7. Kagawa T, Yuasa K, Fukunari F, Shiraishi T, Miwa K. Quantitative evaluation of vascularity within cervical lymph nodes using Doppler ultrasound in patients with oral cancer: Relation to lymph node size. *Dentomaxillofac Radiol* 2011;40:415-21.
8. Culjat M, Singh RS, Yoon DC, Brown ER. Imaging of human tooth enamel using ultrasound. *IEEE Trans Med Imaging* 2003;22(4):526-9.
9. Shankar VA, Ashwini NS, Kumar G, Babu S. Diagnostic significance of ultrasonography in investigations of swellings of head and neck region: A clinico-imaging study. *Indian J Dent* 2013;4:129-36.
10. Krithika C, Ramanathan S, Koteeswaran D, Sridhar C, Krishna JS, Shiva Shankar MP. Ultrasonographic evaluation of oral submucous fibrosis in habitual areca nut chewers. *Dentomaxillofac Radiol* 2013;42:1-8.
11. Chakarvarty A, Panat SR, Sangamesh NC, Aggarwal A, Jha PC. Evaluation of masseter muscle hypertrophy in oral submucous fibrosis patients - An ultrasonographic study. *J Clin Diagn Res* 2014;8:45-7.
12. Cornec D, Jousse-Joulin S, Pers JJ, Marhadour T, Cochener B, Boisrême-Gastrin S, et al. Contribution of salivary gland ultrasonography to the diagnosis of Sjogren's syndrome toward new diagnostic criteria? *Arthritis Rheum* 2013;65:216-25.
13. Siegert R. Ultrasonography of inflammatory soft tissue swellings of the head and neck. *J Oral Maxillofac Surg* 1987;45(10):842-6.
14. Yesuratnam A, Wiesenfeld D, Tsui A, Iseli TA, Hoorn SV, Ang MT, et al. Preoperative evaluation of oral tongue squamous cell carcinoma with intraoral ultrasound and magnetic resonance imaging-comparison with histopathological tumour thickness and accuracy in guiding patient management. *Int J Oral Maxillofac Surg* 2014;43:787-94.
15. Gianfranco G, Eloisa F, Vito C, Raffaele G, Gianluca T, Umberto R. Color-doppler ultrasound in the diagnosis of oral vascular anomalies. *N Am J Med Sci* 2014;6:1-5.
16. Wiggins R. Oral cavity. In: Harnsberger HR, ed. *Diagnostic imaging: head and neck.* Salt Lake City, Utah: Amirsys, 2004; III-4-6-III-4-48.
17. Bains VK, Mohan R, Gundappa M, Bains R. Properties, effects and clinical applications of ultrasound in periodontics: an overview. *Periodontal Practice Today.* 2008;5:291-302.
18. Yagel S, Cohen SM, Rosenak D, Messing B, Lipschuetz M, Shen O, et al. Added value of three-/four-dimensional ultrasound in offline analysis and diagnosis of congenital heart disease. *Ultrasound Obstet Gynecol* 2011;37:432-7.
19. Oikarinen KS, Nieminen TM, Mäkäräinen H, Pyhtinen J. Visibility of foreign bodies in soft tissue in plain radiographs, computed tomography, magnetic resonance imaging, and ultrasound. An in vitro study. *Int J Oral Maxillofac Surg.* 1993;22:119-124.
20. Marotti J, Heger S, Tinschert J, Tortamano P, Chuembou F, Radermacher K, Wolfart S. Recent advances of ultrasound imaging in dentistry--a review of the literature. *Oral Surg Oral Med Oral Pathol Oral Radiol.* 2013;115:819-832.