

MRI 3D CISS: A Boon for Neuro Imaging

Asha ML¹, Reenu Jose^{2,*}, Chaithanya Reddy³, Lekshmy J⁴, Rajaratanam⁵, Mahesh Kumar⁶

¹Professor & HOD, ²PG Student, ^{4,5,6}Senior Lecturer, Dept. of Oral Medicine & Radiology, ³Professor, Dept. of Public Health Dentistry, Dr. Syamala Reddy Dental College, Hospital & Research Centre, Bangalore

***Corresponding Author:**

Email: cathyjose2@gmail.com

Abstract

The cerebrovascular system plays a key role in supporting the brain by providing oxygen and nutrients. The coupling between neuronal activity and vascular response is controlled by the neurovascular unit (NVU). Dysfunction in the neuronal cells may impair the proper control of vascular responses by the NVU. Magnetic resonance imaging is the most powerful tool available to investigate neurovascular pathologies.

Three-dimensional (3D) constructive interference in steady state (CISS) is a fully refocused steady-state gradient-echo MRI sequence. This sequence is now freely available and is frequently included with MRI to investigate a wide range of pathologies for detailed view of neurovascular anatomy. In oral and maxillofacial region, this has been applied to understand the neurovascular pathology behind diseases like Trigeminal neuralgia, nerve hypertrophy etc. Hence, understanding its basic physics and clinical utility might pave way for further applications in diagnosis of head and neck region.

Keywords: Constructive interference in steady state, Longitudinal magnetization, Transverse magnetization, Central nervous system, Cranial nerves, Neurovascular compression

Introduction

Three-dimensional (3D) constructive interference in steady state (CISS) is a fully refocused T2 weighted steady-state gradient-echo MRI sequence. Fully refocused steady-state sequences have introduced a new era in MR imaging in oral and maxilla facial region^[1]. The interactive evaluation of 3D CISS is very advantageous to delineate the tiny and complex vasculature and adjacent cranial nerves at the ventral and ventro-lateral surface of the brainstem. The imaging of the structures in the base of the skull often creates dilemma due to band artifact caused by the distortion of the main magnetic field. The inherent difference in signal intensity between nerve structures and surrounding fat, and possibility to perform multiplanar and curved reconstructions along individual nerve fibers, makes MRI 3D CISS inevitable in the field of oral and maxillofacial imaging.

Etymology^[2]

CISS is known by different names according to different manufacturers. It is called fast imaging employing steady-state acquisition (FIESTA) by General Electric, true fast imaging with steady-state precession (FISP) by Siemens, balanced fast field echo (FFE) by Philips, and true steady-state free precession (SSFP) by Toshiba.

Physics^[1]

When a patient is placed in a magnet resonance scanner, the randomly moving protons in the body is aligned along the Z axis. And this magnetization force is represented as a vector along the positive side of the Z axis and is called Longitudinal Magnetization (LM). When a radiofrequency (RF) pulse is applied, the LM is

tilted into the transverse plane, is called Transverse Magnetization (TM). The net magnetization is the sum of LM and TM. The same sequence of RF excitations and relaxation is repeated, until a steady state is acquired. This is achieved by keeping the repetition period (TR) shorter than the T2 relaxation times of the tissue^[3]. The decaying signals or residual TM is fed back into LM along with the next RF excitation. Hence it is called 'green sequence'.

In Constructive interference in steady state (CISS), two consecutive runs of three-dimensional (3D) is combined. The first run makes use of alternating pre and post excitation pulses and the second run is performed with constant pulses. The two image sets thus acquired show mutually shifted "banding artifacts." And maximum intensity projection between these two data sets yields the banding artifact free CISS image^[4].

Rationale of 3D CISS in Diagnosis

CISS has become the sequence of choice for evaluating the cranial nerves. This is because of the increased sensitivity of the 3D CISS sequence due to accentuated T2 values between CSF and pathological structures. This is achieved by,

- Using T2 W image and shortening TR
- Increasing the T2 relaxation time.
- Using flip angle of 50°–80°.
- High gradient amplitude and slew rates.
- Using high gradient magnets to reach the peak rapidly.

Applications

1. **Assessment Of Cranial Nerves^[2]:** The studies of cranial nerves (CNs) using CISS were conducted at

the beginning of the 1990s, and the first cranial nerves studied were the facial (CNVII) and vestibulo-cochlear (CNVIII) nerves^[5]. 3D CISS is routinely used for the assessment of cerebello pontine angle (CPA) lesions, inner ear structures and the internal auditory canal (IAC). This can be used for the diagnosis of schwannoma, pulsatile tinnitus or facial spasm and trigeminal neuralgia (TN), tumor of optic nerve origin.

Neurovascular compression (NVC) at the root entry zone (REZ) is the main cause of trigeminal neuralgia^[6]. This compression and displacement of the nerve by the vascular loop is well assessed by the CISS sequence. Even other cause of TN without NVC like arachnoid adhesions at the REZ, nerve atrophy^[7] and neuralgia after herpes virus infection^[8] can also be well appreciated. But for the evaluation of trigeminal ganglion, contrast enhanced CISS is more relevant.

Orbital mass due to tumor of optic nerve or other nerve of orbit^[9] in patients with neurofibromatosis can be clearly delineated with the help of 3D CISS.

2. Evaluation of the Cisternal Spaces and Cavernous Sinus:

Malignancies and infectious processes like granulomas are seen as nodular structures in the cisterns. The intense appearance of this soft tissue mass makes it difficult to evaluate with other imaging sequences. But the accentuated T2 values make 3D CISS classic modality for its evaluation.^[10]

3. Visualization of Vertebrobasilar Aneurysms^[11]:

3D CISS helps to delineate the aneurysmal structures in relationship to the tiny and complex vasculature and adjacent cranial nerves at the ventral and ventrolateral surface of the brainstem.

4. Cysts and Cystic Lesions:

Cyst walls, their extent and margins are clearly depicted on 3D CISS images^[12]. CISS may help to differentiate between a recurrent arachnoid cyst and a postoperative cavity by demonstrating adhesions^[13].

5. Neurocysticercosis:

Identification of the scolex is essential for making a definitive diagnosis of neurocysticercosis and CISS is the best single modality to depict the scolex inside the cysticercus cyst. It has high contrast-to-noise ratio and may also be related to accentuation of the T2 value between the cystic fluid and the surrounding CSF, makes 3D CISS sequence highly sensitive^[13].

6. Hydrocephalus:

Because of high contrast^[14], CISS is an excellent tool for assessing the CSF pathways^[15]. It is capable of delineate minute membranes which may be seen in cases of non-communicating hydrocephalus^[16].

7. Trauma:

CISS should be routinely used in trauma cases to allow accurate visualization of intra-dural nerve roots and detection of pseudomeningoceles in cases of nerve rupture or avulsion. Even though bony defects cannot be assessed, the CSF fluid leakage can be well appreciated in CSF rhinorrhea.

As it's a non- ionizing technique, it can be repeatedly used for follow up studies.

8. **The Vestibular System:** CISS delivers fine detail when imaging the semi-circular canals and otolith organs, which makes it an important tool for the assessment of sensorial hearing loss and also to study the vestibular system.

9. **Assessment of Brain Tumors:** The direction of displacement of the adjacent nerves and vessels gives a clue as to the exact location of the tumor. The visualization of CSF cleft, helps to differentiate extra and intra- axial tumors.

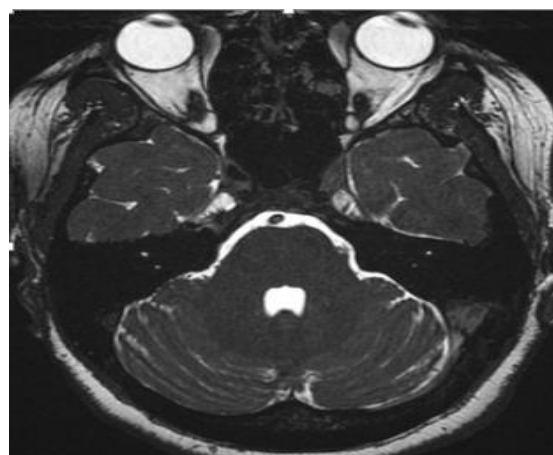
10. **The Spine:** CISS can clearly demonstrate spinal vascular malformations which may show subtle findings on routine sequences. This is because the associated cord signal abnormality is better appreciated on a T2 sequence. Both intra- and extra-medullary cystic abnormalities also can be characterized^[17]. Thus CISS proved to be beneficial in the study of architecture of arterio-venous fistulas, intra-spinal cystic lesions and arterio-venous malformations.

It also plays an important role in identifying the cause and for the precise assessment of brachial plexus involvement in symptomatic cases, in assessment of preoperative work-up of neoplastic conditions or entrapment syndrome, as well as in the assessment of new symptoms that occur in the postoperative situation.

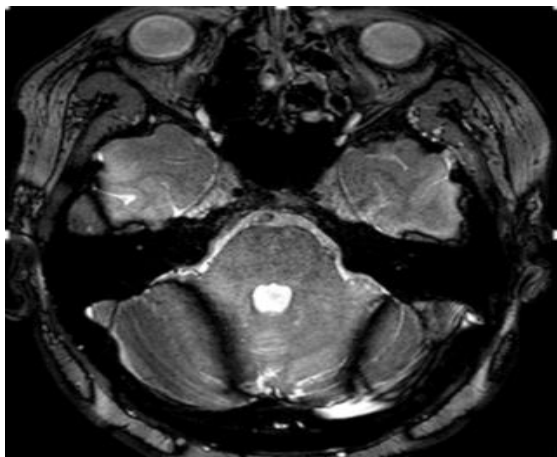Other Clinical Application

It is used in the evaluation of cartilage and meniscal lesions, brain hemorrhages, cardiac imaging to assess the myocardial viability, pericardial diseases and congenital heart diseases, abdominal imaging^[18], fetal imaging (fetal brain^[19]) and interventional imaging for needle path guidance^[20] and study of musculoskeletal system^[21].

Difference between 3D CISS MRI AND 3D MRI



3D CISS MRI



3D MRI

In routine MRI, phase shift error across the image results in banding artifact. Such artifacts are commonly seen in the base of the skull due to distortion in main magnetic field. To overcome this disadvantage of routine MRI, TR and TE values are shortened and alternating and non-alternating excitation pulses are combined. There by obtaining maximum intensity projection, resulting in image which is largely free of dispersion banding.

Advantages

- 3D CISS use short TR and TE and therefore tissues with long T2 relaxation will demonstrate wider range and additional signals due to various refocused echo paths.
- Highest possible signal-to-noise ratio per unit time among all known sequences.
- High spatial resolution and excellent contrast resolution.
- Increased signals and improved speed of acquisition.
- High speed reduces motion or flow related artefacts from respiration and peristalsis.

Disadvantages

- Expensive when compared to conventional MRI scan.
- Slight increased reconstruction time.

Economic Factor & Availability

As it's a modification of routine MRI, it's readily available in all MRI machines. It is compatible with high strength MRI machines, above 1.3 Tesla. 3D CISS MRI is available in most of the established diagnostic centers and its cost ranges from 6000-7500 INR, while routine MRI are cheaper. But considering the diagnostic value, 3D CISS MRI is cost effective^[22].

Conclusion

CISS imaging is useful in the study of CNs, most notably when vascular compression tumors are suspected. With the accentuated T2 values CSF and pathologies can be well appreciated, which makes it a bonus in the field of neuro- imaging.

References

1. Govind B. Chavhan, MD, DNB, et al, Steady-State MR Imaging Sequences: Physics, Classification, and Clinical Applications, Radio Graphics, July-August 2008;28(4):1147-1160.
2. Fabrício Guimarães Gonçalves and Lázaro Luis Faria do Amaral, Constructive Interference in Steady State Imaging in the Central Nervous System European Neurological Review, 2011;6(2):138-142.
3. Hendrick RE. Image contrast and noise. In: Stark DD, Bradley WG, eds. Magnetic resonance imaging, 3rd ed. St Louis, Mo: Mosby, 1999;43-68.
4. Scheffler K, Lehnhardt S. Principles and applications of balanced SSFP technique. Eur Radiol 2003;13:2409-2418.
5. Casselman JW, Kuhweide R, Deimling M, et al., Constructive interference in steady state-3DFT MR imaging of the inner ear and cerebellopontine angle, AJNR Am J Neuroradiol, 1993;14:47-57.
6. Becker M, Kohler R, Vargas MI, Viallon M, Delavelle J. Pathology of the Trigeminal Nerve. Neuroimag Clin N Am 2008;18:283-307.
7. Baechli H, Gratzl O. Microvascular decompression in trigeminal neuralgia with no vascular compression. EurSurg Res. 2007;39: 51-57.
8. Davis LE, King MK. Shingles (herpes zoster) and post-herpetic neuralgia. Curr Treat Options Neurol. 2001;3:401-411.
9. Blaser SI, Smirniotopoulos JG, Murphy FM. Central nervous system manifestations of the phakomatoses. In: Atlas SW, editor. Magnetic Resonance Imaging of the Brain and Spine. 4th ed. Philadelphia, USA: Lippincott Williams and Wilkins, Wolters Kluwer; 2009;274-6.
10. Chang KH, Han MH, Roh JK, Kim IO, Han MC, Choi KS, et al. Gd-DTPA enhanced MR imaging in intracranial tuberculosis. Neuroradiology 1990;32:19-25.
11. Tanrikulu, L., Hastreiter, P., Buchfelder, M. and Naraghi, R. (2016) Three-Dimensional Visualization of Neurovascular Structures in the Posterior Cranial Fossa: A Potential Concept for Microsurgical Considerations in Aneurysms. Open Journal of Modern Neurosurgery, 6, 51-54.
12. Yang D, Korogi Y, Ushio Y, Takahashi M. Increased Conspicuity of Intraventricular Lesions Revealed by Three-dimensional Constructive Interference in Steady State Sequences. Am J Neuroradiol 2000;2:1070-2.
13. Schroeder HW, Gaab MR, Niendorf WR. Neuroendoscopic approach to arachnoid cysts. J Neurosurg 1996;85:293-8.
14. Govindappa SS, Narayanan JP, Krishnamoorthy VM, Shastry CH, Balasubramaniam A, Krishna SS. Improved Detection of Intraventricular Cysticercal Cysts with the Use of Three-dimensional Constructive Interference in Steady State MR Sequences. Am J Neuroradiol 2000;21:679-84.
15. Dincer A, Kohan S, Ozek MM. Is All "Communicating" Hydrocephalus Really Communicating? Prospective Study on the Value of 3D-Constructive Interference in Steady State Sequence at 3T. Am J Neuroradiol 2009;30:1898-1906.

16. Kurihara N, Takahashi S, Tamura H, et al., Investigation of hydrocephalus with three-dimensional constructive interference in steady state MRI, *Neuroradiology*,2000;42:634–8.
17. Gonçalves FG, Neves PO, Jovem CL, et al., Chronic myelopathy associated to intramedullary cysticercosis, *Spine (Phila Pa 1976)*,2010;35:E159–62.
18. Keogan MT, Edelman RR. Technologic advances in abdominal MR imaging. *Radiology* 2001;220:310–320.
19. Chung HW, Chen CY, Zimmerman RA, et al. T2-weighted fast MR imaging with trueFISP versus HASTE: comparative efficacy in the evaluation of normal fetal brain maturation. *AJR Am J Roentgenol* 2000;175(5):1375–1380.
20. Boll DT, Lewin JS, Duerk JL, Aschoff AJ, Merkle EM. Comparison of MR imaging sequences for liver and head and neck interventions: is there a single optimal sequence for all purposes? *AcadRadiol* 2004;11(5):506–515.
21. Hingwala D, Chatterjee S, Kesavadas C, Thomas B, Kapilamoorthy TR. Applications of 3D CISS sequence for problem solving in neuroimaging. *Indian J Radiol Imaging*. 2011;21(2):90–97.
22. Radhika Bestal, Y. UdayShankar2, Ashwini Kumar3, E. Rajasekhar4, S. BhanuPrakash5 MRI 3D Ciss– A Novel Imaging Modality in Diagnosing Trigeminal Neuralgia – A Review, *Journal of Clinical and Diagnostic Research*. 2016 Mar, Vol-10(3):1-3.