

Assesment of sexual dimorphism by morphometric analysis using occlusal radiographic measurements in Kashmiri population

Altaf Hussain Chalkoo¹, Shazia Maqbool², Bashir Ahmed Wani³, Nusrat Nazir^{4*}, Towseefa Jan⁵

¹Professor and HOD, ^{2,3,5}Post Graduate, ⁴Senior Resident, ¹⁻⁴Dept. of Oral Medicine and Radiology, ¹⁻⁵Govt. Dental College, Srinagar, Jammu and Kashmir, India

***Corresponding Author: Nusrat Nazir**

Email: shaziamaqbool786.ss@gmail.com

Abstract

Introduction: Determination of gender not only reflects a social demand, but also aids in medico-legal requirements. During mass fatalities only the part of skull is available for forensic examination. Cases where corpses are beyond recognition, medical/dental records and radiographs help in differentiation of gender. Dental arches analysis by occlusal radiographic measurements can also be used for identification of a person.

Aims: To determine gender by morphometric measurements of dental arches using occlusal radiographic measurements.

Materials and Methods: Sixty standardized occlusal radiographs of 30 males and 30 females in the age range of 20-25 years were taken and traced on a tracing paper. Median line and a line touching vestibular portions of central incisors were drawn. From this intersecting point 'I', a line was drawn to vestibular portion (which represents the most prominent area) of canine, second premolar and second molar on both sides, in both arches, for angular measurements. Linear measurements relative to the width of the arches were made in three segments- in the region of canines, premolars and second molars. The obtained data was statistically analysed.

Result: Only one linear measurement "p-p" were significantly larger in males than in females and only one angular measurement "PIBL" were found statistically significant for gender differentiation.

Conclusion: Linear and angular measurements can be used for gender differentiation in kashmiri population.

Keywords: Dental arches analysis, Forensics, Occlusal radiographic measurements, Sexual dimorphism.

Introduction

Identification of gender is one of the most difficult and most important task in Forensic Medicine and Dentistry. Gender determination of a deceased individual holds social and legal repercussions.^{1,2} Determination of gender is the keystone to establish a biological profile from skeletal remains of the corpses as it reduces possible matches by 50%.³ Nonmutilated remains do not pose much difficulty in identification, but the challenge lies in identifying mutilated body parts when only a part of skeleton or bone is found intact.⁴ Skull is the second most commonly sexed bone for determination of gender as it remains intact in cases of mass destructions.⁵ Among facial bones mandible is commonly found intact bone. Because of its compact nature, it can be used in for sex determination as it expresses strong univariate sexual dimorphism.⁶ Thus, dental arches analysis paves a way for determination of gender.⁷ Search of literature revealed no published studies on gender determination by linear and angular measurements of dental arches by occlusal radiographs in kashmiri population. Therefore, the present study was designed and carried out with the aim of analyzing dental arches for gender determination by using occlusal radiographic linear and angular measurements.

Materials and Methods

In this study 60 subjects were included 30 males and 30 females in the age range of 20-25 years, selected from a population of students by simple random sampling method. Subjects having normal set of complete dentition (class I dentition) and 'U' shaped palate were included in the study. Subjects with compromised dental health like periodontal diseases, morphological tooth abnormalities like attrition, caries etc., h/o tooth extractions/ missing tooth (except third molars), any skeletal abnormalities in maxilla and mandible, gross facial asymmetry, trauma and developmental disorders, h/o surgical orthodontic treatment, and history and clinical features suggestive of endocrinal, hereditary and nutritional disturbances were excluded from the study. After taking the written consent from each patient, standardized occlusal radiographs (30 maxillary and 30 mandibular) were taken on

Technomac dental X-ray machine with 70kVp, 8 mA and 1.2 sec exposure parameters after taking due radiation protection and safety measures.

All the radiographs were traced as shown in Fig. 1 (A) and (B) and the measurements were done as shown in Fig. 2(A) and (B), assigning capital letters to the maxillary arch and small letters to the mandibular arch. Letter L and l, and R and r denote left side and right side of the maxillary and mandibular arches respectively.

Table 1: Showing angular measurements as per gender

Angular Measurement	Male [n=15]		Female [n=15]		P-value
	Mean	SD	Mean	SD	
CIAR	25.20	5.32	26.87	4.98	0.383
PIBR	42.87	2.95	43.60	2.23	0.449
MICR	52.47	2.23	50.80	2.34	0.056
CIAL	27.27	5.09	28.80	3.88	0.361
PIBL	43.40	2.35	45.80	3.08	0.023*
MICL	52.87	2.47	53.07	2.40	0.824
Ciar	20.40	2.97	19.27	4.89	0.45
Pibr	37.53	2.07	38.20	2.78	0.462
Micr	48.13	2.97	48.93	1.28	0.347
Cial	20.60	2.13	19.07	3.58	0.165
Pibl	37.47	2.23	37.07	2.76	0.667
Micl	49.20	1.52	49.93	1.71	0.225

*Statistically Significant Difference (P-value<0.05)

Table 2 showing statistically significant difference among genders for “pp” in mandibular arch.

Table 2: Showing linear measurements as per gender

Linear Measurement	Male [n=15]		Female [n=15]		P-value
	Mean	SD	Mean	SD	
CC	3.73	0.351	3.75	0.261	0.861
PP	5.11	0.349	5.11	0.302	0.956
MM	6.45	0.344	6.24	0.342	0.102
cc	3.21	0.187	3.17	0.215	0.654
pp	4.93	0.238	4.73	0.244	0.031*
mm	6.53	0.144	6.39	0.271	0.104

*Statistically Significant Difference (P-value<0.05)

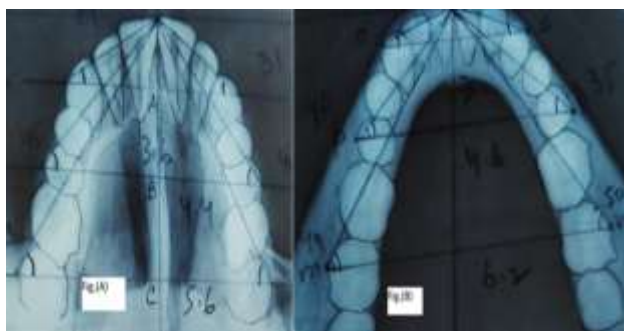


Fig. 1: A,B: showing tracings of standard occlusal radiographs.

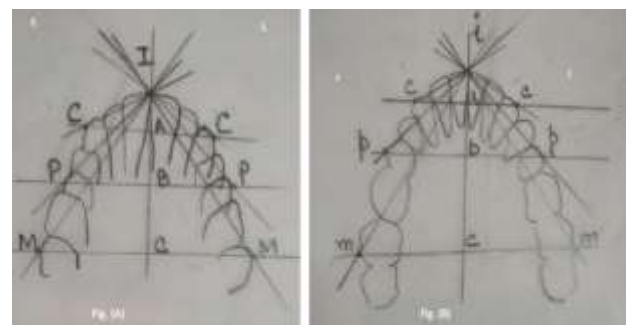


Fig. 2: A,B: showing schematic representation of tracings of occlusal standard radiographs c,p,m,i represents mandibular arch and C,P,M,I represents maxillary arch.

Results

There were 30 males and 30 females in the age range of 20-25 years with a mean age of 22.5 years. Mean and

standard deviation for linear and angular measurements obtained for males and females are presented in Table 1 & 2 respectively. Only one linear variable “pp” showed higher values in males than in females which were found statistically highly significant for gender differentiation. Angular measurement values have shown highly significant differences ($p < 0.05$) between males and females in “PIB L” angle measures only.

Table 1 showing highly statistically significant difference for “PIBL” among males and females in maxillary arch, with females having higher angular measurement value than males.

Discussion

Sex determination is the first step for identification of corpses followed by age and stature estimation as both are sex dependent.⁸ To identify sex in explosions, mass disaster, air hurricanes from mutilated and damaged dead bodies (non living) is the most challenging task for forensic experts.⁹ Gender determination in forensic dentistry plays an imperative role in establishing the biological profile of the deceased individuals.^{5,10} Whenever a mutilated body is found, its identification poses a great challenge to the dentist. Skull is composed of compact bone, due to which it is resistant to destruction and remains intact. In addition to skull, mandible is also the most commonly found intact bone.¹¹ Depending upon the available bones that remains intact and their condition, the methods varies for determination of sex.¹² The pelvis and skull are the most reliable source among human bones as they are usually obtained intact. Mandible is the second most common sexed bone in facial skeleton in absence of complete pelvis because of its durability.¹³ Gender dimorphism is the system for identification of differences in shapes of men and women and allowing more precise search of the dead person's identity.¹⁴ Determination of gender has been carried out by many methods, morphological assessment was considered as oldest approach in forensic odontology and medico-legal cases. Some authors have used linear measurements to determine gender, especially through craniometric measurements,¹⁵ But there are few researches relating to the size and shape of dental arches.. In recent times, sexual dimorphism have been studied with various metric parameters and have been found advantageous and also very reliable in distinguishing gender among different populations.¹⁴ There are only few researches which have been done relating to size and

shape of dental arches. Merz¹⁶ studying the size of dental arches did not find significant differences between genders, which disagrees with this research. Therefore, the synergism of teeth size effect together with the arch shape among genders may contribute to the differences between the studied groups, since Caucasian women usually have smaller teeth and African descent males have the biggest teeth in the dental arches.¹⁷ Based on these data, relation between arch size can vary among genders and ethnical groups, indicating bigger sizes in males, as seen in the present study of linear measures. Therefore, as demonstrated by Dalidjan et al.¹⁸ discordance and a slight relationship between teeth size and arches shape can be observed. There are many variable factors that influence the size of teeth and the shape of arches. Dentofacial complex relationship, the tissue that involves them, occlusion, dental arches variability in shape and genetic component are related to the differences found in the maxilla and mandible.¹⁸ Coronal morphology and permanent teeth sizes usually remains unchanged during growth and development process, except for specific conditions of nutritional abnormality or disorders inherited in other pathological conditions. Thus, odontometry can be used in gender determination. Finally, this is a simple, quick and accurate technique for sexual differentiation, which is always population-specific, allowing gender determination through occlusal radiographs, highlighting the obtained linear and the angular values. Therefore, the present study was undertaken for sex determination from the linear and angular measurements obtained from standard occlusal radiographs. In the present study, all the linear measurements are found non-significant in gender differentiation except “pp” values and for angular measurements only one namely “PIB L” are found highly significant in differentiation of sex. The results of the present study are not in accordance with the results of the study done by Leticia et al¹⁹ in Brazilian population. Relationship between arch size vary among gender indicating bigger sizes in males. Thus, occlusal radiographic measurements paves a way for gender determination.

Conclusion

Comparison between sexes showed that linear and the angular measurements can be used for sexual dimorphism. Among the linear measurements only “pp” showed statistically highly significant sexual

differences and for angular measurements only “PIBL” shows the statistically significant differences. Thus, concludes that the linear and the angular measurements can be used individually as a definitive key in gender differentiation among males and females. Also, it has been concluded from the study that morphometric measurements not only paves way for gender differentiation but the study is also ethnicity and geographic area specific among different individuals.

Conflict of Interest: None.

References

- Borges SR. Sexual dimorphic characteristics. Qualitative variations in facial areas and distances, by means of lateral cephalometric radiographs in white adult. *Rev Bras Odontol* 1977;31:118-27.
- Patil KR, Mody RN. Determination of sex by discriminant function analysis and stature by regression analysis- a lateral cephalometric study. *J Forensic Sci Int* 2005;147(2-3):175-180.
- Scheur L. Application of osteology to forensic medicine. *Clin Anat* 2002;15(4):297-312.
- Rogers TL. Determination of sex of human remains through cranial morphology. *J Forensic Sci* 2005;50(3):493-500.
- Naikmasur VG, Shrivastava R, Mutalik S. Determination of sex in South Indians and Immigrant Tibetans from cephalometric analysis and discriminant functions. 2010;197(1-3):122.e1-6.
- Shamim T. Forensic Odontology. *J Coll Physicians Surg Pak* 2010;20(1):1-2.
- Gupta A, Kumar K, Shetty DC, Wadhwan V, Jain A, Khanna KS. Stature and gender determination and their correlation using odontometry and skull anthropometry. *J Forensic Dent Sci* 2014;6:101-6.
- Scheuer L. Application of osteology to forensic medicine. *Clin Anat* 2002;15:297-312.
- Srivastava PC. Correlation of odontometric measures in sex determination. *J Indian Acad Forensic Med* 2011;32(1):56-61.
- Mathur UR, Mahajan AM, Dandekar RC, Patil RB. Determination sex using discriminant function analysis in young adults of Nashik: A Lateral Cephalometric Study. *J Adv Dent Sci* 2014;2(1):21-5.
- Indira AP, Markande A, David MP. Mandibular ramus: An indicator for sex determination - A digital radiographic study. *J Forensic Dent Sci* 2012;4:58-62.
- Raj JD, Ramesh S. Sexual dimorphism in mandibular ramus of South Indian population. *Actrocom Online J Anthro* 2013;9(2):253-258.
- Hoque MM, Ara S, Begum S. Morphometric analysis of dry adult human mandibular ramus. *Bangladesh J Anat* 2014;12(1):14-16.
- Camps FE. Gradwohl's legal medicine. 3rd ed. Wright and Son: Bristol John; 1976.
- Nascimento Correia Lima N, Fortes de Oliveira O, Sassi C, Picapedra A, Franceschini L Jr, Daruge E Jr. Sex determination by linear measurements of palatal bones and skull base. *J Forensic Odontostomatol* 2012;30:38-44.
- Merz M. Tooth diameters and arch perimeters in a black and white population. *Am J Orthod Dentofac Orthop*. 1991; 100: 53-8.
- Altherr ER, Koroluk LD, Phillips C. Influence of sex and ethnic tooth-size differences on mixed-dentition space analysis. *Am J Orthod Dentofacial Orthop* 2007;132:332-9.
- Dalidjan M, Sampson W, Townsend G. Prediction of dental arch development: an assessment of Pont's Index in three human populations. *Am J Orthod Dentofacial Orthop* 1995;107:465-75.
- Leticia Ferreira dos santos, Rodrigo Galo, Ricardo Henrique Alves da Silva. Gender evaluation in human beings by occlusal radiographs. *Braz J Oral Sci* 2015;14(1):23-26.

How to cite this article: Chalkoo AH, Maqbool S, Wani BA, Nazir N, Jan T. Assesment of sexual dimorphism by morphometric analysis using occlusal radiographic measurements in Kashmiri population, *Int J Maxillofac Imaging* 2019;5(2):34-7.