

## The role of cone beam computed tomography (CBCT) for direct sinus lift in atrophic maxillary posterior region: Report of a case

Priyadarshini Banerjee<sup>1\*</sup>, Rajesh Kshirsagar<sup>2</sup>, Vikrant Sane<sup>3</sup>, Rajat Bhende<sup>4</sup>, Mayur Limbhore<sup>5</sup>, Pratik Warade<sup>6</sup>, Prasamita Mishra<sup>7</sup>

<sup>1,4,5</sup>Post graduate student (MDS III), <sup>2</sup>Professor and Head, <sup>3</sup>Associate Professor, <sup>6,7</sup>Post graduate student (MDS II), <sup>1-7</sup>Dept. of Oral and Maxillofacial Surgery, <sup>1-7</sup>Bharati Vidyapeeth Dental College and Hospital, Pune, Maharashtra, India

**\*Corresponding Author: Priyadarshini Banerjee**

Email: priyadarshinibanerjee29@gmail.com

### Abstract

In the posterior maxilla, unfavourable ridge resorption following dental extractions, sinus pneumatization and poor quality of bone remain areas of concern. It becomes imperative to increase the height of the alveolar bone to facilitate implant placement in such regions. Pre surgical radiographic assessment using Cone Beam Computed Tomography (CBCT) allows the surgeon to plan implant insertion with ease. The article discusses the radiographic evaluation of gain in residual bone height after direct sinus lift technique using CBCT, thereby discussing its versatility and usage.

**Keywords:** Direct sinus lift, Radiographic assessment, Cone beam computed tomography (CBCT)

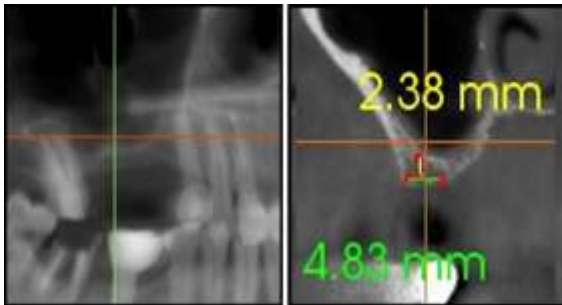
### Introduction

Edentulism is a demotion to one's self confidence. It has a significant impact on the quality of life owing to poor facial aesthetics. The maxillary posteriors remain one of the critical areas due to its proximity to the maxillary sinus. Sinus floor elevation technique is routinely performed to increase the residual bone height in atrophic maxilla with a high clinical success rate. Aggravated dipping of the sinus membrane is particularly noted post extraction. The standard procedure for direct sinus lift involves the placement of bone graft, thereby raising the inferior border of the maxillary sinus.<sup>1</sup> The most commonly associated complication includes perforation of the sinus membrane.<sup>2</sup> The literature holds several studies addressing direct sinus lift techniques, recent advances and associated complications.<sup>3</sup> Currently, the use of CBCT is imperative to evaluate the residual bone height prior to placement of prosthetic implants in the maxillary posterior region at a low effective radiation dose.<sup>4</sup> Orthopantomograms (OPG) lack resolution owing to unequal magnification and geometric distortion.<sup>5</sup> The article discusses the radiographic evaluation of gain in residual bone height after direct sinus lift technique using CBCT, thereby discussing its versatility and usage.

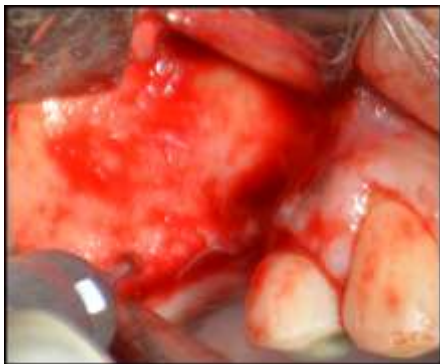### Case Report

A 43 year old male patient reported with an edentulous right maxillary posterior region seeking rehabilitation of the same. On CBCT evaluation, a preoperative residual bone height of 2.38 mm in 16 region was detected (Fig. 1). A conducive treatment plan of direct sinus lift was

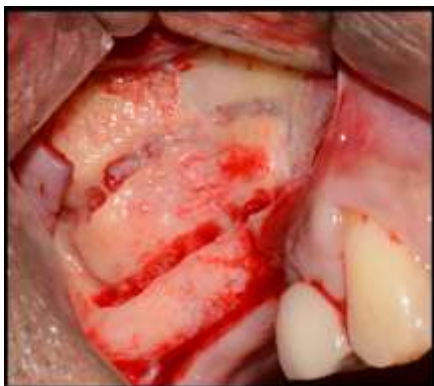planned to augment the residual bone height for implant placement. Prophylactic medications and steam inhalation was advised prior to the procedure. Direct sinus lift was performed following injection of local anaesthesia, raising a mucoperiosteal flap and exposure of the lateral bone pertaining to right maxillary posterior region. Lateral window was created and a synthetic graft material (Demineralized freeze dried bone) was dispensed through the lateral osteotomy site to maintain the elevated sinus membrane lining (Fig. 2a, 2b, 2c). Primary closure was achieved using black silk suture. The buccal and palatal mucosa were undermined to accommodate the collagen membrane. Post operative medications and orders were given to ensure uneventful healing. Suture removal was performed after 8 days upon satisfactory wound healing. At the end of 6 months, a CBCT was advised to evaluate the increase in bone height, which amounted to 9.06 mm 16 region. (Fig. 3) Subsequently, dental implant through crestal approach, measuring 4.5 mm × 9 mm was placed under local anesthesia under strict aseptic protocols. An OPG was advised at the end of 6 months for post operative evaluation (Fig. 4). A comparative charting between the pre and post op OPG showed a residual bone height gain of about 6-7 mm. (Fig. 5)



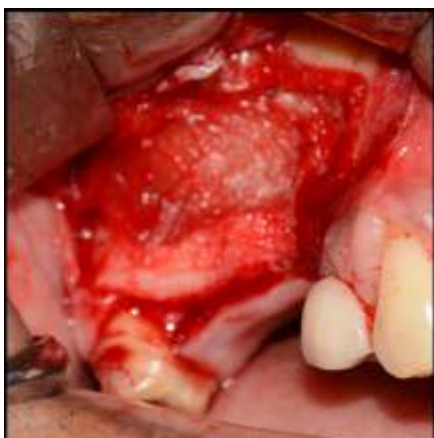**Fig. 1:** Pre Op CBCT showing atrophied maxillary posterior region



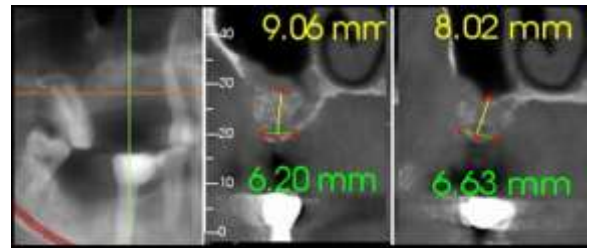
**Fig. 2 a:** Anterolateral wall exposed



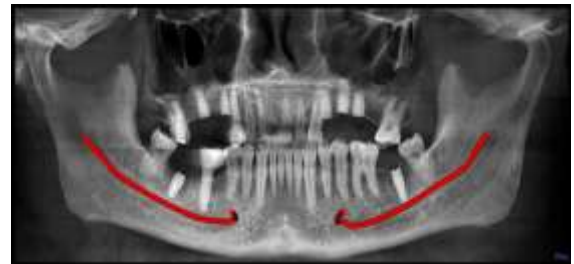**Fig. 2b:** Bony window created



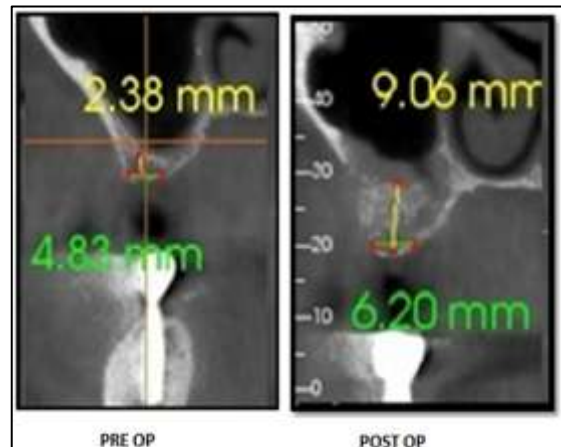
**Fig. 2c:** Maxillary Sinus Exposed, Subsequently Raised And Membrane Placed.



**Fig. 3:** Post Op CBCT after 3 months showing a residual alveolar bone gain of about 6mm



**Fig. 4:** Post Op OPG after Implant Placement



**Fig. 5:** A pre and post operative comparison of residual bone height with a resultant gain of about 6mm.

### Discussion

In the posterior maxilla, unfavourable ridge resorption following dental extractions, sinus pneumatisation and poor quality of bone remain areas of concern. Diminished vertical bone height in the posterior maxillary region hinders implant placement. It is, thus, imperative to increase the height of the alveolar bone to facilitate implant placement. Radiology has a significant role in any minor or major surgical procedure. Pre surgical radiographic assessment allows the surgeon to plan implant insertion with ease. There exists evidence on Cone Beam Computed Tomography (CBCT) generating volumetric data. However, the resolution of CBCT imaging is non isotropic, with limited spatial image resolution in at least one axis.<sup>6</sup> Detailed information

through cross-sectional imaging and 3D assessment using CBCT has become the need of the hour for sinus lift procedure in atrophic maxillae.<sup>7</sup> When panoramic radiographs are used, bone quantity and quality seem to be overestimated. CBCT is superlative since it provides a three dimensional, multi-planar reformatted image with no superimposition of anatomic structures with a high resolution. Low exposure rate of 5-38.3  $\mu$ Sv makes it highly preferable.<sup>8</sup> It is safe to conclude that CBCT has emerged as a reliable and leading diagnostic aid in perioperative planning for dental implants providing a three dimensional assessment.

**Conflict of Interest:** None.

### References

1. Tan WC, Lang NP, Zwahlen M, Pjetursson BE. A systematic review of the success of sinus floor elevation and survival of implants inserted in combination with sinus floor elevation. Part II: Transalveolar technique. *J Clin Periodontol* 2008;35:241-54.
2. Ulm CW, Solar P, Krennmair G, Matejka M, Watzek G. Incidence and suggested surgical management of septa in sinus-lift procedures. *Int J Oral Maxillofac Implants* 1995;10:462-5.
3. Krennmair G, Ulm C, Lugmayr H. Maxillary sinus septa: Incidence, morphology and clinical implications. *J Craniomaxillofac Surg* 1997;25:261-5.
4. Ludlow JB, Ivanovic M. Comparative dosimetry of dental CBCT devices and 64-slice CT for oral and maxillofacial radiology. *Oral Surg Oral Med Oral Pathol Oral Radiol Endod* 2008;106:106-14.
5. Chan HL, Misch K, Wang HL. Dental imaging in implant treatment planning. *Implant Dentistry* 2010;19:288-298.
6. Mischkowski RA, Ritter L, Neugebauer J, Dreiseidler T, Keeve E, Zoller JE et al. Diagnostic quality of panoramic views obtained by a newly developed digital volume tomography device for maxillofacial imaging. *Quintessence Int* 2007;38:763-72.
7. Temmerman A, Hertelé S, Teughels W, Dekeyser C, Jacobs R, Quirynen M. Are panoramic images reliable in planning sinus augmentation procedures. *Clin Oral Implants Res* 2011;22:189-94.
8. Tatum H Jr. Maxillary and sinus implant reconstructions. *Dent Clin North Am* 1986;30:207-29.

**How to cite this article:** Banerjee P, Kshirsagar R, Sane V, Bhende R, Limbhore M, Warade P, Mishra P. The role of cone beam computed tomography (CBCT) for direct sinus lift in atrophic maxillary posterior region: Report of a case. *Int J Maxillofac Imaging* 2019;5(2):41-3.