

## Sialolithiasis of parotid gland with visible facial nerve twitchings – A rare case report with review of literature

Shakuntala Soujanya<sup>1\*</sup>, T. Harshavardhan<sup>2</sup>, Jayakrishna<sup>3</sup> Vinuthna<sup>4</sup>, Prabhakar Rao<sup>5</sup>

<sup>1</sup>Senior Lecturer, <sup>2</sup>Professor, <sup>3</sup>Associate Professor, <sup>4</sup>Assistant Professor, <sup>5</sup>BDS, <sup>1,2</sup>Dept. of Oral Medicine and Radiology, <sup>3-5</sup>Dept. of Dentistry, Government Dental Colleges, Meghna Institute of Dental Sciences, Nizamabad, Telangana, India

**\*Corresponding Author: Shakuntala Soujanya**

Email: shakuntalasoujanya@gmail.com

### Abstract

Parotid sialoliths are very rare and frequent than that of submandibular sialoliths. However, if present they are manifested by group of clinical features such as unilateral swelling, pain whose onset and progression coincides with intake of food, etc. Even-though as there are many availing advanced diagnostic and treatment modalities like Sialoendoscopy, Lithotripsy, etc. still the conventional sialography is considered as a gold standard approach as it is not only cost-effective but also because of its increased specificity. Here we are reporting such a case of sialolithiasis of left parotid gland diagnosed and treated with conventional sialography.

**Keywords:** Painful swelling, Left cheek region, Eye blinking, Facial twitchings, Sialography, Sialolithiasis.

### Introduction

Among the various lesions of oral-facial region we encounter in our day-to-day life as oral physicians, Sialoliths are the most common pathologies which are nothing but the calcareous concretions found in the ducts of the major or minor salivary glands or within the glands themselves. In the year 1983 Shafer has proposed that they are formed as a result of deposition of calcium salts around a central nidus which may consist of desquamated epithelial cells, bacteria, products of bacterial decomposition, or foreign bodies, etc.<sup>1</sup> According to the literature published by Doku and Berkman in 1967 it is thought to be found very rare in children and younger age group showing higher rate of preponderance of occurring in middle-aged adults.<sup>2</sup> Even it was concluded by Blatt in 1962 that the salivary gland most commonly affected is the submandibular gland followed by the parotid, sublingual and minor salivary glands with intra-ductal stones are most commonly occurring followed by intra-glandular stones.<sup>3</sup> However, in this article we are reporting a young female with intra-ductal parotid sialolith formed by a mucous plug accompanied by facial nerve twitching's which are very rare.

### Case Report

A young female of age 23yrs reported to the regular OPD with a chief complaint of swelling on left side of face at the time of taking food from 1month which was insidious in onset gradually progressed, reached the maximum size while taking food and then gradually disappeared with completion of intake of meals, often accompanied with the symptom of pressure in the same region, rapid blinking of lower eye lid and redness of the eye on the same side of face which further aggravates with intake of sour food and the same thing was appreciated on extra-oral examination when the patient was given a candy and asked to eat it along with presence of undulating facial twitchings which disappeared with completion of candy. Further, the intra-oral examination has revealed the presence of decreased salivary flow rate from stensons duct orifice when observed for on the left side. Finally, a sialography has revealed a mucous plug obstruction in the parotid ductal system w.r.t. 27 region and a final diagnosis of Parotid sialolithiasis was done. Later as a part of treatment as the size of plug is few "mm" in diameter, non-surgical management was considered.

Intially, symptomatic treatment was considered where analgesics (Tab acetoaminophen 500mg BID), antibiotics (Tab Augmentin 625 mg BID) were given

along with advising her to take more liquids for hydration and to bite on a lemon to stimulate salivary flow followed by ductal dilatation with lacrimal probe was carried out once in a week for a duration of 3 weeks and finally patient turned up after a month in an absolute asymptomatic condition.

**Case: “Left Parotid silolithiasis”**

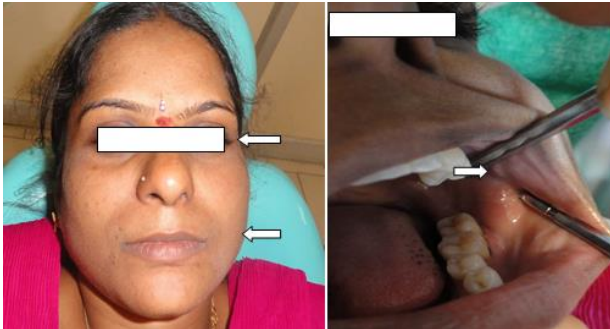

Fig. 1: Clinical examination

**Preliminary radiographs**

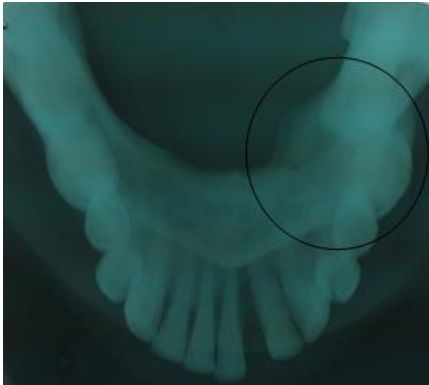

Fig. 2: Occlusal radiograph

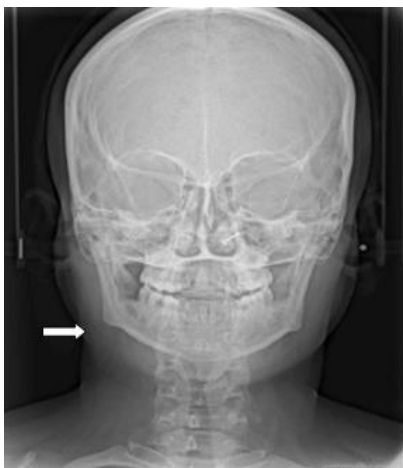


Fig. 3: PA view of skull

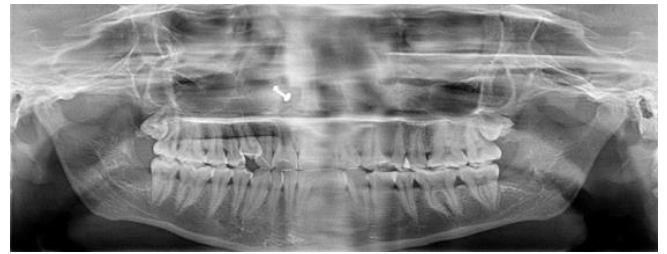


Fig. 4: Orthopentamograph

**Sialography**

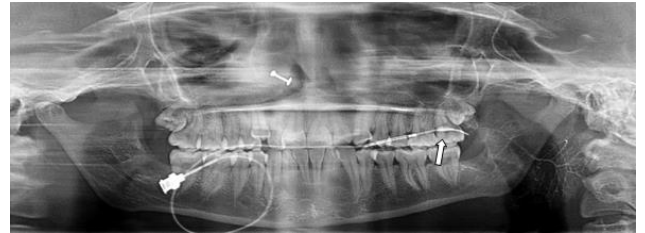


Fig. 5: Orthopentamograph showing mucous plug in the proximal portion of stensons duct

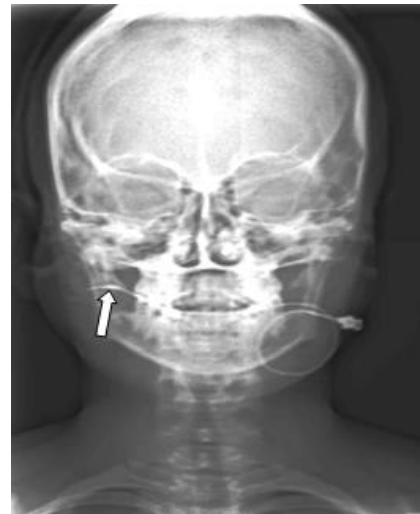
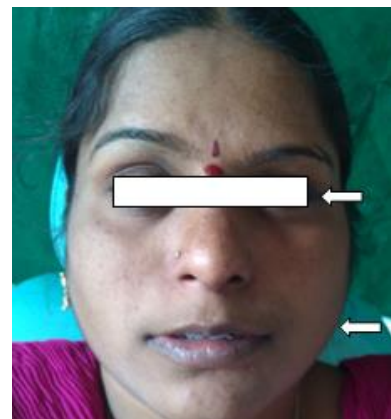
Fig. 6: PA view of skull



Post-Op follow-up photograph

## Discussion

Most of the times patient reports with a chief complaint of intermittent, unilateral pain and swelling associated with eating which subsides thereafter and reoccurs between meals<sup>4</sup>. When clinically if these sialoliths are looked for they appear as yellowish masses of round to ovoid in shape with rough to smooth consistency consisting of mainly calcium phosphate with smaller amounts of carbonates in the form of hydroxyapatite, with smaller amounts of magnesium, potassium and ammonia where Submandibular stones are 82% inorganic and 18% organic and parotid stones are composed of 49% inorganic and 51% organic material. The organic material is composed of various carbohydrates and amino acids.<sup>5</sup>

## Etiopathogenesis

Studies have shown that there is an initial organic nidus which progressively grows by the deposition of inorganic and organic substances or that intracellular microcalculi are excreted in the canal and act as a nidus for further calcification. In some cases, the existence of mucosal plugs acting as a nidus in the ductal system was reported. A possibility of debris, bacteria or substances migrating in the salivary ducts from oral cavity has also been suggested.<sup>6</sup>

## Clinical Features

In the early stages of an obstructed salivary gland, the gland is usually soft and non-tender to palpation. At some point after the onset of obstructive symptoms, secondary infection of the gland occurs. Infection produces a gland that is enlarged and tender to palpation, with the overlying skin often erythematous. Intraorally, the duct is edematous and tender to digital palpation. If the sialolith is located in the anterior third of the duct, digital palpation may reveal its exact location and size and in most instances of an obstructed salivary duct, there will be decreased or absent salivary flow.<sup>7</sup> In 1969, Hall proposed that the presence of purulence in the saliva indicates a bacterial infection.<sup>8</sup>

## Radiographic Features

Even though as there are various clinical and imaging methods available for diagnosing sialoliths, it's the clinical scenario which best enables us in choosing the most accurate salivary gland imaging. Always the occlusal and panoramic views are the most common radiographic techniques used to diagnose sialoliths,<sup>4</sup> however sometimes they cannot be visualized as few of them are hypomineralized and being superimposed by other radiodense tissues demanding for other advanced imaging modalities like ultrasonography and CT.<sup>9</sup>

Ultrasonographic (US) examination is considered as a simple and non-invasive modality to evaluate sialoliths especially during the acute infection. US examination is considered less accurate in comparison to computed tomography (CT) in distinguishing multiple stones. It has also been reported that sialoliths smaller than 3 mm may not be detected during US examination, as they will not produce acoustic shadows.<sup>5</sup>

However, 20% of salivary calculi are radiolucent and can be detected only by sialography providing best visualization of the sialolith in relation to the salivary gland and its duct compared to routine radiography, but should be performed only after the acute infection has resolved (Blatt, 1962).<sup>3</sup> Thereafter, digital sialography and subtraction sialography have increased the sensitivity and specificity of conventional sialographic technique which were considered as the gold standard modalities.<sup>10</sup>

## Differential diagnosis

The differential diagnosis of an unilateral salivary gland swelling includes viral sialadenitis, bacterial sialadenitis, HIV – lymphoepithelial cyst, Sjogrens syndrome, sarcoidosis, malnutrition, salivary gland tumors.<sup>11</sup>

## Treatment and prognosis

Initially symptomatic treatment with antibiotics (penicillin/ erythromycin/ clindamycin) and analgesics followed by instruction to suck on sour lemon or orange candy to stimulate salivary flow (Blatt 1962; Kaban 1990) is considered.<sup>3,12</sup> Later depending on site and size of the sialolith either surgical removal of the

calculus or complete excision of the salivary gland is considered according to the literature published by Reuther and Hausamen in 1976. According to Timosca et al. 1976 if it is located in the anterior third or middle portion of the duct, dilation of the duct and/or sialolithotomy is usually the treatment of choice.<sup>13</sup>

If the calculus is located in the posterior third of the duct or in the gland, treatment consists of sialolithotomy or sialoadenectomy (Reuther and Hausamen 1976; Timosca et al. 1976) where if any attempts to remove a salivary stone may cause damage to the gland resulting in a progressive obstructive disorder of the gland causing irreversible changes, impairing its function and finally sialoadenectomy is indicated.<sup>14, 15</sup>

In the management of large sialoliths which are located in the close proximal duct, extracorporeal shock wave lithotripsy (ESWL) can be considered because of less damage caused by it to the adjacent tissues during the procedure. Similarly Sialadenoscopy is a non-invasive technique that can be used to manage large sialoliths as well as ductal obliteration.<sup>16</sup> Even CO2 laser, because of its advantages of minimal bleeding, less scarring, clear vision and minimal post-operative complications, is gaining its popularity in the treatment of sialolithiasis.<sup>17</sup>

## Conclusion

Finally we conclude that even though there are many treatment approaches for cases of silolithiasis like salivary stimulants, ductal lavage, sialoendoscopy, lithotripsy, etc., surgery remains as the last option and mode of treatment depends on size and site of the sialolithiasis.

## Source of Funding

None.

## Conflict of Interest

None.

## References

1. Shafers text book of Oral pathology, 5<sup>th</sup> Edition.
2. Cornell McCullom III, Cameron Y.S. Lee, David I, Blaustein. Sialolithiasis in an 8-year-old child: case report. PEDIATRIC DENTISTRY: JULY/AUGUST, 1991 VOLUME 13, No.4.
3. Blatt IM: Studies in sialolithiasis. III. Pathogenesis, diagnosis and treatment. *South Med J* 1962;57:723-29.
4. Torres-Lagares D, Parotid sialolithiasis in Stensen's duct. *Med Oral Patol Oral Cir Bucal* 2006;11(1):E80-4.
5. Moghe S, Parotid sialolithiasis. *BMJ Case Rep* 2012. 2012.
6. Kraaij S, Systemic diseases and the risk of developing salivary stones: a case control study. *Oral Surg Oral Med Oral Pathol Oral Radiol* 2015;119(5):539-43.
7. Williams MF. Sialolithiasis. *Otolaryngol Clin NA* 1999;32:819.
8. Hall HD: Diagnosis of diseases of the salivary glands. *J Oral Surg* 1969;27:16-25.
9. Dr. Soumithran C.S1. Parotid Sialolithiasis: A Case Report. *IOSR J Dent Med Sci (IOSR-JDMS)* 2016;15(7):96-100. e-ISSN: 2279-0853, p-ISSN: 2279-0861.
10. Hong KH, Yang YS. Sialolithiasis in the sublingual gland. *J Laryngol Otol* 2003;117:905-7.
11. Moghe S, Pillai A, Thomas S, Nair PP. Parotid sialolithiasis. *BMJ Case Rep* 2012. doi:10.1136/bcr-2012-007480
12. Kaban LB: Salivary gland disease, in Pediatric Oral and Maxillofacial Surgery. Philadelphia: WB Saunders, 1990;189-20
13. Satvinder Singh Bakshi. A Hard Calculus: Submandibular Sialolithiasis. *Am J Med* 2017;130(2).
14. Reuther J, Hausamen JE: Sialolithiasis der glandula submandibularis in kinosalter. *Klin Padiatr* 188:285-88, 1976
15. Timosca G, Gavrilita L, Barna M: La lithiase salivaire chez les enfants, considérations concernant 12 cas. *Rev Stomatol Chir Maxillofac* 1976;77:341-6.
16. Lucas T. Duong et al. Management of anterior submandibular sialolithiasis. *J Oral Med Oral Surg* 2019;25:16
17. Capaccio, P., M. Gaffuri, and L. Pignataro, Sialendoscopy-assisted transfacial surgical removal of parotid stones. *J Craniomaxillofac Surg* 2014;42(8):1964-9.

**How to cite this article:** Soujanya S, Harshavardhan T, Jayakrishna, Vinuthna, Rao P. Sialolithiasis of parotid gland with visible facial nerve twitchings – A rare case report with review of literature. *Int J Maxillofac Imaging* 2019;5(4):99-6.