

## Fabrication of tooth supported overdenture using customized metal short copings: A case report

Jogeswar Barman<sup>1</sup>, Sumeet Bhattacharjee<sup>2\*</sup>, Rubaiya Rahman<sup>3</sup>

<sup>1</sup>Reader, <sup>2,3</sup>PG Trainee, Dept. of Prosthodontics, Regional Dental College, Guwahati, Assam, India

**\*Corresponding Author: Sumeet Bhattacharjee**

Email: [sumeet.bhattacharjee@gmail.com](mailto:sumeet.bhattacharjee@gmail.com)

### Abstract

Overdenture has been a proven mainstay of conservative prosthodontic treatment when proper diagnosis, treatment planning, and most importantly, patient compliance are achieved. Despite recent developments in dental implantology, the conservative approach to root preservation followed by an overdenture is still valid. The many advantages of root retention include- alveolar bone maintenance, better prosthesis support, proprioceptive feedback, aesthetics and psychological benefits. This paper presents a case report of rehabilitation of an edentulous patient with a tooth supported overdenture.

**Keywords:** Short copings, Tooth supported, Overdenture.

### Introduction

Over-denture is a complete or removable partial denture that covers and rests on one or more remaining natural teeth, the root of natural teeth, or dental implants. DeVan's golden statement, "Perpetual preservation of what remains is more important than the meticulous replacement of what is missing," still holds true. Overdenture is one of the most practical measures used in preventive dentistry and can be considered as a better option in comparison with removable complete denture prosthesis in many ways.<sup>1</sup> Over-denture is indicated in patients with few remaining retainable teeth in an arch. Over-denture offers many advantages over conventional complete dentures in terms of preservation of the remaining alveolar supporting-bone along with increased stability, etc. The presence of a healthy periodontal ligament maintains alveolar ridge morphology, whereas a diseased periodontal ligament, or its absence, might be associated with variable but inevitable time-dependent reduction in residual ridge dimensions. Restored retained abutments teeth are frequently endodontically prepared and used as abutments for an over-denture. The objective is to distribute stress concentration through retained abutments and denture-supporting soft tissues.<sup>2,3</sup>

An overdenture requires careful assessment of the inter-occlusal distance. There must be sufficient space for roots, metal copings and possible attachments, together with an adequate thickness of the denture base material and artificial teeth, all without jeopardizing the strength of the denture.

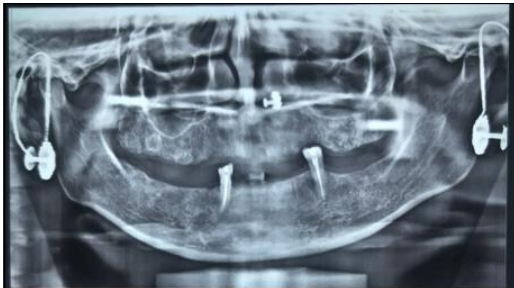
### Case Report

A sixty three years old female patient reported to the Department of Prosthodontics and Crown & Bridge of

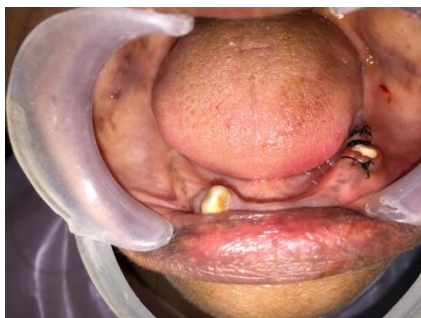Regional Dental College & Hospital, Guwahati, India with chief complaint of difficulty in mastication. On examination, it was found that maxillary arch was edentulous and she was not wearing any denture. In the lower arch, only right canine and left first premolar were left. Both the teeth had sufficient periodontal support. The upper arch was completely edentulous. We decided to preserve the remaining lower teeth and fabricate a tooth-supported over denture for the lower arch along with acrylic complete denture for the upper arch. On her first visit, we took diagnostic impressions; fabricated diagnostic casts then recorded tentative jaw relations and articulated the casts. Interocclusal space between both the arches was found to be 16 mm and it was decided to use short copings. Root canal treatment of both the tooth was done in the lower arch was done during the diagnostic period (Fig. 1). Preliminary Teeth arrangements were done following the orientation lines and principles of teeth arrangement and was decided that left premolar tooth had to undergo crown lengthening procedures.

2gm of amoxicillin 1 hour before the crown lengthening procedure was given on next appointment. Crevicular incision was given with blade no 12 and was extended mesially and distally to the abutment tooth. 3mm of surrounding bone were reduced overall around the tooth and then sutured with 3-0 black silk. The abutment teeth were reduced in vertical height to 2mm above the crest of the ridge. The preparation was rounded to minimize the horizontal torque on the roots (Fig. 2). Antibiotic and analgesics were prescribed to the patient for 1 week after which the suture was removed. The tooth preparation was done to receive copings and the gutta percha was removed

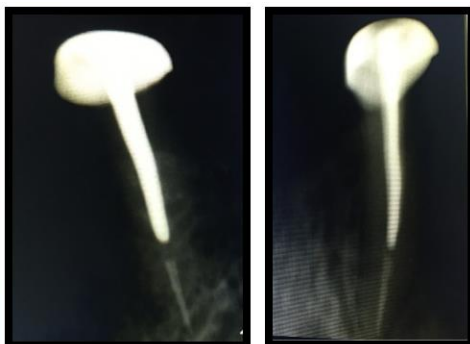with endodontic plugger and peaso reamers. Indirect impression of both the prepared teeth was made with polyvinylsiloxane (DMG, Silagum) and subsequently poured to obtain a cast. Wax pattern was made over the prepared teeth. Metal copings were obtained by casting and cemented over the prepared teeth with Type 1 GIC (Fig. 3). Final impression, with coping in place on their respective abutment was made using a custom tray (Fig. 4). The jaw relation was recorded. Teeth arrangement was made and try-in was done (Fig. 5). Maxillary and mandibular complete dentures were fabricated following the conventional except that the recess was created on the impression surface of the mandibular denture to accommodate the abutments. The dentures were finished, polished and inserted into the patient mouth (Fig. 6). The patient was given instruction about insertion and removal as well as maintenance of the denture. Periodic follow-up was carried out.



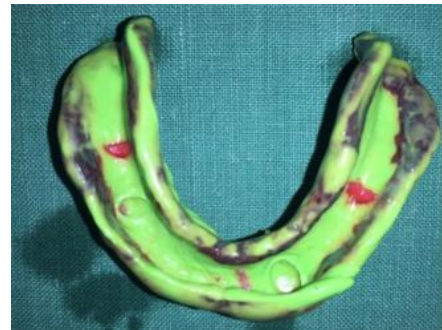**Fig. 1:** Orthopantomogram after completion of root canal treatment



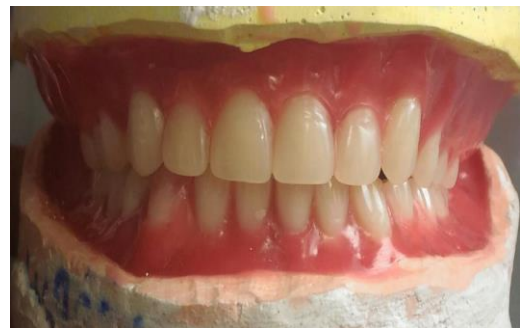**Fig. 2:** Prepared abutment tooth



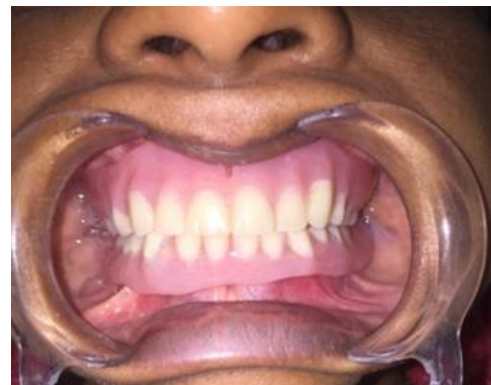**Fig. 3:** IOPA view of cemented copings



**Fig. 4:** Final impression



**Fig. 5:** Teeth arrangement



**Fig. 6:** Finished prosthesis in mouth

**Discussion**

Fabrication of tooth supported over denture is a step in the direction of preventive prosthodontics.<sup>1</sup> The residual ridge reduction with reduced dexterity at advanced age impairs the adaptation to denture prosthesis. The obvious way to prevent denture problems is to save the natural teeth.<sup>2</sup> Healthy teeth with compromised periodontal status can be modified and retained for biomechanical and psychological advantages. This preventive approach can be achieved by means of overdentures.<sup>3</sup> Two most significant factors for the success of the overdenture are proper selection of the patient and establishing careful mode of treatment that will satisfy both the patient and the dentist. According to Zarb et al the advantages of overdentures include retention and stability especially the mandibular dentures.<sup>4</sup> The maxillary

overdenture is of great value when it opposes remaining mandibular anterior teeth, because it aids in conserving the ridge against resorption from masticatory stress.

According to Robert L De franco tooth supported overdenture accomplishes three important goals. It maintains the abutment as a part of the residual ridge which in turn provides more support than a conventional complete denture. When the teeth are retained, alveolar bone integrity is maintained as they support the alveolar bone. However when teeth are removed alveolar bone resorption process begins. With the preservation of the teeth there is also preservation of the periodontal membrane and this in turn preserves proprioceptive impulses resulting in better occlusal awareness, biting forces and consequent neuromuscular control. Rissin et al. in 1978 compared masticatory performance in patients with natural dentition, complete denture and over denture. They found that the over-denture patients had a chewing efficiency one-third higher than the complete denture patients.<sup>5</sup> Additional retention can also be provided in overdenture with help of various attachment systems available depending on the requirements of the clinical case thus adding to improved patient acceptability. But these attachments are costly. In case of bare root overdentures, there are always risks of fracture of the abutment roots.<sup>6</sup>

Root canal therapy is a necessary phase of preparation for the selected teeth; single rooted or double rooted teeth with readily accessible canals are preferred. Teeth that are mobile because of bone loss can become acceptable for overdenture support when the clinical crown is reduced to near ridge height. The short coping design showed least amount of stress than any of the other design. This design minimizes horizontal torque on the roots and provides ease of maintenance of oral hygiene. Various techniques used in the treatment of teeth to serve as abutment for overdenture ranges from simple tooth modification and reduction, tooth preparation with cast coping to endodontic therapy with amalgam plugor cast coping utilizing some form of attachments. Attachments like CEKA attachment can be used but economic reasons sometime restrict their use.

However, if there is requirement of additional retention then variation in design is required. Long copings or attachment can be used to provide additional retention. In the following case report, we have used short metal copings which are comparatively economical solutions as the interarch space were limited. Abutments were prepared in dome shape contour and received cast copings. These dentures provide mainly the preservation of alveolar bone, maintenance of proprioception and stability of prosthesis.

Oral hygiene instructions must be given to the patient and reinforcement of the same has to be done. Recall examinations with radiographs at regular intervals of 6 months or less will maintain the prosthetic, restorative, and periodontal status of the patient at acceptable levels, which in turn leads to the success of the overdenture therapy. Regular fluoride gel application can also be advised for proper maintenance of abutment tooth.

### Conclusion

Tooth supported overdentures are still an excellent and economic therapeutic concept. In this study use of root abutment as an aid to support complete denture is presented. Use of overdentures has been favoured often because of mechanical advantages. Even though the retained teeth may be periodontally compromised, they still may provide sufficient support for the transmission of masticatory pressure and periodontal ligament receptors to initiate a jaw opening reflex. The abutments enhance support and stability of the denture and slow the rate of alveolar resorption. The clinical procedure is straightforward and can be readily applied in general dental practice.

### Source of Funding

None.

### Conflict of Interest

None.

### References

1. Frantz WR. The use of natural teeth in overlay dentures. *J Prosthet Dent.* 1975;34(2):135-40.
2. Pound E. Cross-arch splinting versus premature extraction. *J Prosthet Dent.* 1966;16:1058-68.
3. Crum RJ, Rooney GE. Alveolar bone loss in overdentures: A 5-year study. *J Prosthet Dent.* 1978;40:610-13.
4. Toolson LB, Smith DE. A five year longitudinal study of patients treated with overdentures. *J Prosthet Dent.* 1983;49:149-56.
5. Rissin L, House JE, Manly RS, Kapur KK. Clinical comparison of masticatory performance and electromyographic activity of patients with complete dentures, overdentures, and natural teeth. *J Prosthet Dent.* 1978;39:508-11.
6. Warren AB, Caputo AA. Load transfer to alveolar bone as influenced by abutment design for tooth-supported dentures. *J Prosthet Dent.* 1975;33:137-48.

**How to cite this article:** Barman J, Bhattacharjee S, Rahman R. Fabrication of tooth supported overdenture using customized metal short copings: A case report. *IP Int J Maxillofac Imaging.* 2020;6(1):12-4.