

## Prosthetic rehabilitation of an ocular defect with custom-made ocular prosthesis: A case report

Jogeswar Barman<sup>1</sup>, Rubaiya Rahman<sup>2\*</sup>, Sumeet Bhattacharjee<sup>3</sup>

<sup>1</sup>Reader, <sup>2,3</sup>PG Trainee, Dept. of Prosthodontics, Regional Dental College, Guwahati, Assam, India

**\*Corresponding Author: Rubaiya Rahman**

Email: [rubbyriпти88@gmail.com](mailto:rubbyriпти88@gmail.com)

### Abstract

Ocular prosthesis is artificial replacement of the eye, for patients who have lost an eye as result of trauma or a carcinoma. The loss of an eye can have a physical, social, and psychological impact on the affected person. Prosthetic rehabilitation attempts to restore these disfigurements may improve esthetic, level of function, psychological condition of the patient and ultimately ameliorate the quality of life. This article describes clinical report of rehabilitation of a post ophthalmic enucleation patient with custom made prosthesis using stock eye shell that can create esthetically pleasing result.

**Keywords:** Custom-made, Enucleation, Ocular prosthesis.

### Introduction

“Beauty lies in the eyes of the beholder”. Eyes are the first features of the face one generally notice. It helps us to see and adds to the beauty of the face. The loss of an eye is mostly due to congenital defect, irreparable trauma, tumour, painful blind eye and sympathetic ophthalmia.<sup>1</sup> The disfigurement associated with the loss of an eye can cause significant physical, psychological and emotional problems.<sup>2</sup> Ocular rehabilitation can be traced back to the Egyptian and Roman civilisations where art eyes were manufactured from noble metals and precious stones. The stock glass eyes gained popularity in Germany and other European nations in the eighteenth century. The severe shortage of glass eyes during the Second World War led to the use of dental acrylic resin as an alternative for ocular prosthesis fabrication which was popularized by the United States Naval Schools.<sup>3</sup>

A fundamental objective when restoring anophthalmic socket with an ocular prosthesis is to enable the patient to cope better with the process of rehabilitation.<sup>4</sup> Multidisciplinary management and a team approach are essential in providing accurate and effective rehabilitation and follow-up care for the patient. Therefore, the combined efforts of the ophthalmologist, the plastic surgeon, and the prosthodontist are essential to provide a satisfactory ocular prosthesis.<sup>5</sup>

Prosthetic rehabilitation of a patient is greatly enhanced if an implant is placed in the orbit. However the placement of an ocular implant is not always possible or feasible. Patients in this situation can be treated with a stock prefabricated or custom-made ocular prostheses that have been adapted to accommodate the defect<sup>6</sup>. The close contact of Custom-made ocular prosthesis with the tissue bed improves tissue health

by reducing fluid accumulation in the tissue-prosthesis interface.

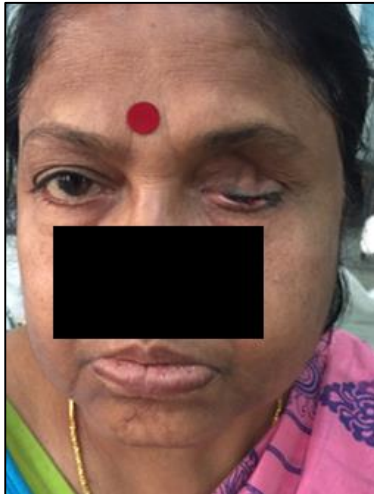This article describes a technique for fabricating a custom-made ocular prosthesis using a conventional method of anophthalmic socket rehabilitation.

### Case Report

A 56-year-old female patient reported to the department of Prosthodontics, Regional Dental College and Hospital, Guwahati, India, with the chief complaint of facial disfigurement due to loss of the left eye (Fig. 1). On taking the history, it was found that the patient had undergone injury of her left eye 4 years back and then diagnosed with painful blind eye for which the eye had to be enucleated at the department of Ophthalmology, Guwahati Medical College, Assam. No ocular conformer or immediate prosthesis was given to the patient.

On examination, socket was completely healed with no inflammation or residual scar formation. The palpebral fissure was examined in open and closed position and found to be normal. The mobility of the posterior wall of the defected eye was normal. There was an inadequate depth of the upper and lower fornices for the retention of the prosthesis, so another surgery was planned to increase the depth of lower fornix.

Considering all factors, we decided to fabricate a conformer immediately after the second surgery to maintain the gained depth, followed by a custom-made ocular prosthesis for the patient.



**Fig. 1:** Pre-operative view

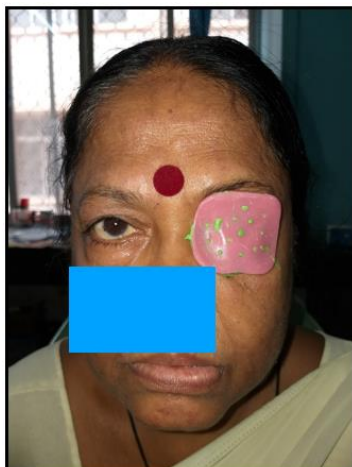### Procedure

The custom-made ocular prosthesis fabrication procedure was done in the following steps:

#### Impression making

An external tray impression technique was used for impression making of the defect. An impression of the facial area corresponding to the defected eye was registered with the help of putty elastomeric impression material (Heraeus Variotime, Kulzer). This impression was used as a template for the fabrication of a custom external tray. Tray extension was again checked in defect eye. 2% lignocaine topical gel was applied to the ocular tissue to reduce the irritability during impression making.

Now polyvinyl siloxane light body impression material (Heraeus Variotime by Kulzer) is slowly injected into the socket and simultaneously extra material is loaded in the custom external tray and placed over the defect (Fig. 2).



**Fig. 2:** External tray impression making

#### Mould making

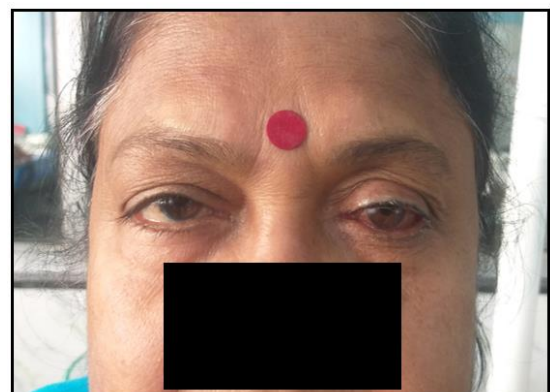The impression was carefully removed and beading and boxing were done (Fig. 3). Impression was poured in two sections in type IV gypsum product (Kalrock, Mumbai, India). The two-piece mold was retrieved from the impression. The mold was coated with a separating medium and melted modeling wax (DPI, India) is poured into the cavity. The mold was opened and the wax was removed. Sharp ridges and undesirable irregularities are eliminated carefully with the help of a wax carver and the surfaces of the wax pattern were made smooth. Wax was added until satisfactory contours of the eyelids were achieved both in open and closed positions.



**Fig. 3:** Impression of the defect

#### Positioning the iris

Size selection of the iris and its positioning was done with Adobe Photoshop, CS version 8 using the contralateral normal eye as a guide. Iris of similar color and size with the patient's right eye was selected from a stock eye shell. Iris was positioned in the wax pattern and tried in the socket (Fig. 4).



**Fig. 4:** Iris positioning

### Flasking and curing

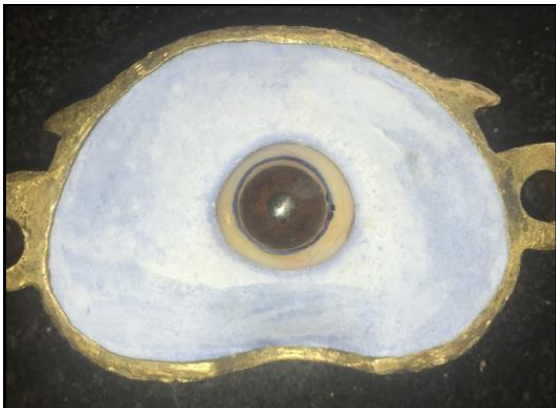
The wax pattern was invested in type IV gypsum products in two sections. Iris was carefully removed and the remaining part was poured in type IV gypsum product. After the dewaxing stone mould was packed with tooth-coloured heat-cured acrylic resin (DPI, Mumbai, India) which simulate the colour of the scleral portion of the normal eye. After curing, the prosthesis was removed carefully and polished.

### Space creation

The iris was repositioned in the prosthesis and then it was tried in the patient's socket. About 1 mm of acrylic was removed from the anterior surface of the prosthesis leaving the iris intact and again re-contoured with modeling wax.

### Characterization

Prosthesis was reinvested and dewaxed. After dewaxing was completed, mould was opened and characterization of the prosthesis was executed (Fig. 5). Characterization was done with the help of camel oil-based water colour and red-coloured streaks of veined heat cure material (DPI, India) to simulate the detailing of the contralateral normal eye.



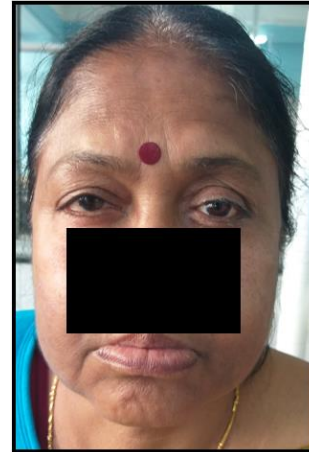**Fig. 5:** Characterization of prosthesis

### Addition of clear layer

The mould with the prosthesis was trial packed with heat cure clear acrylic resin (DPI, Mumbai, India) which will give a natural shiny surface and life-like appearance to the prosthesis afterward. Before final packing extra resin that flowed over the iris due to pressure of trial closer was carefully removed with the help of a sharp scalpel; the mold was closed tightly and allowed to cure slowly over 1 hour.

### Insertion

Prosthesis was inserted into the socket, and checked for any areas requiring adjustment. The esthetics and comfort of the patient were evaluated. The patient was educated to insert and remove the prosthesis (Fig. 6).



**Fig. 6:** Post operative view

### Prosthetic eye care instructions

Following instructions were given to the patient-

1. Never clean or soak your artificial eye with rubbing alcohol because it will crack and destroy the ocular prosthesis.
2. Remove the ocular prosthesis as per instruction and stored it in water or soft contact lens saline solution. This will keep deposits from drying on the surface.
3. To clean your prosthesis, use an antibacterial soap. Wash the eye between your fingertips.
4. Use sterile saline with bulb syringe to rinse out the socket.
5. Any eye drops can be used with the artificial eye in place.
6. Visit at least once a year or more often to have your ocular prosthesis checked, cleaned and polished.

### Discussion

Prosthetic rehabilitation cannot restore the vision but can fulfil aesthetic as well as psychological requirements for a patient. A correctly placed ocular prosthesis should maintain its orientation when the patient is looking straight ahead. It should also restore the normal opening of the eye, support the eyelid, restore a degree movement, be adequately retained and aesthetically pleasing. An accurate impression is necessary for the development of an accurately fitting extraoral prosthesis. Various ocular impression techniques are described in the literature like external impression, impression with a stock or modified stock ocular tray, impression using a stock ocular prosthesis, and the wax scleral blank technique and each has its own integral advantages and disadvantages. In this case, we have used impression with custom external tray, as the detailed and accurate impression of the anophthalmic socket tissue bed can be obtained with this technique and it is an easy procedure to execute.

There are many techniques for fabrication of ocular prosthesis among them stock eye shell, relining a stock shell or custom ocular prosthesis is currently in use. Stock or prefabricated eye prosthesis has certain disadvantages of improper adaptation, compromised esthetic and limited eye movements whereas custom made prosthesis advantages include improved adaptation to underlying tissues, increased mobility of the prosthesis, improved facial contours, and enhanced esthetics gained from control over the size of the iris and pupil, the color of the iris and sclera and a gaze similar to the natural eye.<sup>7</sup> It also involves technical sensitive procedures in various steps of fabrication which are quite difficult and based purely on artistic maneuverability of the maxillofacial prosthodontist. However, a custom prosthesis is more expensive than a stock prosthesis, and several steps are required for its fabrication. The ocular prostheses are produced either from either glass, methyl methacrylate resin or ceramics. Glass is not the material of choice as it is subject to damage and surface deterioration from contact with orbital fluids, leading to a short usable life expectancy.<sup>6</sup> Methyl methacrylate resin is superior to other ocular prosthetic materials with regard to tissue compatibility, aesthetic compatibilities, durability and permanence of colour, adaptability of form, cost and availability.<sup>7</sup> So, PMMA was the material of choice in this case.

In our case, we have used prefabricated iris shell matched with patient contralateral eye and artificial custom made sclera was developed by heat-cure tooth color acrylic resin making it inexpensive and less time-consuming.

Now regarding retention of extraoral prostheses, various methods have been described in the literature; they include tissue undercuts, magnets and osseointegrated implants. Although osseointegrated implant may provide the most reliable prosthesis retention; inadequate bone, additional surgeries and expenses may contraindicate this type of treatment. In the presented case, retention was primarily achieved using anatomic tissue undercut.

## Conclusion

The aesthetic outcome of the custom-made ocular prosthesis was far better than the stock ocular prosthesis. The technique

described in this report represents a straight forward, simple and cost-effective method and results in a more esthetically pleasing and accurate prosthetic outcome. Although the patient cannot see with the ocular prosthesis however, it has definitely restored the patient's self-esteem and allowed him to confidently face the world. The use of ocular prosthesis has changed the patient's social life at a significant level and improved the confidence too.

## Source of Funding

None.

## Conflict of Interest

None.

## References

1. Raflo GT. Enucleation and evisceration. In Tasmun W, Jaeger E (Eds.), *Duane's clinical ophthalmology*, Revised ed, Vol. 5. Philadelphia: Lippincott-Raven, 1995:1-25.
2. Lubkin V, Sloan S. Enucleation and psychic trauma. *Adv Ophthalmic Plast Reconstr Surg*. 1990;8:259-62.
3. Gordon B. The ancient origins of artificial eyes. In: *Annals of Medical History*. 3rd ed., Series 2. New York: Paul B. Hoeber; 1940. p. 58.
4. Ow RKK, Amrith S. Ocular prosthetics: use of a tissue conditioner material to modify a stock ocular prosthesis. *J Prosthet Dent*. 1997;78:218-22.
5. Bartlett SO, Moore DJ. Ocular prosthesis: a physiologic system. *J Prosthet Dent*. 1973;29:450-59.
6. Erpf SF. Comparative features of plastic and/or glass in artificial-eye construction. *Arch Ophthalmol*. 1953;50:737.
7. Cain JR. Custom ocular prosthetics. *J Prosthet Dent*. 1982;48:90-4.

**How to cite this article:** Barman J, Rahman R, Bhattacharjee S. Prosthetic rehabilitation of an ocular defect with custom-made ocular prosthesis: A case report. *IP Int J Maxillofac Imaging*. 2020;6(1):20-3.