



## Case Report

# How does mandible impacted third molar become vertical in young adult

Chen Tie-Lou<sup>1,\*</sup>, Jin Liu<sup>1</sup>, Zhang Xin-Hai<sup>1</sup>

<sup>1</sup>Dept. of Oral Health, Changhai Hospital, Second Military Medical University, Shanghai, China



### ARTICLE INFO

#### Article history:

Received 14-03-2020

Accepted 14-05-2020

Available online 27-07-2020

#### Keywords:

Mandible

Impacted third molar

Vertical

Reason

Pericoronitis

### ABSTRACT

A 21-year-old Chinese woman was referred to our department for the swelling and toothache of the right lower posterior teeth for 2 days. Clinical and Panoramic and CT image examination revealed that the third molar near middle impacted, and the third molar of right maxillary distoangular impacted. We all know that the mandible impacted third molar usually impossible to erupt. However, the right mandible near middle impacted third molar erupted after 7 months. The panoramic image confirmed that the right mandible impacted third molar had become vertical and had good contact with the adjacent second molar. Therefore, reported as a rare case.

© 2020 Published by Innovative Publication. This is an open access article under the CC BY-NC license (<https://creativecommons.org/licenses/by-nc/4.0/>)

## 1. Introduction

Pericoronitis is the most common oral disease in young people due to third molar impacted, and the third molar also caused adjacent dental caries and periodontitis.<sup>1</sup> The eruption of the proximal impacted teeth was not reported. Recently, we encountered the mandible third molars with nearly middle impacted erupted after 7 months, but no obvious abnormality was found in adjacent teeth and periodontal diseases. Therefore, reported as a rare case.

## 2. Case Report

A 21-year-old Chinese woman was referred to the Department of Periodontal, Oral Center of the Affiliated First Hospital of Second Military Medical University for the swelling and toothache of the right lower posterior teeth for 2 days. The patient stated that the discomfort and toothache caused by the eruption of the third molar in the right lower posterior teeth, which was aggravated during eating and brushing. Being a non-smoker, she has no history of systemic diseases and allergies. The clinical examination

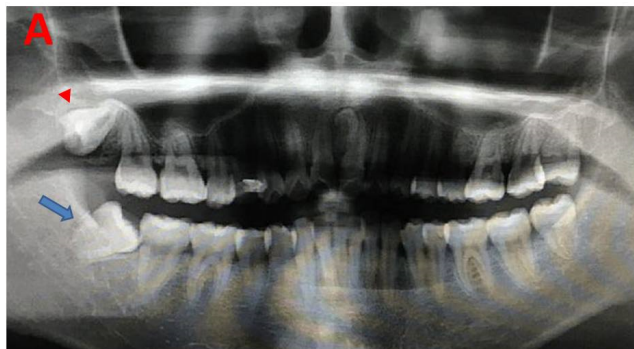
revealed that the third molar was nearly middle impacted, its distal gingival redness, and covered the distal end of the third molar. The opening mouth degree is 2.5cm. The patient diagnosed as third molar pericoronitis according to clinical and micro-computed tomography (CT). CT image showed that the right third molar of mandible was near middle impacted, the right third molar of maxillary distoangular impaction (Figure 1). CT images showed that the mandible third molar was located in the centre between buccal and tongue (Figure 2). The patient was prescribed with metronidazole 200 mg, 3 times a day for 7 days to suppress inflammation. The patient was instructed to rinse his mouth twice daily with 0.12% chlorhexidine mouthwash for 1 week, and the pericoronitis of mandible third molar healed in 7 days.

Interestingly, the patient's right lower impacted third molar was completely eruption and no longer impacted at seven months of clinical examination, and the impacted third molar had good contact with the adjacent teeth. The panoramic image confirmed that the right mandible impacted third molar had become vertical and had good contact with the adjacent second molar (Figure 3). The patient asked for removing the impacted third molar of mandible because the right third molar of maxillary was

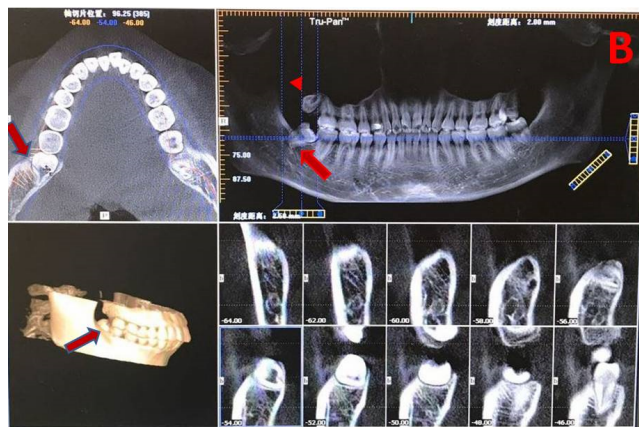
\* Corresponding author.

E-mail address: [chentielou2010@sina.com](mailto:chentielou2010@sina.com) (C. Tie-Lou).

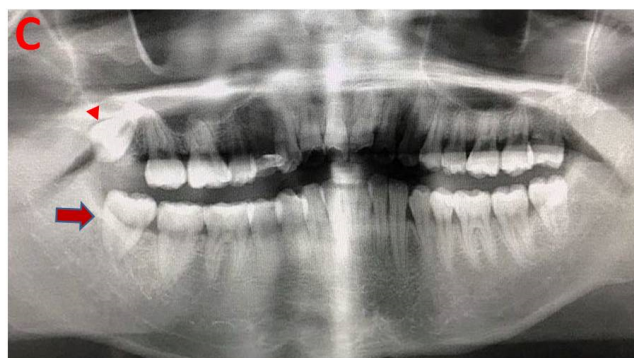distoangular impaction.



**Fig. 1:** Radiograph changes of the right third molar of mandible and maxillary. Panoramic image of Initial consultations, the lower right third molar of mandible was near middle impacted.



**Fig. 2:** CT tomography of Initial consultations, right third molar of mandible located in the centre between buccal and tongue



**Fig. 3:** Panoramic image in 7 months later, the lower right third molar of mandible was vertical. (right mandible third molar arrow, right maxillary third molar arrow)

### 3. Discussion

A longitudinal study of adult third molar eruption for 10 years by Garcia RI<sup>1</sup> and found that 11.7% of the 829 participants had one or more unerupted third molars. In the study, 14 unerupted third molars were extracted, while 11 third molars erupted in 10 subjects. Four of them each had one third molars extracted after eruption, and three of the 11 erupted third molars were in functional occlusion. The positions of four of the 11 erupted "third molars" remained unchanged. Therefore, clinical eruption may be due to a decrease in gingival tissue levels associated with periodontitis at the distal end of the second molar. The eruption of third molars in the elderly seems to be a more frequent. Most of the erupting third molars have caries and periodontitis. Garaas R<sup>2</sup> checked 6 793 patients and found that one third of them had visible third molar disease, and 89 percent had periodontal disease. One fourth of retained and disease-free third molar need to be removed preventively at a young age, whereas the rest should be treated according to signs and symptoms.<sup>3</sup>

Yamaoka M<sup>4</sup> demonstrated that the relationship between the presence of adjacent teeth and the angulation of completely impacted teeth is different between the upper and lower third molar area. The difference might influence the functional occlusion, and should be considered when the impacted teeth are extracted.

As we know, the third molar of the mandible is often impacted, resulting in dental caries, gingival inflammation and pericoronitis in adjacent teeth, and always be extracted. There is no better way to make the impacted third molars vertical, and the cause of the impacted third molars eruption in this case may be related to the patient's abnormal occlusion.

### 4. Source of Funding

Shanghai Health and Family Planning Commission Research Grant (20134418), was also supported by the General Logistics Department Research Grants of CPLA(CHJ13J035).

### 5. Conflict of Interest

None.

### Acknowledgments

The study was sponsored by the Shanghai Health and Family Planning Commission Research Grant (20134418), was also supported by the General Logistics Department Research Grants of CPLA(CHJ13J035).

### References

1. Garcia RI, Chauncey HH. The eruption of third molars in adults: A 10-year longitudinal study. *Oral Surg Oral Med Oral Pathol.* 1989;68:9–13.

2. Garaas R, Moss KL, Fisher EL, Wilson G, Offenbacher S, Beck JD, et al. Prevalence of Visible Third Molars With Caries Experience or Periodontal Pathology in Middle-Aged and Older Americans. *J Oral Maxillofac Surg.* 2011;69(2):463–70.
3. Venta I. How often do asymptomatic, disease-free third molars need to be removed? *J Oral Maxillofac Surg.* 2012;70(9):41–7.
4. Yamaoka M, Furusawa K, Yamamoto M. Influence of adjacent teeth on impacted third molars in the upper and lower jaws. *Aust Dent J.* 1995;40(4):233–5.

**Jin Liu** PhD

**Zhang Xin-Hai** Director & Professor

**Cite this article:** Tie-Lou C, Liu J, Xin-Hai Z. How does mandible impacted third molar become vertical in young adult. *IP Int J Maxillofac Imaging* 2020;6(2):41–43.

## Author biography

**Chen Tie-Lou** Director & Professor