



## Review Article

## Cone beam imaging – an imperative arm in implant planning

Raghunand Sindhe<sup>1,\*</sup>, Aman Deep Sodhi<sup>2</sup>, Vathsala Naik<sup>2</sup>, Sangeetha R<sup>2</sup>,  
Vinod Kumar<sup>2</sup>, Swaroop R Telkar<sup>2</sup>

<sup>1</sup>Dept. of Oral Medicine and Radiology, Yeshaswi Dental Clinic, Bengaluru, Karnataka, India

<sup>2</sup>Dept. of Oral Medicine and Radiology, Bangalore Institute of Dental Sciences, Bangalore, Karnataka, India



## ARTICLE INFO

## Article history:

Received 04-08-2020

Accepted 13-08-2020

Available online 07-10-2020

## Keywords:

Teledentistry

Imaging

Consultations

CBCT

Implant

Radiology

## ABSTRACT

Recently, Dental implants have taken the dental rehabilitation to another level. Dental implants are highly preferred over other rehabilitation techniques, as they have a more conservative approach with minimal damage to other adjacent structures. The aim of the study was to evaluate the prevalence of anatomical variations in maxilla and mandible on CBCT images of patients referred for dental implants. In our study, a total of 102 CBCT images comprising of 60 males & 42 females with mean age of 50 years & 45 years were analysed. We found that in approximately 50% of the cases, the anterior loop of mental nerve was seen and lingual foramen was identified in the anterior part of the mandible in about 20% cases. Two-dimensional radiographs have been used for a long time as the only diagnostic tool in implant dentistry. However, radiographs may seem to be adequate for patients with wide residual ridges but CBCT effectively brings together prosthetic and surgical considerations which are important for beauty, restoration and prosthetic indices.

© 2020 Published by Innovative Publication. This is an open access article under the CC BY-NC license (<https://creativecommons.org/licenses/by-nc/4.0/>)

## 1. Introduction

Recently, Dental implants have taken the dental treatments ablaze especially amongst the urban areas. With the advent of the phenomenon of “Osseo-integration” dental implants has integrated itself as a part of dental rehabilitation. Rehabilitation by dental implants is highly preferred over other rehabilitation techniques as they have a more conservative approach with minimal damage to other adjacent structures which has been the need of the hour since a long time.<sup>1</sup>

Implant placement requires the assessment of many parameters, all of which directly or indirectly affects the treatment outcome and its prognosis. A well planned pre-surgical treatment planning and meticulous execution of the same is the way to achieve the best possible results. Restorative requirements, adequate surgical training, experience in selecting implant system and visualization of

the desired end result of the treatment.<sup>1</sup>

Surgery and Prosthodontic replacement forms the 2 important segments of dental implants. However, the expertise of a maxillofacial radiologist would be necessary for proper interpretation of anatomical structures and or / pathosis in or outside the primary area of interest, which remains the hidden/unrecognized segment of the triangle whose impact is felt at each and every stage of the implant placement.

Even though conventional radiographs (periapical and panoramic radiography) provide adequate information about the vital structures, there are many hidden surprises when assessed through advanced imaging such as CBCT.

The limitations of these traditional diagnostic radiographic modalities include non-uniform magnification, diagnostic restrictions in anterior zone, missing cross-sectional information of the residual alveolar ridge, obscuring bucco-lingual width, angulation and undercuts of the planned implant osteotomy site.<sup>2</sup>

\* Corresponding author.

E-mail address: [rsnhin@gmail.com](mailto:rsnhin@gmail.com) (R. Sindhe).

The arrival of Cone Beam Computed Tomography (CBCT) in the field of dentistry has been supported by a wealth of scientific reports, after which it gained widespread importance & acceptance in the field of dentistry for a variety of applications.

CBCT in comparison with standard radiographic techniques for the evaluation of implant sites have reported improved clinical efficacy of cross-sectional imaging and, more recently published studies have confirmed CBCT as ideal positioning of dental implants. In comparison to CT scans, CBCT allows 3D visualization of Cranio-facial complex, high spatial resolution, less radiation exposure and more cost effective.<sup>3,4</sup>

Dental implant surgery is considered a safe and minimally invasive procedure. However the significance of proper treatment planning cannot be over-emphasized. Critical anatomical landmarks like maxillary sinus, mandibular canal, anterior loop of the mental foramen, adjacent teeth have to be accurately assessed to avoid post-operative complications such as neurosensory disturbances, hemorrhage and perforation of sinus membrane. Also available bone width, height and angulation should be analyzed properly prior to placement of the implant.<sup>5</sup>

Thus the aim of this study was to evaluate the prevalence of anatomical variations in maxilla and mandible on CBCT images of patients referred for dental implants. This paper is a compilation of all cases which looked usual in conventional radiographs but not so when analyzed using CBCT technology, thereby highlight the role of CBCT as a third arm in implant treatment planning, execution and success.

## 2. Materials and Methods

We conducted a retrospective study of patients who had undergone CBCT scan for Implant treatment in the duration of June to July 2017 and reviewed the same for any unusual findings (within and outside the area of interest).

In our study, a total of 102 CBCT images comprising of 60 males & and 42 females with mean age of 50 years & 45 years were analysed. CBCT images were taken by CS 9300 with a standardised FOV 17 x 13.5 cm, 60-90 KV, tube Current of 2-15 mA across all patients

The primary findings in the CBCT scans were limited to the presence of anterior loop of mental nerve, maxillary sinus pneumatization both unilateral and bi-lateral, presence of maxillary sinus polyps, sinus septae and presence of tortuous canals within the sinus cavity. Further, the thickness of the labial cortical plate in the esthetic zone and the bucco-lingual width was also assessed in these images.

In addition to the assessment of the above findings, we also had assessed the patients with pre-surgical radiographic stent, post-surgical grafting and post-surgical implant site.

Based on all the findings, a detailed report was prepared and summarized to reach a conclusive diagnosis.

## 3. Results

In approximately 50% of the cases, the anterior loop of mental nerve was seen and the lingual foramen was identified in the anterior part of the mandible in about 20% cases.

Unilateral sinus pneumatization was found to be unilateral and bilateral in about 30% & 20% cases respectively. The maxillary sinus polyps were present within the sinus cavity in about 22% of the cases, out of which 28% demonstrated tortuous sinus canals, however sinus septae was observed in only about 3% of the scans (Figure 1 )

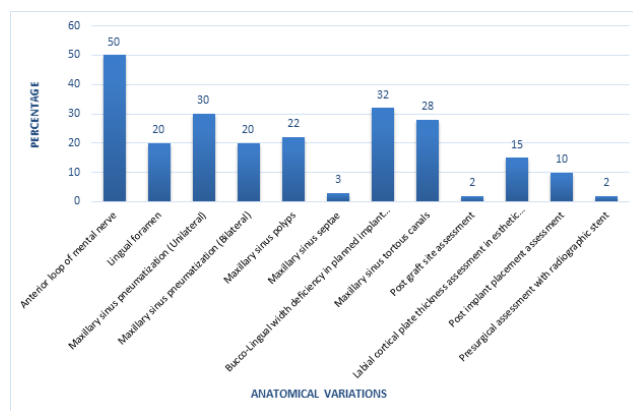


Fig. 1:

A bucco-lingual width deficiency in the planned implant osteotomy site was observed in 32% cases and inadequate labial cortical plate thickness in esthetic zone in 15% scans.

Only 2% of the total scans analyzed were sent with radiographic stent for implant treatment planning. Patients were referred back for CBCT post grafting and after placement of dental implant in 2% and 10% respectively.

## 4. Discussion

Teeth not only have a functional role but also play a very important role in esthetics. Irrespective of the age, socioeconomic status it is imperative for the patient to look for its replacement at its earliest.

The type of replacement depends on many factors like the age, anatomy, functional capacity and the amount of esthetic appeal the person requires. Even though the conventional methods of tooth replacement have been successful, their shortcomings cannot be ignored so easily. Therefore, the advent of implants is on a high ride in today's world as they are more conservative in preserving the adjacent tooth structures and is a standalone structure in the area of replacement.

Implants also have increased chewing efficiency, better proprioception, enhanced esthetics which shout out loud to switch over to place implants over the conventional replacement methods, which is done over the years.

Successful implant placement depends on efficient planning and execution of the same. The most common/primary parameters of evaluation includes the height, width, morphology and density of the residual alveolar ridge height, also the proximity to critical anatomical structures is a must to avoid post-operative complications.<sup>6</sup>

A three - dimensional (3D) information of bone volume and topography prior to implant placement increases the overall success of implant therapy with possible reduction in surgical and postoperative implant complications which means a better prognosis.<sup>7</sup>

CBCT has been recommended as best option for implant imaging by the American Academy of Oral & Maxillofacial radiology (AAOMR) board, recently.<sup>8</sup>

Our study has assessed the anatomical structures in 102 CBCT images retrospectively prior to implant placement and the importance of a well-designed report by the oral and maxillofacial radiologist which has facilitated in the outcome of a successful implant treatment planning and its execution.

The mental nerve is a terminal branch of inferior alveolar Nerve. Anterior loop (AL) of mental nerve is an extension of inferior alveolar nerve which has been shown with anatomic on cadavers and radiologic images in several studies.<sup>9,10</sup>

In our study, AL was identified in 50% of the images, with no gender differences. These results are in accordance to studies by Chun-I Lu et al. 2015 where prevalence ranged from 22-88%, Apostolakis D et al. 2012 in which loop was seen in 48.8% of the scans.<sup>11,12</sup>

Careful assessment of the mental nerve and its Anterior Loop is vital particularly while preparing implants for the inter-foraminal region to elude any neurosensory snags. The risk ranges from 1-7% depending on implant proximity with the nerve. Thus a 2 mm of safety zone is advisable between an implant and the coronal aspect of the nerve.<sup>13</sup>

As a precautionary measure, when the location of the AL of the mental nerve cannot be determined, then placement of the implant at a distance of about 6 mm to the most anterior point of the mental foramen is desirable to elude any neurological complication.<sup>14</sup>

Anterior mandible is a common elective area for placement of dental implant due to its favorable anatomy. However, after tooth loss the resorption pattern of mandible results has a lingual angulated trajectory, which makes implant placement unfavorable. Hence, if the width is not assessed erstwhile by CBCT imaging then it can lead to the perforation of the lingual cortical plate.<sup>15</sup>

Another important anatomical landmark to be acknowledged is the presence of lingual foramen and canals. According to a study by Romanos GE et al. 2012, panoramic radiograph can detect only 2.7% of lingual foramen.<sup>16</sup> However, incidence reported on CBCT ranges from approximately 85-100% according to studies by

Makris N et al., Kusum CK et al., Denny CE et al.<sup>17-19</sup>

In the present study a low incidence of 45% was observed. One possible interpretation for this disagreement could be the imaging technique used. The thickness cut was set to 0.5 mm in the current study with an interval of 0.5 mm between the cuts unlike the 1 mm thickness used which masks smaller bony structures. Also differences could be attributed to racial and ethnic origin.

Any misdirection of the osteotomy drill can lead to damage to lingual and sub-mental artery leading to fatal upper airway obstruction due to hemorrhage. One of the major uses of CBCT is pre-surgical implant planning. Two dimensional radiographs cannot provide information of the residual ridge height and width. This is an important parameter in implant treatment planning as the existing ridge governs the diameter of the implant selected.

32% of CBCT studied had inadequate ridge width and 15% with insufficient labial cortical plate thickness. Unaccounted data prior to surgery, can lead to the most common complication such as fracture of the cortical plates with subsequent exposure of the implant threads ultimately leading to implant failure.

Labial cortical plate can cause esthetics problems, especially in the anterior zone. Hence, it is necessary to include hard and soft tissue grafting procedures in the treatment plan to avoid any future complications. Therefore, Cross-sectional images are very valuable in the design phase before surgery.<sup>20,21</sup>

Out of the 102 CBCT images scanned, 2% were referred for implant treatment planning with a radiographic stent. Radiographic markers can be slot in at the time of the scan, thus providing important radiographic landmarks that can be used to correlate the proposed clinical location and angulation of implants with the available alveolar bone.

CBCT scans have DICOM (Digital Imaging and Communications in Medicine) compatibility. With the help of DICOM data, computer generated surgical guides (stereolithographic models) can be fabricated which helps the surgeon place implants in their optimal and exact position.<sup>22</sup>

Periodontal regeneration has become an integral part of implant therapy. 2% of the scans were for evaluation of the bone post grafting. Thus CBCT provides us with information of the grafted site without making the patient go through surgical re-entry.

Also post-implant assessment, CBCT is more valuable than routine radiological techniques. Approximately 10% cases were referred for second CBCT after implant placement.

## 5. Conclusion

Two-dimensional radiographs have been used for a long time as the only diagnostic tool in implant dentistry. Though traditional radiographs may seem to be adequate for patients

with wide residual ridges that exhibit sufficient residual bone anatomical variations can surprise us and lead a visibly simpler case to failure.

CBCT, has the capability to reconstruct a three dimensional model of the maxilla and mandible which helps identify critical anatomic structures accurately for precise placement of dental implants with minimal complications. The high-quality diagnostic images provided by CBCT follow the ALARA (As Low As Reasonably Achievable) principle. CBCT effectively brings together prosthetic and surgical considerations which are important for beauty, restoration and prosthetic indices.

Also the report from Oral and Maxillofacial Radiologist may be very crucial before entering into the no see zone and is an Imperative arm in Implant Planning.

## 6. Source of Funding

None.

## 7. Conflict of Interest

None.

## References

- Hochman MN, Chu SJ, Tarnow DP. Maxillary anterior papilla display during smiling: A clinical study of the interdental smile line. *Int J Periodontics Restorative Dent.* 2012;32:375–83.
- Pande SP, Kumbhare SP, Parate AR. Incidental findings on cone beam computed tomography: Relate and relay. *J Indian Acad Oral Med Radiol.* 2015;27(1):48–54.
- Deeb G, Antonos L, Tack S, Carrico C, Laskin D, Deeb JG. Is Cone-Beam Computed Tomography Always Necessary for Dental Implant Placement? *J Oral Maxillofac Surg.* 2017;75(2):285–9.
- Patcas R, Tausch D, Pandis N, Manestar M, Ullrich O, Karlo CA, et al. Illusions of fusions: Assessing cervical vertebral fusion on lateral cephalograms, multidetector computed tomographs, and cone-beam computed tomographs. *Am J Orthod Dentofacial Orthop.* 2013;143(2):213–20.
- Kumar V, Sathesh K. Applications of Cone Beam Computed Tomography (CBCT) in Implant Treatment Planning. *JSM Dent.* 2013;1(2):1008.
- Jaju P, Svama PV. Pre evaluation of implant site by denta scan. *J Dental implants.* 2011;1(2):63–74.
- Bagga MB, Jindal S. Role of CBCT in Dental Implants: Current perspectives. *J Periodontol Med Clin Pract.* 2016;03:45–50.
- Tyndall DA, Price JB, Tetradis S, Ganz SD, Hildebolt C, Scarfe WC. Position statement of the American Academy of Oral and Maxillofacial Radiology on selection criteria for the use of radiology in dental implantology with emphasis on cone beam computed tomography. *Oral Surg, Oral Med, Oral Pathol Oral Radiol.* 2012;113:817–26.
- Li X, Jin ZK, Zhao H, Yang K, Duan JM, Wang WJ. The prevalence, length and position of the anterior loop of the inferior alveolar nerve in Chinese. *Surg Radiol Anat.* 2013;35(9):823–30.
- Jalili MR, Esmacelinedjad M, Bayat M, Aghdasi MM. Appearance of anatomical structures of mandible on panoramic radiographs in Iranian population. *Acta Odontol Scand.* 2012;70(5):384–9.
- Apostolakis D, Brown JE. The anterior loop of the inferior alveolar nerve: prevalence, measurement of its length and a recommendation for interforaminal implant installation based on cone beam CT imaging. *Clin Oral Implants Res.* 2012;23(9):1022–30.
- Filo K, Schneider T, Locher MC, Kruse AL, Lübbers HT. The inferior alveolar nerve's loop at the mental foramen and its implications for surgery. *J Am Dent Assoc.* 2014;145(3):260–9.
- Greenstein G, Tarnow D. The Mental Foramen and Nerve: Clinical and Anatomical Factors Related to Dental Implant Placement: A Literature Review. *J Periodontol.* 2006;77(12):1933–43.
- Benavides E, Rios HF, Ganz SD, An CH, Resnik R, Reardon GT. Use of cone beam computed tomography in implant dentistry: The international congress of oral implantologist consensus report. *Implant Dent.* 2012;21:78–86.
- Gakonyo J, Butt F, Mwachaka P, Wagaiyu E. Arterial blood supply variation in the anterior midline mandible: Significance to dental implantology. *Int J Implant Dent.* 2015;1(1):24–30.
- Romanos GE, Papadimitriou DEV, Royer K, Stefanova-Stephens N, Salwan R, Malmström H, et al. The Presence of the Mandibular Incisive Canal. *Implant Dent.* 2012;21(3):202–6.
- Binnal A, Denny EC, Jindal R. Anatomic Variation in Lingual Foramen: A Cone beam Computed Tomography Study. *World J Dent.* 2016;7(4):179–81.
- Makris N, Stamatakis H, Syriopoulos K, Tsiklakis K, Stelt PFVD. Evaluation of the visibility and the course of the mandibular incisive canal and the lingual foramen using cone-beam computed tomography. *Clin Oral Implants Res.* 2010;21(7):766–71.
- Indrajeet, Kusum CK, Mody PV, Nooji D, Rao SK, Wankhade BG. Interforaminal hemorrhage during anterior mandibular implant placement: An overview. *Dent Res Jo.* 2015;12(4):291–300.
- Shokri A, Khajeh S, Falah-Kooshki S, Ostovarrad F, Karimi A, Khavid A. Assessment of dental implant site dimensions in cone beam computed tomography systems. *Braz Dent Sci.* 2014;17(3):74–82.
- Safi Y, Vasegh Z, Kadkhodazadeh M, Hadian H, Bahemmat N. Different methods to evaluate mandibular alveolar ridge in Cone Beam Computed Tomography images in pre-implant surgery assessments. *Int J Medl Re Health Sci.* 2016;5:134–42.
- Nagarajan A, Namasivayam A, Perumalsamy R, Thyagarajan R. Diagnostic Imaging for Dental Implant Therapy. *J Clin Imaging Scie.* 2014;4(2):4.

## Author biography

**Raghunand Sindhe** Dentist

**Aman Deep Sodhi** Reader

**Vathsala Naik** Professor and HOD

**Sangeetha R** Senior Lecturer

**Vinod Kumar** Dentist

**Swaroop R Telkar** Reader

**Cite this article:** Sindhe R, Sodhi AD, Naik V, Sangeetha R, Kumar V, Telkar SR. Cone beam imaging – an imperative arm in implant planning. *IP Int J Maxillofac Imaging* 2020;6(3):49-52.