



Case Report

Treatment of Class II div.1 malocclusion with impacted mandibular canine: A case report

Rashi Yadav^{1,*}, Bhavesh Kothari¹, Kamlesh Garg¹, Parmender Vaidik¹, Bhakti Rajdev¹, Tulip Chakravarty²

¹Dept. of Orthodontics and Dentofacial Orthopaedics, Pacific Dental College and Hospital, Udaipur, Rajasthan, India

²Dept. of Public Health Dentistry, Pacific Dental College and Hospital, Udaipur, Rajasthan, India



ARTICLE INFO

Article history:

Received 25-06-2020

Accepted 26-06-2020

Available online 07-10-2020

Keywords:

Class II malocclusion

Premolar extraction

Impacted mandibular canine

ABSTRACT

Class II malocclusion in nongrowing patient is a great challenge in treatment. Class II div. 1 malocclusion can be the result of a retrognathic mandible, a prognathic maxillary or both. The present article discussed a case of 17 year old female patient presented with Proclined upper anterior, crowding in lower anterior, impacted mandibular canine with increased overjet and overbite, treatment was initiated using fixed orthodontic appliances followed by extraction of upper 1st premolar and retained deciduous teeth and exposure of impacted canine. Case was finished with good intercuspation of upper and lower teeth, ideal overjet and overbite were obtained.

© 2020 Published by Innovative Publication. This is an open access article under the CC BY-NC license (<https://creativecommons.org/licenses/by-nc/4.0/>)

1. Introduction

Patient suffering from class II malocclusion are usually affected by their problem which make them the most common cases that seek orthodontic treatment. Angle's class II div 1 malocclusion usually characterized by maxillary protrusion and /or mandibular retrusion.¹ This is usually accompanied by protrusion of upper anterior teeth, narrow upper arch and incompetent upper lip in non growing patient, this malocclusion can be treated by 1 of 2 methods – orthodontic camouflage which usually involves extraction of upper premolars or even upper and lower premolar or orthognathic surgery to reposition the mandible and /or maxilla in normal position.²

2. Case Report

A 17 years old female patient with chief complaint of forwardly placed upper front teeth. Patient had no medical history, dental history of restoration w.r.t. 36 and 46. Extraoral examination showed that patient

had convex profile and incompetent lips, 100% incisor exposure on smile and patient had gummy smile of 4mm. Intraoral examination revealed class II molar and canine relation, crowding in lower anterior with an Overjet of 15mm, overbite of 7mm, missing 43, retained deciduous w.r.t. 83, crossbite w.r.t. 17,47 cephalometric examination showed skeletal class II jaw base relationship with retrognathic mandible (SNA- 79, SNB-76, ANB- 3), Hypodivergent growth pattern (Go-Sn- Gn -27, FMA-22), Proclined upper incisor. OPG revealed an impacted 43.

3. Treatment Objectives

1. Correction of Proclined upper anteriors.
2. Correction of gummy smile.
3. Relieving lower anterior crowding.
4. Achieving class I canine relation.
5. Extraction of retained deciduous teeth 83.
6. Surgical exposure of 43.
7. Correction of posterior crossbite w.r.t 17, 47.
8. Achieving normal Overjet and overbite.
9. Achieving balanced soft tissue profile.

* Corresponding author.

E-mail address: rashi26yadav@gmail.com (R. Yadav).

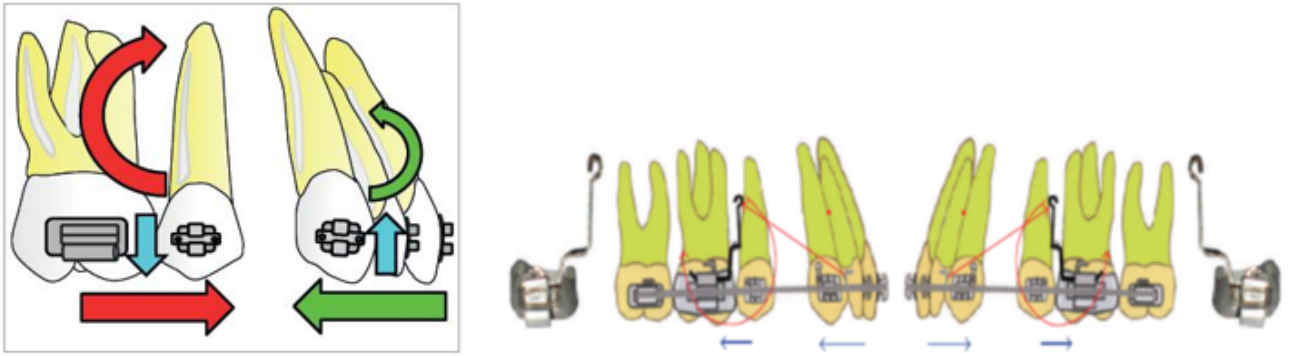


Fig. 1: Power arm based intrusion and retraction

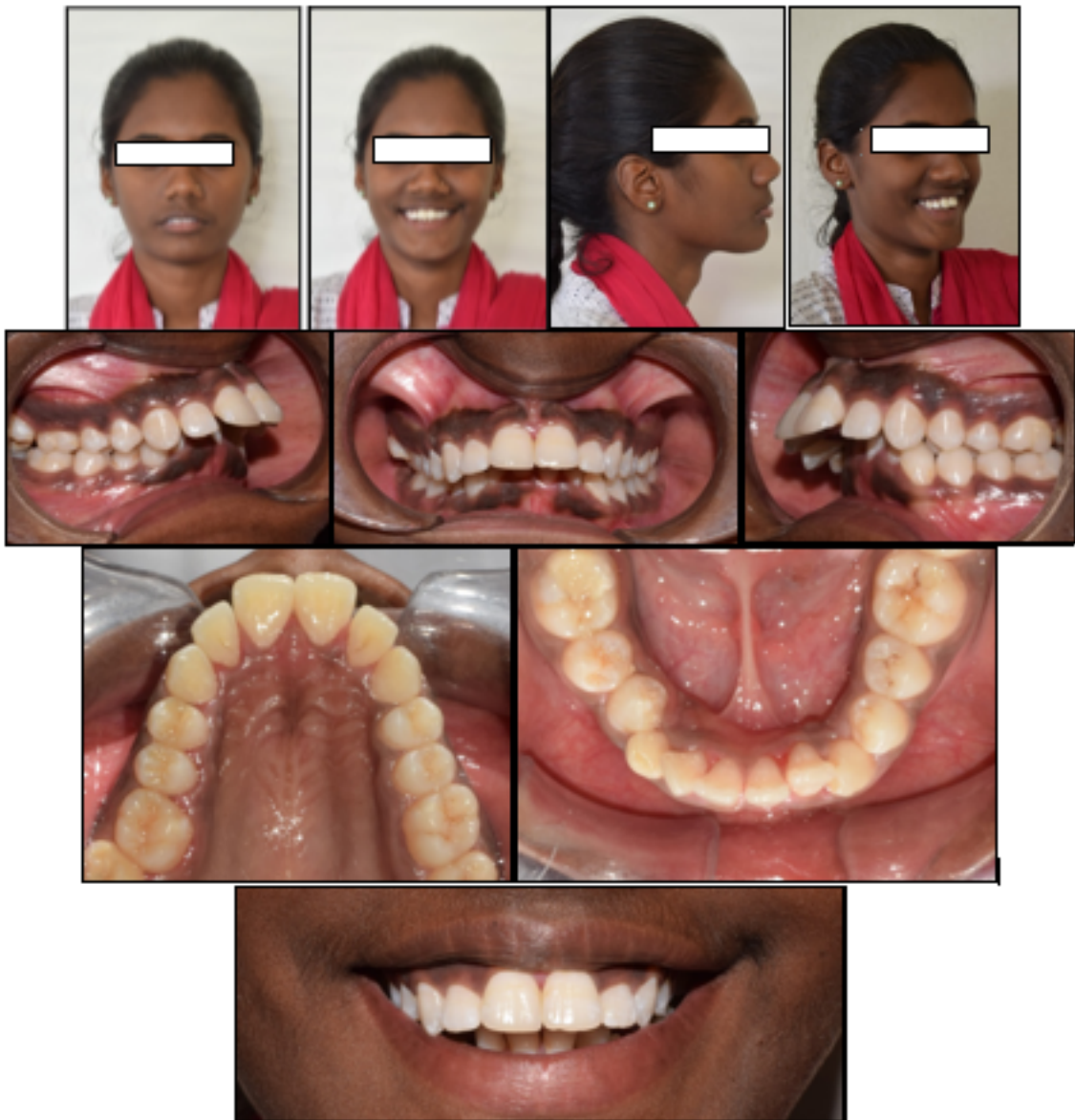


Fig. 2: Pretreatment extraoral and intraoral photograph

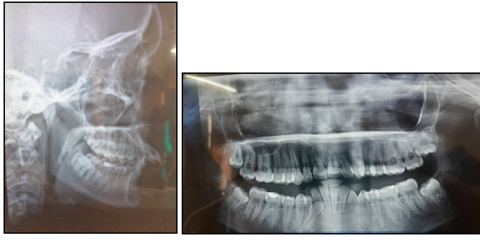


Fig. 3: Pre-treatment lateral cephalogram and OPG

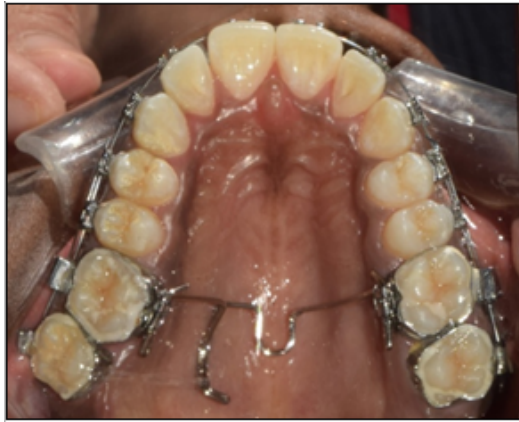

Fig. 4: TPA with distal extension

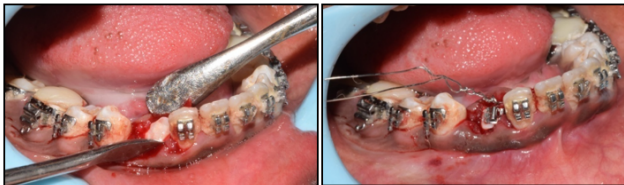

Fig. 5: Canine exposure and traction

4. Treatment Progress

1. Treatment was initiated with banding and bonding procedure using preadjusted edgewise appliance with 0.022" MBT bracket slot.
2. Leveling and alignment were carried out with 0.012" Niti wire sequentially to 0.019 x 0.025" S.S wire.
3. Modified TPA were placed to correct the posterior crossbite w.r.t 17 47.(Figure 4)
4. After initial leveling and alignment extraction of retained deciduous teeth 83, surgical exposure of mandibular canine 43 were carried by raising a buccal flap and attaching the begg's bracket onto the labial surface of exposed tooth. Following this, a ligature wire was placed through this bracket and attached around main archwire. The flap was replaced and sutured. As the tooth was placed lingually, buccal traction were given to bring the canine into arch. (Figure 5)

5. During alignment and leveling upper first premolars were also extracted.
6. Then the retraction was carried out using power arms in upper first molars. Hence, power arm supported intrusion and retraction was carried out. (Figure 6)
7. Finishing and detailing was done and fixed spiral retainers were bonded upper and lower arches from end of treatment good smile esthetics were obtained. Canine to canine and circumferential retainers were given. (Figure 7)

5. Treatment Results

At the end of the treatment Angle's Class II molar relation was maintained on both side and class I canine relation achieved on both side. Upper arch was retracted and cross bite was corrected. The lower crowding was resolved. Normal overjet and overbite were attained. Smile was also improved at the end of treatment (Figure 6). Pre and post treatment cephalogram (Figure 8 and Table 1) were compared which showed that upper and lower incisor angulation was within normal range after treatment.

Table 1: Pre and post treatment cephalometric measurements

Cephalometric measurements	Pre-treatment	Post-treatment
SNA	79	78
SNB	76	77
ANB	3	1
N-A-Pog	1	2
SN-Go-Gn	27	35
Facial Axis	90	92
U1-SN	126	105
L1-MP	84	104
U1-NA	40,10mm	27,6mm
L1-NB	13,3mm	25,3mm
Nasolabial angle	108	120
Lip strain	5mm	7mm

6. Discussion

Adult patients with severe Class II malocclusion may be treated by camouflage or a combination of orthodontic and orthognathic surgeries depending on the severity of malocclusion.³ The main goal of treatment by orthodontic camouflage is to mask the marked skeletal discrepancy by dental compensations. In Class II malocclusion when extractions are needed, they are usually done in the maxillary first premolars to correct the proclination of the upper incisors. This is usually followed by en-masse retraction of the upper incisor with absolute or maximum anchorage to close the extraction space and reduce overjet. This will lead to flattening of the nasolabial angle improvement lip position.⁴

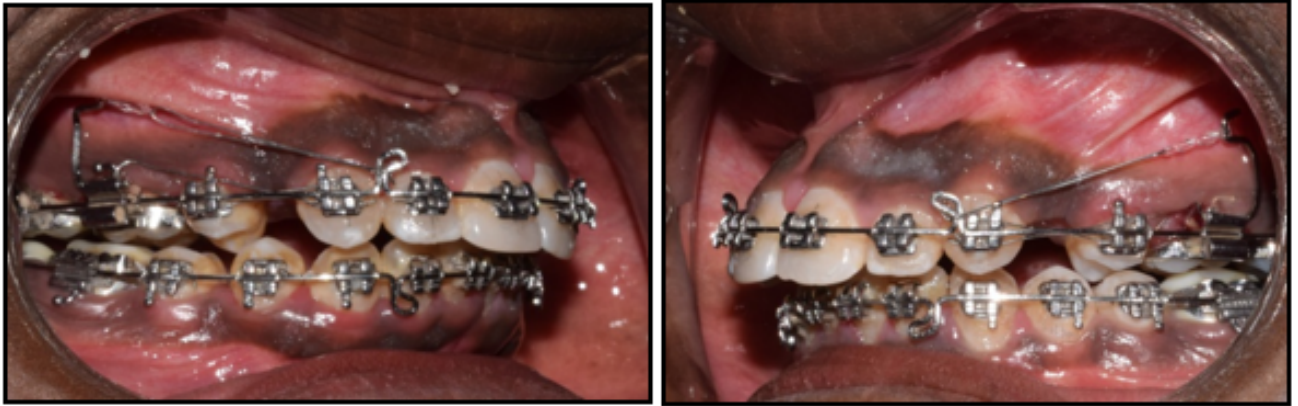

Fig. 6: Retraction with power arm

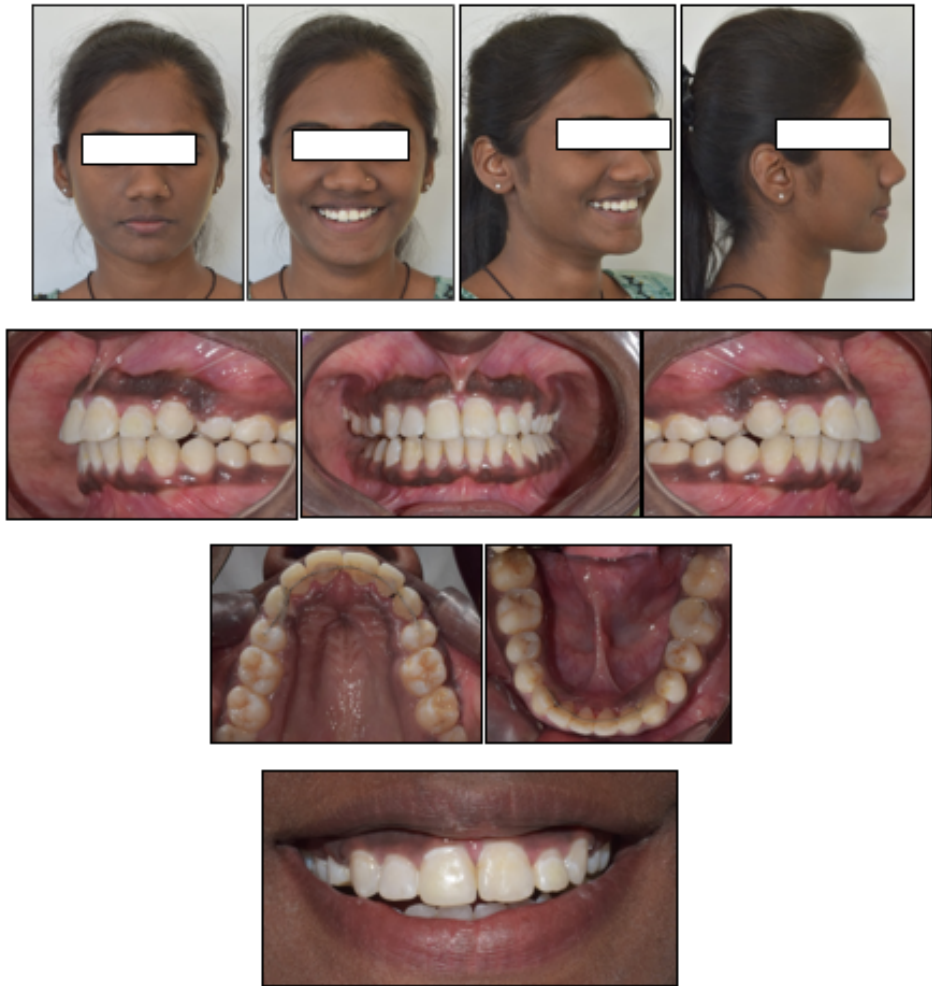

Fig. 7: Post treatment extraoral and intraoral photographs

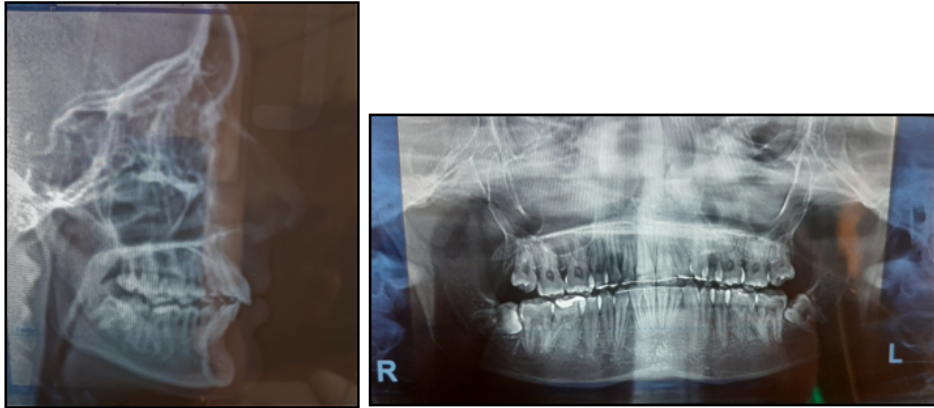


Fig. 8: Post treatment lateral cephalogram and OPG




Fig. 9: Overall superimposition

In this case, it was decided to use the power arm to improve the gummy smile. Construction of power arm done by using 19*25 S.S. wire. As the center of resistance is considered the most important point for tooth movement. Power arm moves the point of force application close to center of resistance, it provided posterior and superior vector of force which was required for intrusion of anterior teeth. This not only helps to avoid labial tipping of anterior teeth but also bring about effective intrusion to minimize gummy smile. (Figure 1)

An attempt to level the buccally placed maxillary 2nd molar by using TPA with distal extension and E-chain crosses over the occlusion surface of maxillary 2nd molar. It helps to apply an isolated forces on buccally placed maxillary 2nd molar without disturbing anchor unit and any undesirable movement on the dentition. This kind of intraarch crossbite correction does not interfere with the physiologic eruption of teeth in the opposite arch.⁵

Success of treatment of mandibular impacted canine depends upon the position, impaction level and age of the patient. In this case as the canine was in favorable position and since canines are considered important keystones in the dental arch, we decided to orthodontically bring it into its ideal position. The needful application of force in different direction is required for not only successfully guiding the eruption of an impacted canine but also aligning it in its correct position. Here in this case overall Treatment time was 30 months with improved smile & Profile. Upper incisors were retracted to achieve normal incisor angulations, Overjet & overbite. Lips became competent and lower lip controlled upper incisors successfully, which is very important for incisor stability in class II division 1 malocclusion.

7. Conclusion

Dental camouflage orthodontic treatment could be a very important alternative method of managing malocclusion rather than through conventional way of approach. Managing such way would be a much more effective clinical way to solve complex malocclusions. Gummy smile was treated with power arm through intrusion of the upper incisors, also patient's profile was improved by correction of overjet using power arm. Treatment was successful with the recovery of impacted canine, correction of crossbite, There

was overall significant improvement in the facial appearance and soft tissue profile of the patient. Esthetically, balanced results were achieved.

8. Source of Funding

None.

9. Conflict of Interest

None.

References

1. Naragond A, Kenganal S, Sagarkar SR. Orthodontic Camouflage Treatment in an Adult Patient with a Class II, Division 1 Malocclusion – A Case Report. *J Clin Diag Res.* 2013;7(2):395–98.
2. Naik VR. Management of Class II div I malocclusion- A case report. *Int J Clin Dental Sci.* 2010;1(1):70–2.
3. Bishara SE, Cummins DM, Jakobsen JR, Zaher AR. Dentofacial and soft tissue changes in Class II, Division 1 cases treated with and without extractions. *Am J Orthod Dentofac Orthop.* 1995;107(1):28–37.
4. Mihalik CA, Proffit WR, Phillips C. Long-term follow-up of Class II adults treated with orthodontic camouflage: A comparison with orthognathic surgery outcomes. *Am J Orthod Dentofac Orthop.* 2003;123(3):266–78.
5. Gupta A, Kannan S, Gupta G, Goyalia A, Kaul A, Garg N. A Modified Transpalatal Arch with Sleeve. *J Indian Orthod Soc.* 2013;47(2):112.

Author biography

Rashi Yadav Postgraduate

Bhavesh Kothari Professor

Kamlesh Garg Professor

Parmender Vaidik Postgraduate

Bhakti Rajdev Postgraduate

Tulip Chakravarty Postgraduate

Cite this article: Yadav R, Kothari B, Garg K, Vaidik P, Rajdev B, Chakravarty T. Treatment of Class II div.1 malocclusion with impacted mandibular canine: A case report. *IP Int J Maxillofac Imaging* 2020;6(3):83-88.