



## Case Report

# Non-Hodgkin's lymphoma with orbital, oral and systemic manifestations: A case report and review of literature

Santan Reddy Muthyam<sup>1,\*</sup>, Surekha P<sup>2</sup>, Charan Paul Motupalli<sup>3</sup>

<sup>1</sup>Dept. of Oral Medicine and Radiology, Sri Balaji Dental College, Hyderabad, Telangana, India

<sup>2</sup>Dept. of Radiology, Bhaskar Medical College, Hyderabad, Telangana, India

<sup>3</sup>Dept. of Pathology, Bhaskar Medical College, Hyderabad, Telangana, India



## ARTICLE INFO

### Article history:

Received 21-03-2021

Accepted 28-3-2021

Available online 29-04-2021

### Keywords:

Extranodal

NonHodgkin's Lymphoma

Optic nerve

## ABSTRACT

Non-Hodgkin's Lymphoma is the commonest among all forms of Lymphomas. It may manifest with nodal and extranodal involvement. Salivary glands, waldeyer's ring, paranasal sinuses are the common sites of extranodal involvement in the head and neck region. Gingiva, buccal mucosa and palate are the intraoral sites of extranodal involvement. Oral manifestations include painful and mobile teeth, gingival or mucosal swellings which may mimic odontogenic pathologies. Intraoral and orbital presentation of Non-Hodgkin's Lymphoma is a sign of aggressive behavior and poor prognosis. Lymphomas have a possibility of relatively early diagnosis with systematic examination of oral tissues and the head and neck region, and timely histopathological and radiological investigations.

© This is an open access article distributed under the terms of the Creative Commons Attribution License (<https://creativecommons.org/licenses/by/4.0/>) which permits unrestricted use, distribution, and reproduction in any medium, provided the original author and source are credited.

## 1. Introduction

Lymphomas are a set of malignancies with pathological behavior ranging from indolent to aggressive and are potentially fatal. Non-Hodgkin's Lymphoma involving extra nodal sites accounts to 20% to 30%.<sup>1</sup> The incidence of oral Non-Hodgkin's Lymphoma is around 0.1% to 5%. Lymphomas involving the orbits may present as isolated optic nerve involvement or along with central nervous system or systemic involvement.<sup>2</sup>

## 2. Case Report

A 50 years old male patient reported with a chief complaint of multiple intra-oral swellings following extraction of a painful mobile tooth 25 days ago. Patient noticed multiple swellings intra-orally and over the right eyebrow. Similar swellings were also noticed on the scalp and the upper back. On intra-oral examination 38 and 41 were missing, there were multiple teeth with Grade 1 mobility and the

periodontal condition was poor. Three soft tissue swellings with well defined borders were seen arising from the attached gingiva palatal to 21, 22, 23; the second one was seen in 38 region (Figure 1) which was extracted 25 days ago with proliferative component and necrotic slough. The third swelling was seen distal to 48 with an ulceroproliferative component and necrotic slough. The swellings were soft to firm in consistency and were mildly tender. There was no pus discharge on probing the periodontal tissues adjacent to the swellings.

Extra-oral examination revealed multiple swellings involving the forehead above the right eyebrow, the scalp over the occipital region, and the lower back. The swellings were soft to firm in consistency and nontender. There was enophthalmus of the right eye with ptosis with blood tinged discharge (Figure 2). Patient gives a history of complete loss of vision in the left eye following trauma 10 years ago and partial loss of vision in the right eye since a week. Neck examination revealed bilateral submandibular lymphadenopathy, and further general examination revealed bilateral axillary lymphadenopathy.

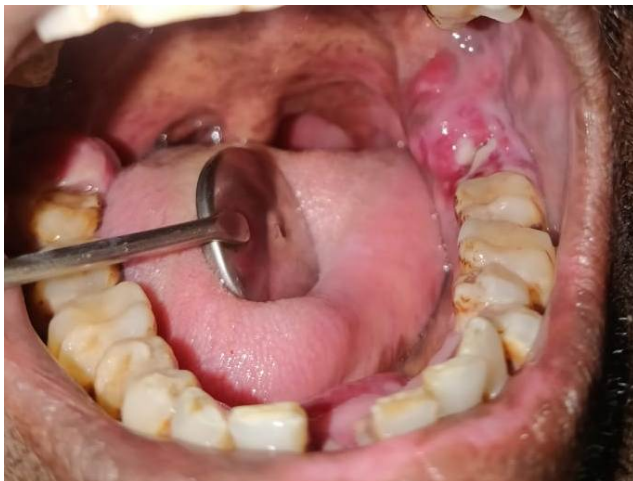\* Corresponding author.

E-mail address: [drshantan8@gmail.com](mailto:drshantan8@gmail.com) (S. R. Muthyam).

Medical history was negative for hypertension, diabetes. Blood investigations were negative for HIV 1 & 2 and HBsAg. Hemoglobin was 9.9g/dL and ESR was 50 mm Hr. He consumes alcohol and smokes beedi since 30-35 years.

With a provisional diagnosis of Non-Hodgkin's Lymphoma and chronic generalized periodontitis, orthopantomograph, biopsy of intra-oral swellings and CT of the orbits and the jaws was advised. Irregular bone erosion was evident in the region of 21, 22, 23, post extraction alveolar socket and proliferative soft tissue shadow was seen in the region of 38 and distal to 48 (Figure 3). Patient was admitted and an initial FNAC of the supraorbital swellings was done which suggested sheets of small round cells with increased nuclear/cytoplasm ratio and vesicular nucleus with prominent nucleoli, atypical mitotic figures, features suggestive of Non-Hodgkin's Lymphoma (Figure 4).

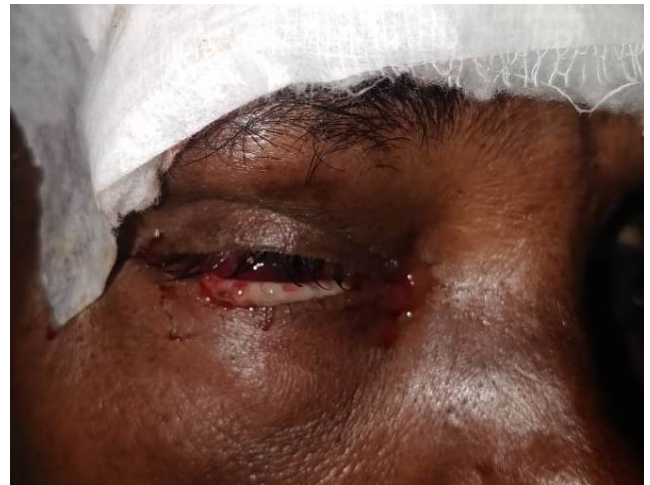Further investigations were done with Non-Hodgkin's Lymphoma as provisional diagnosis. CT of the head and neck revealed well defined oval hyperdense intraconal mass in posterior part of right orbit lateral to optic nerve involving and compressing the globe from below. Another small similar lesion is seen in right orbital septum extending upwards in prefrontal region (Figures 5 and 6). Abdominal ultrasound revealed peripancreatic lymphadenopathy and hepatomegaly. Biopsy of the intra-oral swellings could not be done as there was a sudden deterioration in the patient's condition on the third day and therefore had to be discharged and immediately referred to Regional Cancer Centre. He succumbed 20 days after he reported to our hospital without undergoing any therapy.



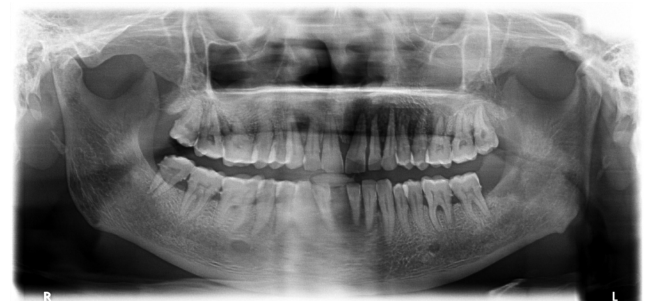**Fig. 1:** Intraoral ulceroproliferative swelling in the region of 38

### 3. Discussion

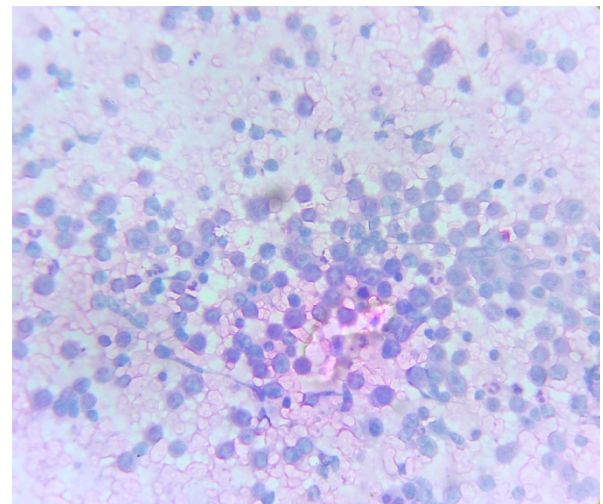
Lymphomas involving the orbits are rare and 1% of them are Non-Hodgkin's Lymphoma. In a retrospective



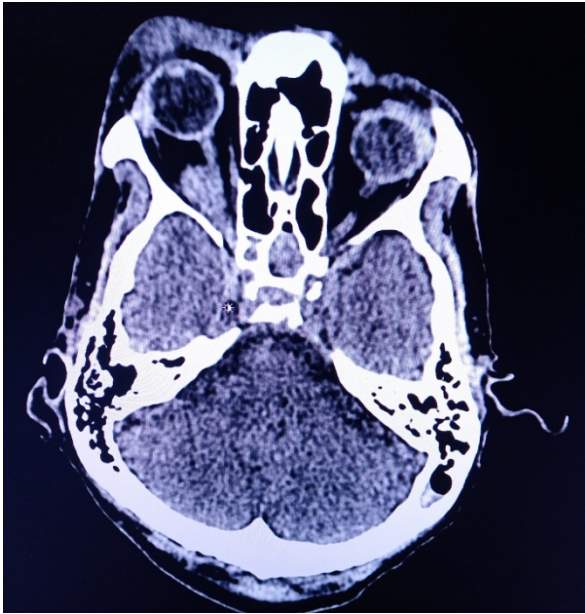
**Fig. 2:** Enophthalmos of right eye with bloody discharge and ptosis



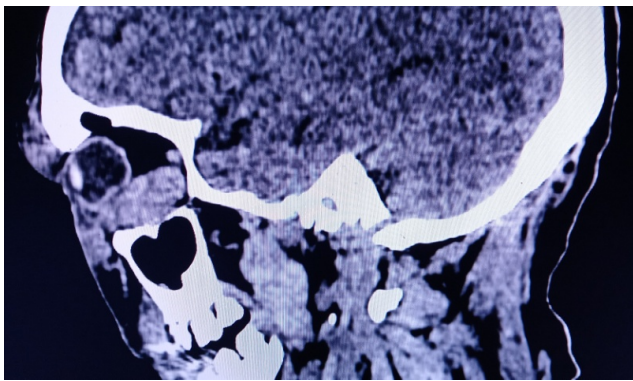
**Fig. 3:** Orthopantomograph showing irregular bone erosion in the region of 21, 22, 23; post extraction alveolar socket and proliferative soft tissue shadow was seen in the region of 38 and distal to 48



**Fig. 4:** FNAC shows sheets of small round cells with increased nuclear/cytoplasm ratio and vesicular nucleus with prominent nucleoli, atypical mitotic figures



**Fig. 5:**



**Fig. 6:** Plain CT images revealing well defined oval hyperdense intraconal mass in posterior part of right orbit lateral to optic nerve involving and compressing the globe from below. Another small similar lesion is seen in right orbital septum extending upwards in prefrontal region

study of 11 patients with orbital tumors, 9 patients (82%) were diagnosed with extranodal MALT Lymphoma and 2 patients with Diffuse Large B cell Lymphoma and recurrent Mantle Cell Lymphoma respectively.<sup>3</sup> Extra nodal sites of involvement of Non-Hodgkin's Lymphoma are GIT, bone, skin and Waldeyer's ring. Intraoral sites like gingiva, buccal mucosa are uncommon and may present with tooth mobility, localized swelling, unexplained tooth pain or ill-defined lytic bone changes.<sup>1</sup>

This particular patient had an aggressive presentation with the involvement of the optic nerve and multiple intraoral sites. Optic nerve involvement is seen in 5% of patients with CNS involvement which in turn constitute 10% of Non-Hodgkin's Lymphomas. Secondary infiltration

to optic nerve is more common than primary optic nerve tumor. Routes of secondary infiltration to optic nerve involve direct spread of tumor cells, hematogenous dissemination, and dissemination through the CSF and perineural invasion. Jennifer L Kim et al have proposed a classification for optic nerve involvement in Lymphomas: 1. Primary optic nerve involvement, 2. Optic nerve involvement with CNS disease, 3. Optic nerve involvement with systemic disease, 4. Optic nerve involvement with Primary Intraocular Lymphoma (PIOL).<sup>2</sup>

Lymphomas involving the CNS may be primary and secondary with the involvement of brain, leptomeninges, eyes, and the spinal cord and may have a poor prognosis. Gadolinium enhanced MRI and FDG-PET/CT should be considered for monitoring and detecting relapses in patients with Lymphomas.<sup>4</sup> Clinical features associated with orbital lymphoma include progressive proptosis, vision loss, diplopia, restricted eye ball movement. Unilateral orbital involvement is seen in majority of the cases than bilateral involvement.<sup>5</sup>

In a recent study, out of 122 lymphomas involving the head and neck region, 80 were extra nodal sites and 42 were nodal sites. Only one intraoral involvement was recorded out of the 80 extranodal sites.<sup>6</sup> Radiographic changes seen in lymphoma involving jaw bones may mimic dental abscess. Long standing jaw pain with no obvious odontogenic cause associated with mobile teeth and aggressive bone destruction could possibly be a sign of malignancy.<sup>7</sup>

Primary Intraosseous Lymphoma is an extremely rare condition which may manifest as odontogenic tumor, cyst, or an infection which may have a high probability of misdiagnosis. The initial standard therapy includes CHOPR (Cyclophosphamide, Hydroxydoxorubicin, Oncovin, Prednisolone, and Rituxan) therapy. Involvement of more than one extra nodal site is an indication of less favourable prognosis which is based on the International Prognostic Index (IPI). Lymphomas may progress in to leukemia.<sup>8</sup> Non-Hodgkin's Lymphoma may also present as generalized gingival enlargement as was reported in a pregnant female.<sup>9</sup> Diffuse Large B-cell Lymphomas involving bone leading to necrosis may be associated with *Actinomyces israelii* and lead to misdiagnosis.<sup>10</sup>

#### 4. Source of Funding

None.

#### 5. Conflict of Interest

The authors declare that there is no conflict of interest.

#### References

1. Varun BR, Varghese NO, Sivakumar TT, Joseph AP. Extranodal Non-Hodgkin's Lymphoma of the Oral Cavity: A Case Report. *Iran J Med Sci.* 2017;42(4):407-11.

2. Kim JL, Mendoza PR, Rashid A, Hayek B, Grossniklaus HE. Optic nerve lymphoma: Report of two cases and review of the literature. *Surv Ophthalmol.* 2015;60(2):153–65. doi:10.1016/j.survophthal.2014.11.004.
3. Eckardt AM, Lemound J, Rana M, Gellrich NC. Orbital lymphoma: diagnostic approach and treatment outcome. *World J Surg Oncol.* 2013;11(1). doi:10.1186/1477-7819-11-73.
4. Ban Y, Jing Z, Zou J. Multiple secondary cauda equina non-Hodgkin's lymphoma: a case report and literature review. *BMC Cancer.* 2019;19(1):594. doi:10.1186/s12885-019-5800-4.
5. Jain K, Borkar AU, Jain VK. A large primary orbital lymphoma with proptosis: A case report and review. *Surg Neurol Int.* 2018;9(1):249. doi:10.4103/sni.sni\_270\_18.
6. Walter C, Ziebart T, Sagheb K, Nedjat RKR, Manz A, Hess G. Malignant Lymphomas in the Head and Neck Region - a Retrospective, Single-Center Study over 41 Years. *Int J Med Sci.* 2015;12(2):141–5. doi:10.7150/ijms.10483.
7. Bugshan A, Kassolis J, Basile J. Primary Diffuse Large B-Cell Lymphoma of the Mandible: Case Report and Review of the Literature. *Case Rep Oncol.* 2015;8(3):451–5. doi:10.1159/000441469.
8. Velez I, Hogge M. Primary Maxillofacial Large B-Cell Lymphoma in Immunocompetent Patients: Report of 5 Cases. *Case Rep Radiol.* 2011;2011:1–4. doi:10.1155/2011/108023.
9. Kothiwale S, Kore S, Rathore A. Generalized gingival enlargement in non-Hodgkins lymphoma during pregnancy: A rare case report. *J Interdiscip Dent.* 2015;5(2):83–6. doi:10.4103/2229-5194.173223.
10. Huang S, Messeca C, Remangeon F, Famery C. Diagnostic difficulty of a mandibular manifestation of diffuse large B-cell lymphoma: a case report. *J Oral Med Oral Surg.* 2021;27(1):2. doi:10.1051/mbcb/2020041.

### Author biography

**Santan Reddy Muthyam**, Associate Professor

**Surekha P**, Professor

**Charan Paul Motupalli**, Associate Professor

**Cite this article:** Muthyam SR, Surekha P, Motupalli CP. Non-Hodgkin's lymphoma with orbital, oral and systemic manifestations: A case report and review of literature. *IP Int J Maxillofac Imaging* 2021;7(1):28-31.