

Odontogenic Keratocyst involving ramus of mandible

Latika Bachani^{1,*}, Ashok Lingappa²

¹PG Student, ²Professor & Head, Department of Oral Medicine & Radiology, Bapuji Dental College, Karnataka

***Corresponding Author:**

Email: latikabachani@gmail.com

Abstract

Odontogenic Keratocysts (OKCs) are a clinical entity with a characteristic growth pattern, microscopic picture and biological behaviour. They arise from the proliferation of the cells of the dental lamina and can occur in patients of all ages. They more commonly involve the mandible, mostly the posterior body, the angle and ramus of mandible. These cysts are often asymptomatic and may attain large size without significant deformation. Many a times, they can be an incidental finding during routine dental X-ray examination. Compared to other types of jaw cysts, OKCs have a striking tendency to recur.

Keywords: *Odontogenic keratocyst, Multilocular radiolucency, Keratocystic odontogenic tumor*

Introduction

The cysts of the oral cavity are very common due to the presence of remnants of odontogenic epithelium.¹ As per the literature, periapical cyst is the most common odontogenic cyst (52.3-70.7%) followed by the dentigerous cyst (16.6-21.3%) and odontogenic keratocyst (OKC) (5.4-17.4%).²

The term odontogenic keratocyst (OKC) was first used by Philipsen in 1956.³ It was earlier known as primordial cyst, which arose from remnants of dental lamina or the enamel organs before enamel formation (Robinson, 1945).⁴ Pindborg and Hansen (1963) described its essential features.⁵

Case Report

A 36 years old female reported with a complaint of pain in posterior region of the left side of her lower jaw since 4 days. History of insidious onset of mild to moderate continuous throbbing type of pain, gradually increasing in severity, aggravates on jaw movements, mild temporary relief on taking analgesics and radiating to forehead. It is associated with insidious onset of swelling over left side of middle third of face noticed since last 3 days. The swelling is gradually increasing in size. History of intermittent discharge intraorally from left side lower jaw posterior region also present which is bitter in taste and is creamy white in color. She also complains of foul breath. No difficulty in jaw movements. No history of trauma. No history of any topical application. No history of prodromal symptoms given by the patient. She did not give any positive medical

history and family history. She revealed that the tooth 38 was extracted 3 years back due to caries and pain. The extraction was uneventful.

On general physical examination, she was well built, moderately nourished, well oriented to time, place and person and was afebrile. On extra-oral examination, bilateral submandibular lymph nodes were palpable. They were solitary, oval in shape, approximately 1cm in diameter, soft to firm in consistency, tender and mobile. The maximum mouth opening was measured as 40mm. A solitary diffuse swelling, roughly oval in shape, measuring approximately 5x5cm in size was noticed over left side her face in the middle third region. (Fig. 1 and 2) It was extending superior-inferiorly from the alar-tragal line till 2cm below the lower border of the mandible and antero-posteriorly from 2cm distal to left corner of the mouth till 1cm posterior to ear lobe. The borders appear ill-defined. Skin over the swelling and the surrounding skin appeared normal in color. The surface of the swelling was smooth. On palpation, all the inspectory findings were confirmed. The swelling was soft in consistency, non-mobile, tender and no local rise in temperature was present. Intra-orally, the left buccal mucosa over the anterior border of the ramus and the retromolar pad region appeared inflamed. On palpation, it was tender. Creamy white colored discharge was also noticed distal to 37. Buccal cortical plate expansion could be appreciated in the region of 36, 37 and distal to 37. No lingual cortical plate expansion was present. (Fig. 3) Paraesthesia was also noticed over the attached gingiva IRT 36,

37. No mobility present IRT 37. 36 and 38 were clinically missing.

Hence on the basis of these findings, a working diagnosis of odontogenic cystic lesion involving the left side posterior body and ramus of mandible was given. The differentials were given as infected odontogenic keratocyst and ameloblastoma.

On FNAC, a yellowish colored, thin consistency fluid was obtained with total protein content of 4.2g/dl. (Fig. 4)

On intraoral periapical radiograph IRT 37, 36 and 38 were found to be missing radiographically. A well-defined homogeneous radiolucency was seen distal to 37. The superior border of the radiolucency was sclerotic. (Fig. 5)

On OPG, (Fig. 6) a multilocular radiolucency was seen involving the left ramus of the mandible, which is roughly oval in shape and measuring approximately 8x5cm in size. It is extending antero-posteriorly from 1cm distal to 37 till the sigmoid notch and superior-inferiorly from 5mm below the anterior border of the ramus till 1cm

above the posterior border of ramus. The anterior, antero-superior and inferior borders of the radiolucency appear sclerotic. The borders are scalloped with thick curved septae of irregular size and shape extending into the radiolucency. The internal structure of the radiolucency appears homogeneously radiolucent. The mandibular canal is pushed below in the region of 38.

On CBCT, (Fig. 7,8,9,10) an oval shaped hypodense area expanding linguallly with thinning and loss of cortical plate and buccal plate is thin and continuous. The hounsefield unit of the hypodense area is around -200 HU. The mandibular canal is pushed below in the region of 38. Hence, the radiographic differentials were given as KCOT and ameloblastoma.

The cystic lesion was enucleated and chemical cauterization with 3 cycles of Carnoy's solution was done. The specimen was sent for histopathology and the biopsy report revealed the characteristic picture of odontogenic keratocyst. The patient is put on follow-up visits.

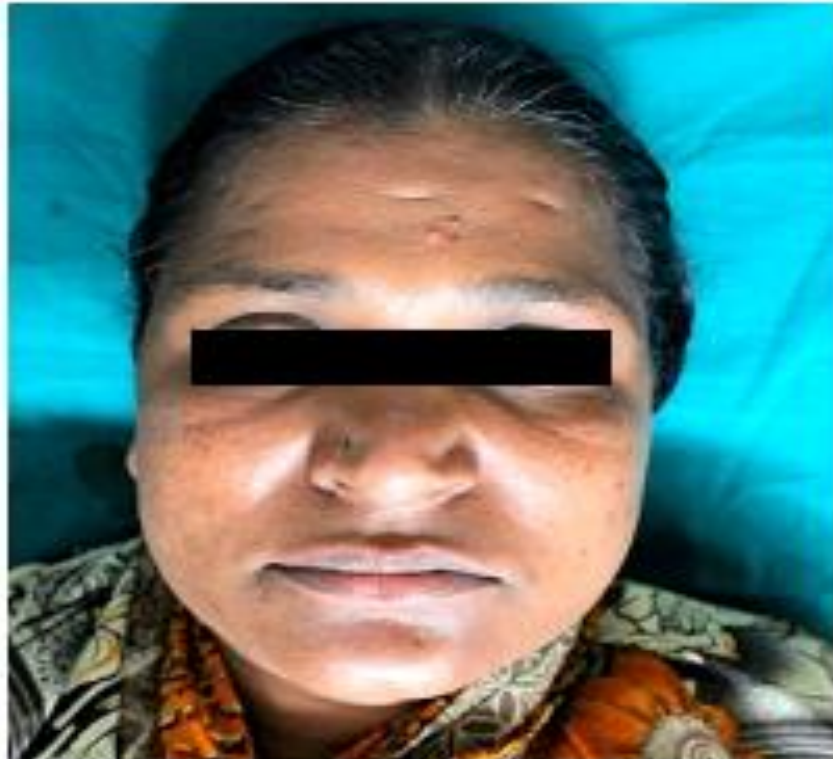

Fig. 1

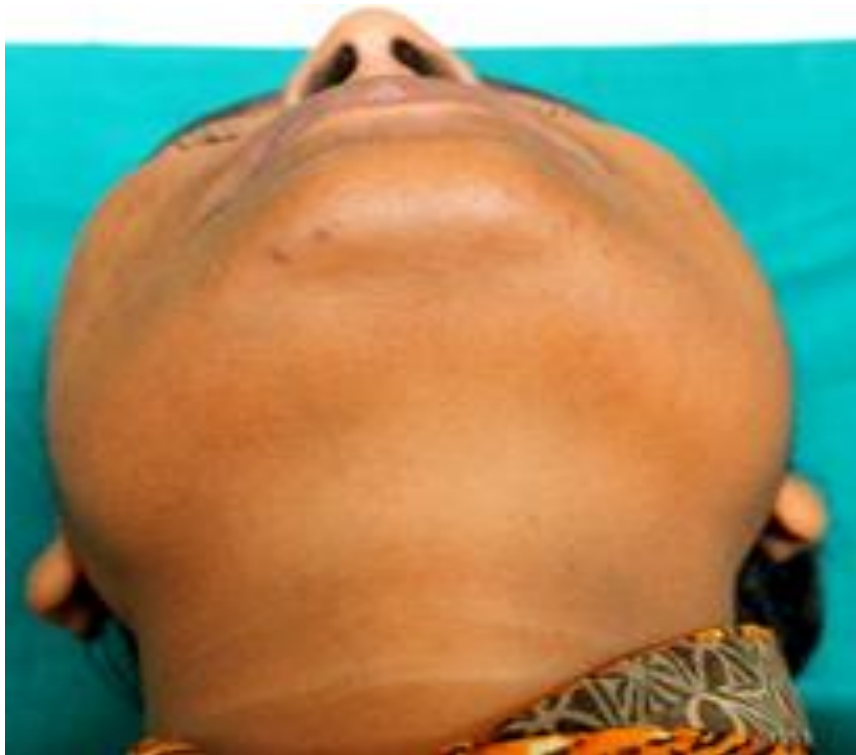

Fig. 2

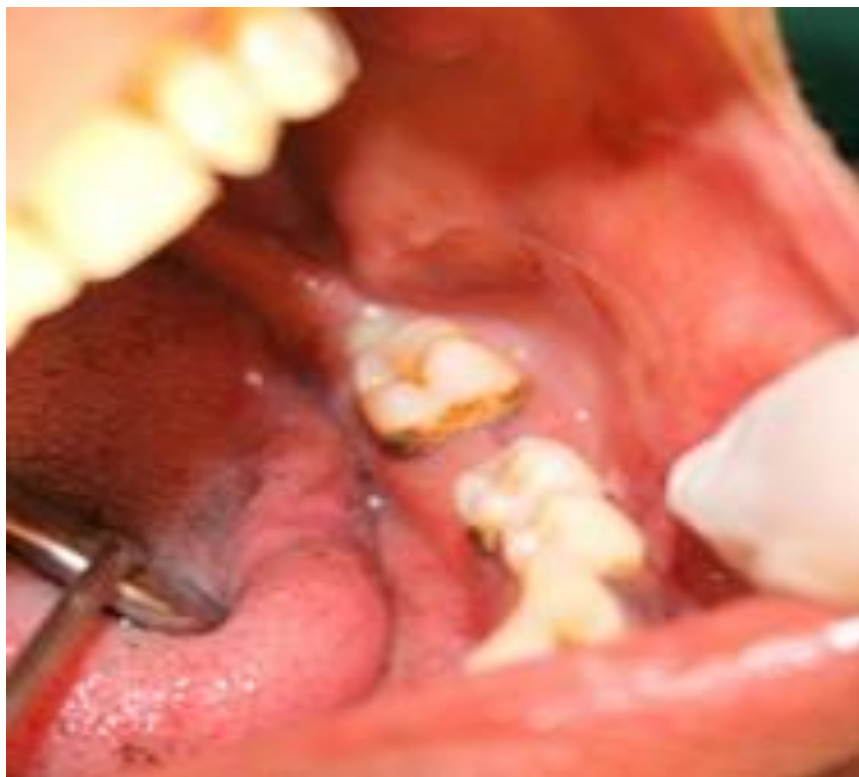

Fig. 3

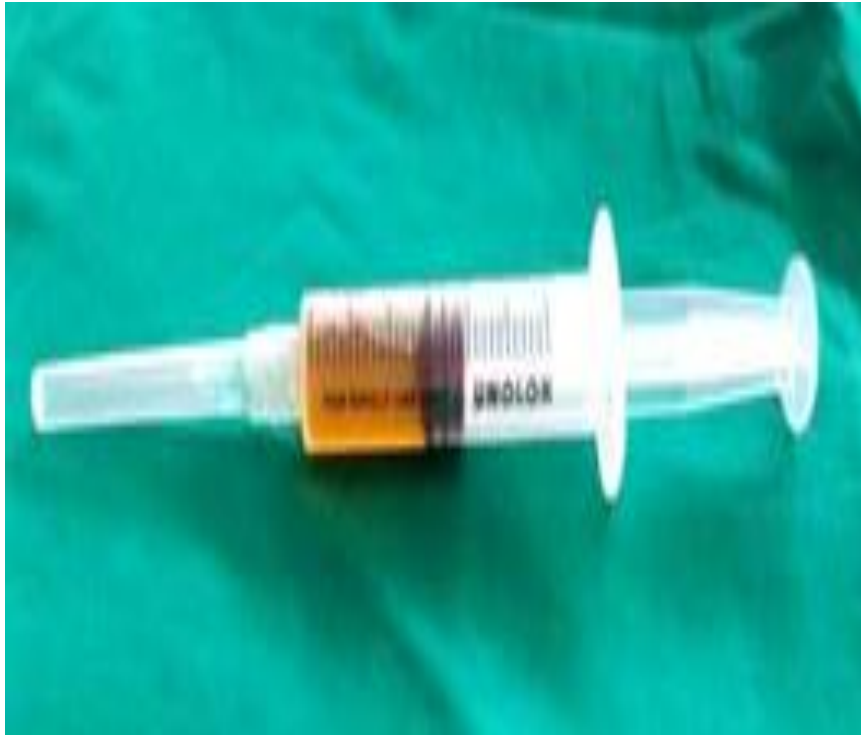

Fig. 4

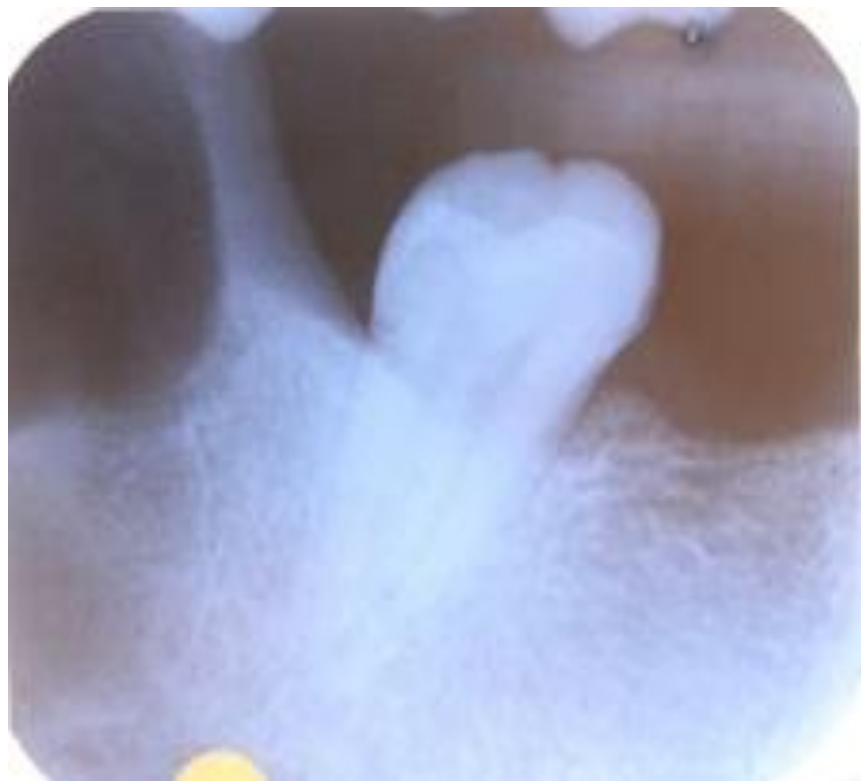

Fig. 5

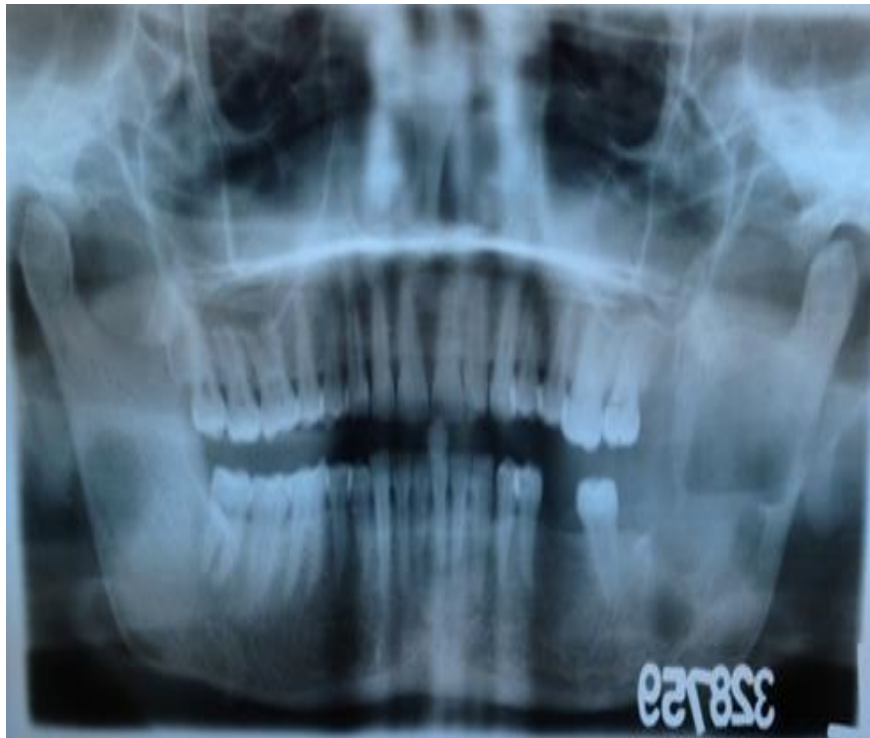

Fig. 6

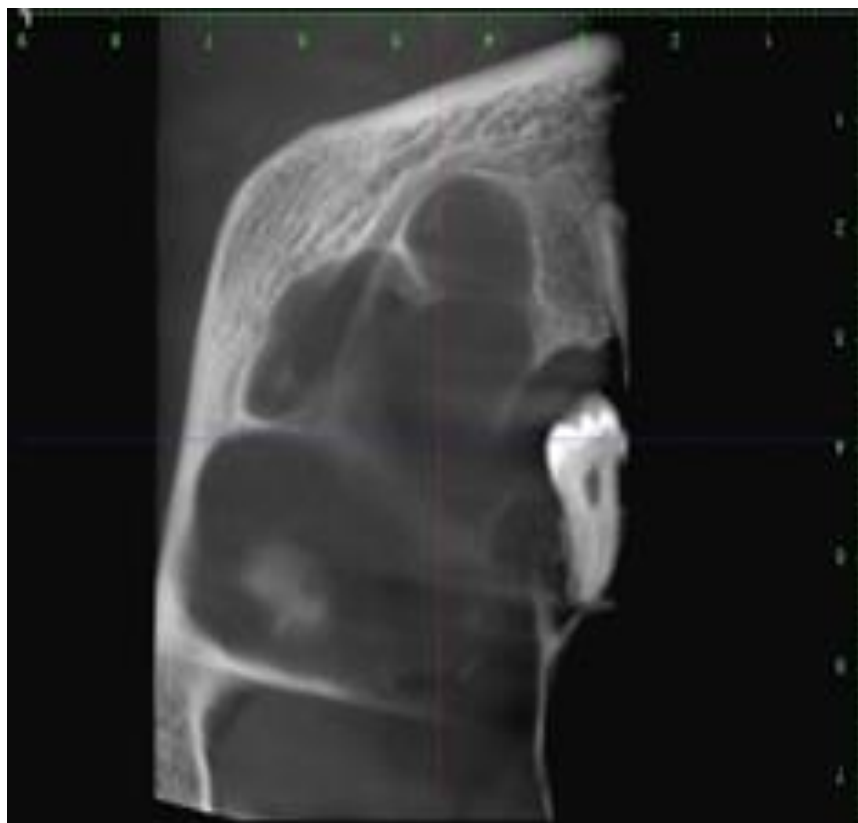


Fig. 7

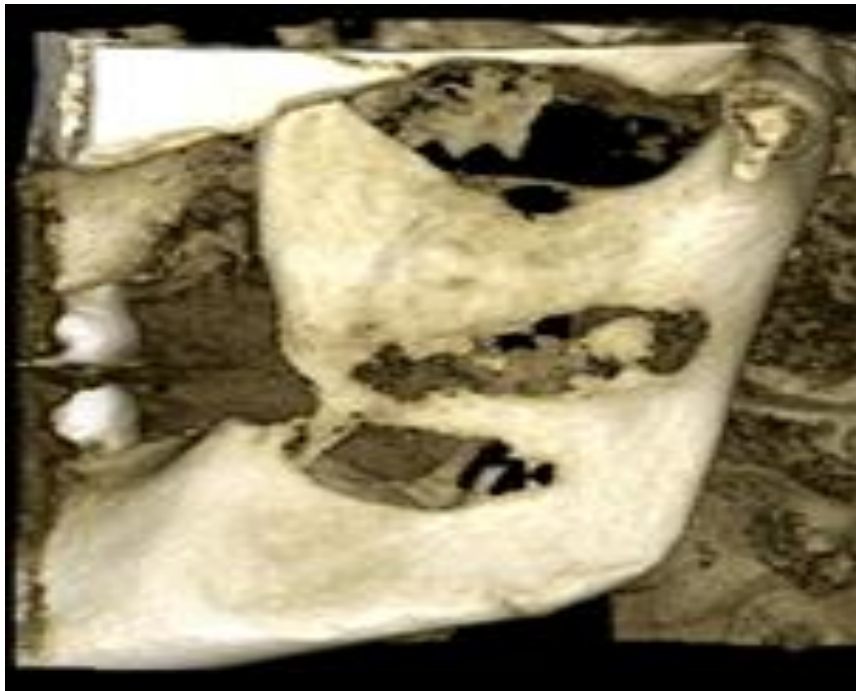


Fig. 8

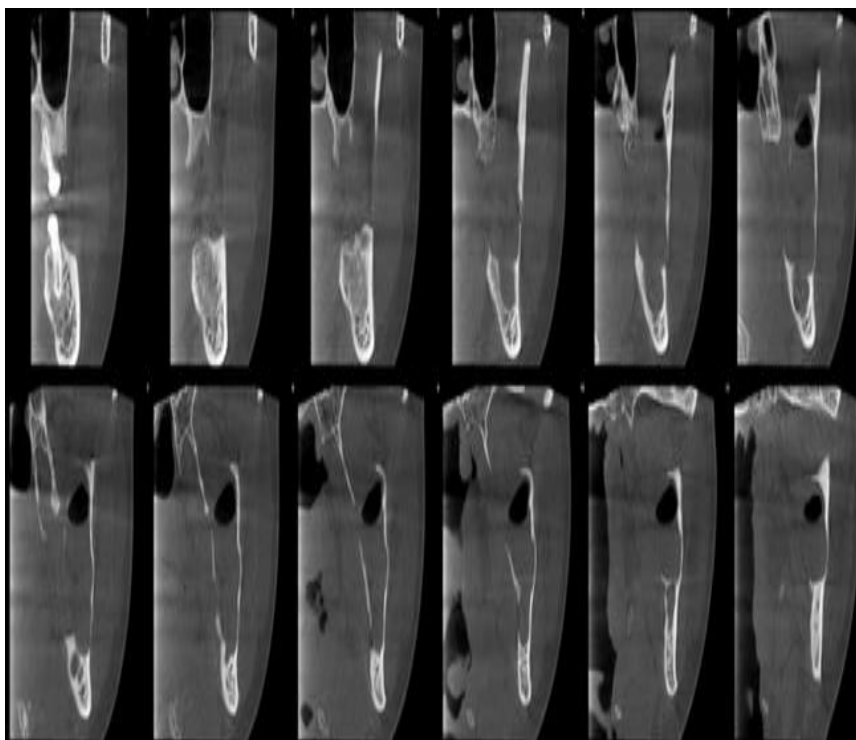


Fig. 9

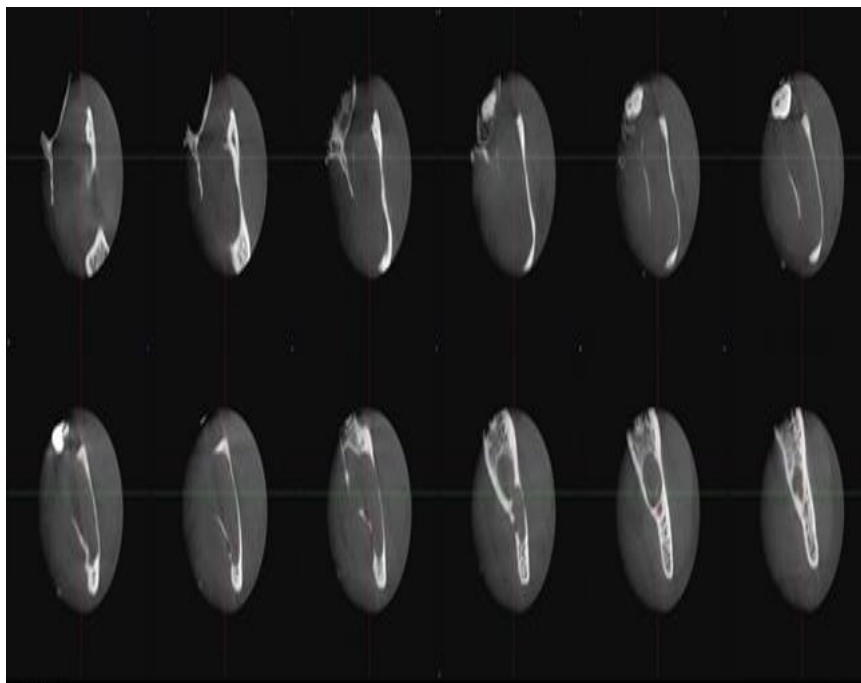


Fig. 10

Discussion

Cysts of the jaw are a common clinic-pathological finding. On the basis of their origin, they can be divided into odontogenic and non-odontogenic. OKC is an independent clinical entity with a typical microscopic picture, clinical growth and biological behavior. It was categorized in the WHO classification as a developmental, non-inflammatory odontogenic cyst that arises from cell rests of dental lamina.⁶ In the latest WHO classification of odontogenic tumors in 2005, these lesions have been renamed as “keratocystic odontogenic tumors” (KCOTs), and are among the most controversial and frequent pathological entities affecting the maxillofacial region.³

It is suggested that OKC originates from dental lamina remnants due to its growth capacity and development characteristics related to the mutation of a suppressor tumor gene, it is considered as benign cystic neoplasm.⁶

As per the literature, incidence rate of OKC is about 12-14% of all odontogenic cysts with two peaks around the ages of 30 and 60. It has a predilection for men.⁷ It can occur in any part of the mandible and maxilla, but the majority arises in the body of the mandible, wherein it occurs significantly more in the posterior region of the mandible.⁵ OKCs can be of 3 types: replace mental, envelop mental and extracranial.⁸ Many times it presents as a localized asymptomatic swelling

discovered only during the course of radiographic examination whereas larger lesions maybe associated with pain, swelling, trismus, sensory deficits, infection or drainage. Growth is chiefly in the anteroposterior dimension and the lesions may attain remarkable size without significantly deforming the jaw skeleton. This tendency to rapid growth is due to higher activity of the epithelial cells of the cyst lining stimulating osteolytic activity of prostaglandin substances in the cell population of the cyst lining and higher accumulation of hyperkeratotic scales in the lumen of the cyst with resulting greater difference in hydrostatic pressure.

Multiple OKCs are usually seen with cutaneous, skeletal, ocular and neurologic abnormalities as a component of nevoid basal cell carcinoma syndrome (NBCCS). The features of this syndrome were first described by Gorlin and Goltz in 1960, so it is also recognized as Gorlin- Goltz syndrome.⁹

Conventional radiographic examinations such as panoramic and intraoral periapical radiographs are usually adequate to determine the location and estimate the size of an OKC. Radio graphically, it presents as a well-defined radiolucent lesion that is either unilocular or multilocular, with smooth and usually corticated margins, unless they have been secondarily infected. In 25-40% of cases, there is an unerupted tooth involved with the lesion; adjacent

teeth may be displaced, but root resorption is rarely seen.¹⁰

When the cyst is multilocular and is located at the molar ramus area, it may be confused to ameloblastoma. The septa present in ameloblastoma are coarse and curved; originate from the normal bone trapped within the tumor. Hence these septa have honeycomb or soap bubble appearance which is not seen in OKC. In odontogenic myxoma, septa present are thin, sharp, and straight. A simple bone cyst has similar scalloped margin, but this margin is delicate and not distinct.¹¹

Histopathologically, OKCs present some distinguishing features compared with other odontogenic tumors. There is a well-defined, often palisaded, basal layer consisting of columnar or cuboidal cells; intensely basophilic nuclei oriented away from the basement membrane; parakeratotic layers, often with a corrugated surface and mitotic figures frequently present in suprabasal layers.¹² The epithelium may show budding of the basal layer into underlying connective tissue, with formation of detached microcysts, termed daughter cysts.¹³

In 1963, Pindborg and Hansen suggested the histological criteria for describing the essential features of OKC and investigators started to discuss the differences between the common parakeratinized type and the rarer orthokeratinized type.¹²

In 2005, the World Health Organization Working Group considered the OKC parakeratinizing variant to be a cystic neoplasm and recommended the more descriptive term "Keratocystic Odontogenic Tumor" (KCOT). Now, cystic jaw lesions that are lined by orthokeratinizing epithelium do not form part of the spectrum of KCOT.¹⁴

Depending on size, location and behavior, treatment should be decided for either incisional or excisional biopsy. Conventional options for surgery include enucleation and curettage, enucleation and peripheral ostectomy, enucleation and liquid nitrogen therapy, enucleation and Carnoy's solution, osseous resection without (rim ostectomy/marginal resection) or with (segmental resection) continuity defect. Carnoy's solution is a mixture of absolute alcohol (60%), chloroform (30%), glacial acetic acid (10%), and ferric chloride (1 g dissolved in 24 ml of absolute alcohol) that penetrates bone to a predictable time dependent depth without injuring the neurovascular structures.

A 5 min application penetrates bone to a depth of 1.54 mm, nerve to a depth of 0.15 mm, and mucosa to a depth of 0.51 mm. Because most residual cells and daughter cysts from locally recurrent lesions are adjacent to the main lesion, it is likely that fixation of vital bone need only extend for 2-3 mm beyond the enucleated lesion.¹⁵

Recurrence of the KCOT ranges from 2.5% to 62%. The possible mechanisms of recurrence have been described by Voorsmit et al. in 1981. These state that any lining epithelium left behind in the oral cavity may give rise to a new lesion formation. Daughter cysts, microcysts or epithelial islands can be found in the walls of the original cysts. New KCOTs may develop from epithelial offshoots of the basal layer of oral epithelium. A long follow-up is hence needed to observe the recurrence for any treatment modality.¹⁶

Conclusion

Odontogenic Keratocysts are not currently a diagnostic problem. Orthopantomograms which are today ordinary tools of dental investigation, make possible the diagnosis of clinically asymptomatic cystic lesions. The problem remains the optimal therapeutic approach to reduce to a minimum the still high likelihood of postoperative recurrence. There is no complete consensus on the ideal operating procedure even today. An open question also remains the timelines of screening for postoperative recurrences. In this regard, in patients with NBCC it is recommended that follow-up X ray is performed only once a year.

References

1. Cawson RA, Odell EW. Essentials of Oral Pathology and Oral Medicine. 6th ed., Vol. 97. New York: Churchill Livingstone; 1998.
2. Daley TD, Wysocki GP, Pringle GA. Relative incidence of odontogenic tumors and oral and jaw cysts in a Canadian population. *Oral Surg Oral Med Oral Pathol* 1994;77:276-80.
3. Philipsen HP. Keratocysticodontogenic tumor. In: Barnes L, Eveson JW, Reichart P, Sidransky D, editors. World Health Organization Classification of Tumors: Pathology and Genetics of Head and Neck Tumors. Lyon: IARC Press; 2005. p. 306-7.
4. Robinson HBG. Classification of cysts of the jaws. *Am J Ortho Oral Surg* 1945;31:370-5.
5. Kramer IR, Pindborg JJ, Shear M. The WHO Histological Typing of Odontogenic Tumors. A commentary on the Second Edition. *Cancer* 1992;70:2988-94.
6. Philipsen HP. Keratocysticodontogenic tumor. In: Barnes L, Eveson JW, Reichart P, Sidransky D, editors. World Health Organization Classification of Tumors: Pathology and Genetics of Head and Neck Tumors. Lyon: IARC Press; 2005. p. 306-7.

7. Rajendran R, Shivpathasundaram B. Shafer's textbook of Oral pathology. Elsevier publication. Noida. 2006. 5th edition. Pg: 363-367.
8. MacDonald-Jankowski DS. Keratocystic odontogenic tumor: systematic review. Dentomaxillofac Radiol. 2011;40:1-23.
9. Voorsmit RA. The incredible keratocyst: A new approach to treatment. Dtsch Zahnarztl 1985;40:641-4.
10. Titinchi F, Nortje CJ. Keratocystic odontogenic tumor: a recurrence analysis of clinical and radiographic parameters. Oral Surg Oral Med Oral Pathol Oral Radiol. 2012;114:136-42.
11. C. S. White and J. M. Pharaoh, Oral Radiology Principles and Interpretation, Mosby Elsevier, 5th edition, 2004.
12. Chirapathomsakul D, Sastravaha P, Jansisyant P. A review of odontogenic keratocysts and the behavior of recurrences. Oral Surg Oral Med Oral Pathol Oral Radiol Endod 2006;101:5-9.
13. Bakaeen G, Rajab LD, Sawair FA, Hamdan MA, Dallal ND. Nevoid basal cell carcinoma syndrome: a review of the literature and a report of a case. Int J Paediatr Dent. Jul 2004;14(4):279-87.
14. Brøndum N, Jensen VJ. Recurrence of keratocysts and decompression treatment. A long-term follow-up of forty-four cases. Oral Surg Oral Med Oral Pathol 1991;72:265-9.
15. Pindborg JJ, Hansen J. Studies on odontogenic cyst epithelium. 2. clinical and roentgenologic aspects of odontogenic keratocysts. Acta Pathol Microbiol Scand 1963;58:283-94.
16. Voorsmit RA, Stoelinga PJ, Van Haelst UJ (1981) The management of keratocyst. J Maxillofac Surg 9(4):228-236.