

Massive Osteolysis of the Mandible (GORHAMs Disease) - A Rare Case Report

S. Padmashree¹, Lekshmy J^{2,*}, Shilpa Sastry³, Rema Jayalekshmy⁴, Rachna Kaul⁵

¹Professor & HOD, ³Senior Lecturer, ⁴Professor, ⁵Reader, Vydehi Institute of Dental Sciences and Research Centre, ²Senior Lecturer, Department of Oral Medicine & Radiology, Dr. Syamala Reddy Dental College & Hospital, Bangalore

***Corresponding Author:**

Email: dr.lekshmyj@gmail.com

Abstract

Massive Osteolysis (Gorhams Disease) is a rare, insidious, chronic disease characterized by progressive resorption of contiguous osseous structures. In 1838, Jackson first described a case of disappearing humerus. Condition is exceedingly rare with less than 150 cases have since been described in the international literature, with fewer than 35 involving a maxillofacial site, usually the mandible. The exact cause of this disease remains unknown, but ongoing clinical research attempts to better understand the etiology. Here we are presenting an unusual and rare case report of a 7 year old female pediatric patient diagnosed as massive osteolysis involving mandible. The purpose of this case report is to raise awareness of the condition and to highlight the clinical and radiological findings that would make the oral diagnostician consider it as a rare differential diagnosis in lesions of facial skeleton. To the best of our knowledge, our case report represents the fourth case in the literature to document Massive osteolysis in a female pediatric patient with mandibular involvement.

Keywords: Gorhams disease, Osteolysis, Mandible

Introduction

Massive osteolysis is a rare skeletal disorder, the etiology and pathogenesis of which is still unknown^[1]. Also called as vanishing bone disease, Gorhams disease, Phantom bone disease, and as Gorham-Stout syndrome. First description was by Jackson *et al* in 1838, since then no more than 200 cases have been reported^[1]. Massive osteolysis is usually initiated in a single bone (or very few bones) or contiguous bones around one focus, according to clinical records^[1]. The maxillofacial skeleton is one region frequently affected. Romer *et al* in 1928 described the first maxillofacial case^[2]. Since then, approximately 50 maxillofacial cases have been reported. The diagnosis is always based on clinical examination, radiographic appearance, and histopathological features. Radiological investigations are very important in the initial diagnosis, continued management, and long-term follow up of patients with Gorhams disease^[3]. Common radiologic findings include atrophy, dissolution, fracture, or fragmentation of bone. Although the specific features of Gorhams disease were initially described with plain radiography, improvements in diagnostic technology have led to the application of these techniques to study the osteolytic lesions more

closely. Herein, we report an unusual and rare case of massive osteolysis involving mandible in a seven year old female child patient with its clinical and radiographic presentation.

Case Report

A 7 year old child female patient presented to the dental out-patient department of Oral Medicine and Radiology, Vydehi Institute of Dental Sciences & Research centre with a chief complaint of pain & progressive loosening of teeth on lower front teeth region of jaw since 4years (Fig. 1). Pain was intermittent, dull type of moderate intensity which aggravated on having food and relieved on its own and mobility of teeth was noticed at the same time which gradually progressed and reached the current status. Patient encountered difficulty in having food & brushing since then. Patient doesn't reveal any history of associated fever, trauma, swelling, sinus opening or pus discharge. The medical, personal and family histories were non-contributory.

Intraoral examination revealed a mass of calculus present on mandibular anterior region with inflamed and detached gingival tissue. Entire lower right quadrant teeth appear displaced & 74 (Mandibular left deciduous 1st molar) appear to be

displaced mesially. Missing tooth was noted in relation to 84(Mandibular right deciduous 1st molar). Maxillary dentition appeared normal for her age and sex with inflamed and hyperplastic gingival tissue (Fig. 2). On palpation, bleeding on probing was elicited on slight provocation with grade III mobility of teeth on lower right quadrant and grade II mobility on lower left quadrant. Reduced thickness of mandible was felt with a step deformity suspected on lower right quadrant anteriorly. Based on the history & clinical findings, a provisional diagnosis of rapidly progressing pattern of periodontitis in relation to mandible was given. Differential diagnosis considered were Langerhans cell histiocytosis, Papillon lefevre syndrome, Hypophosphatasia and Cyclic neutropenia.

Radiographic investigations were conducted to confirm the diagnosis. Panoramic radiograph revealed mixed dentition with maxilla appearing normal for her age and sex. An excessively thin rim of bone noted in relation to the entire mandible with missing teeth on lower right quadrant. Pathologic fracture noted on right inferior border of mandible anteriorly. Computed tomography of head & neck region (3D reconstruction images) (Fig. 4 & 5) also revealed severe osteolytic changes involving the entire mandible. When compared to left side osteolytic changes were more severe in relation to right side involving body and ramus. Total body technetium 99m bone scan was carried out to rule out the involvement of other bones. The scintigraphy scan ruled out the involvement of other bones except mandible (Fig. 6). Haematological investigations including serum calcium, acid and alkaline phosphatase were under normal limits, and no endocrine abnormalities were identified. The findings of pelvic and chest radiography were also normal. Based on history, clinical findings and radiographic findings, a final diagnosis of massive osteolysis of mandible was given. Proposed treatment plan was total mandibular reconstruction with free vascularised fibular graft & bilateral prosthetic replacement of temporomandibular joints with subsequent follow up visits.

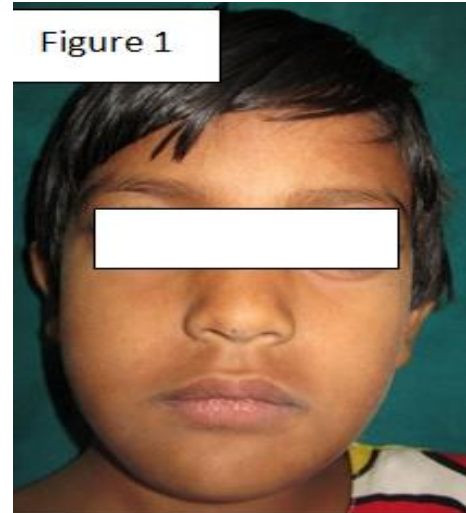

Fig. 1: Extraoral Picture

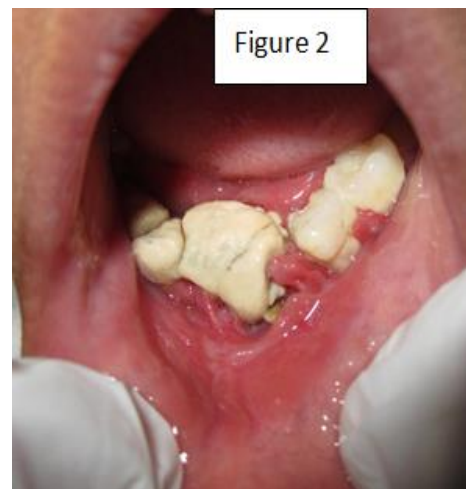

Fig. 2: Intraoral Picture

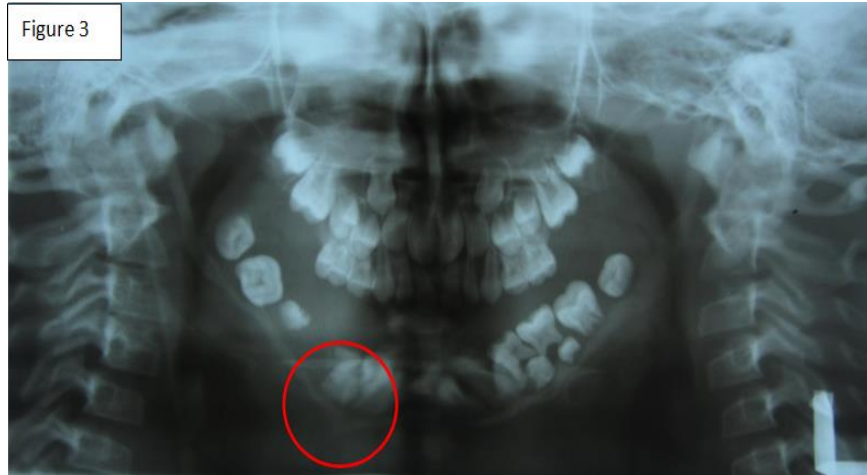

Fig. 3: Panoramic Radiograph

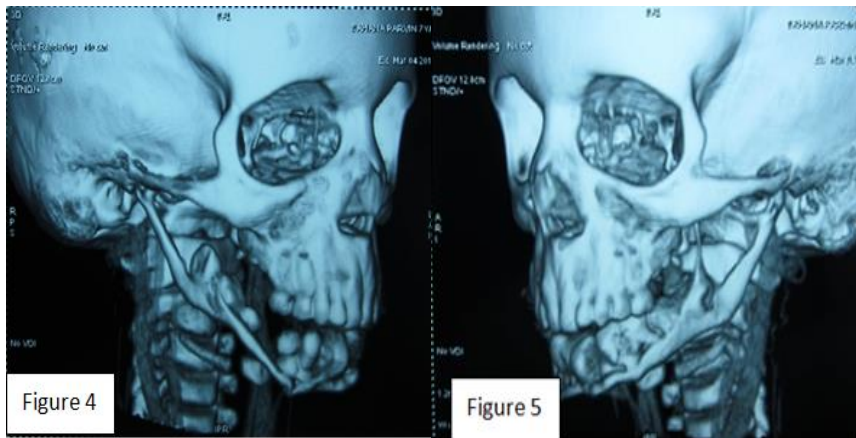


Fig. 4 & 5: 3dimensional computed tomography image

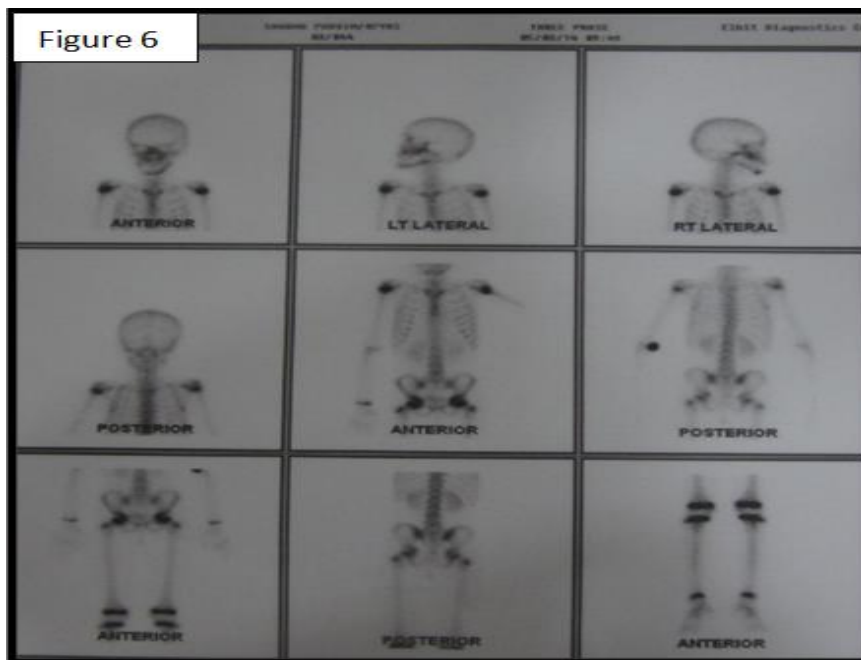


Fig. 6: Radioisotope scan

Discussion

The exact cause of Massive osteolysis still remains unknown, ongoing clinical research attempts to better understand the etiology of this bone disorder^[4]. Majority of cases remains unreported as most of the general dentists are unaware of this disorder. Massive osteolysis is usually monocentric but a locally aggressive condition, with resorption of the affected bone extending into the adjacent soft tissues^[5].

Heffez et al has described criteria for the diagnosis of massive osteolysis as^[47]:

1. Evidence of local progressive osseous resorption
2. Minimal or no osteoblastic response and an absence of dystrophic calcification
3. Non-expansile, non-ulcerative lesion
4. Absence of visceral involvement
5. Osteolytic radiographic pattern
6. Negative findings for a hereditary, metabolic, neoplastic, immunologic or infectious origin

The clinical presentation of massive osteolysis varies depending on the affected sites. Some patients have presented with a relatively abrupt onset of pain and swelling or a pathological fracture on the affected site, whereas others have presented with a history of an insidious onset of pain, limitation of motion and progressive weakness in the affected area^[35]. The disease is usually is not accompanied by any systemic symptoms^[52]. In majority of cases, the bone resorption process may stop spontaneously, and therefore the prognosis is generally good unless vital structures are involved.

A final diagnosis of massive osteolysis is difficult to arrive at. Laboratory findings are not specific and are of no value in the diagnostic procedure. Radiographs usually provide the most significant clues for obtaining a diagnosis. Johnson and McClure in 1958 first described the radiographic findings of patients with Massive osteolysis^[53]. During initial stages, the radiolucent foci appear in the intramedullary or subcortical regions with undisturbed margins. Subsequently, these foci coalesce and it eventually involve the cortex before slow progressive atrophy, dissolution, fracture, fragmentation and the disappearance of a portion of the bone occurs with a "tapering" or "pointing" of the remaining osseous tissue and atrophy of soft tissues. Progressive resorption of the mandible and the lytic process progress continues until the wispy

remnants of the bone remain. Computed tomography scanning and three-dimensional reconstruction are more useful for accurately assessing the range of bone destruction at the time of diagnosis. MRI (Magnetic Resonance Imaging) is used to define the involvement of the adjacent soft tissue and the extent of vascular formation. Radioisotopic scan may demonstrate increased vascularity on initial images and subsequently an area of decreased uptake corresponding to the site of diminished or absent osseous tissues^[10]. The radiographic findings in our case were typical of massive osteolysis.

The differential diagnosis of Gorham's disease is usually determined from other causes of osteolysis such as inflammatory disease (e.g., osteomyelitis), trauma, endocrine disease (e.g., hyperparathyroidism), rheumatoid arthritis, skeletal angiomas, angiosarcoma, and other malignancies. Differential diagnosis considered in our case were Langerhans cell histiocytosis, Papillon Lefevre syndrome, Hypophosphatasia and Cyclic neutropenia considering the extensive gingival lesions with tooth mobility. Langerhans cell histiocytosis is a rare disorder in pediatric population with teeth mobility, spontaneous bleeding and gingival lesions with systemic manifestations in over one third of patients affected. A histopathological investigation only can provide confirmatory results. Papillon lefevre syndrome is characterised by inflamed and swollen gingiva, bleeding on probing on slight provocation, mobility of teeth with typical dermal manifestations of hyperkeratotic papules on hands and soles which was absent in our patient ruling out the condition. Hypophosphatasia presents with early exfoliation of deciduous teeth and teeth present appear hypoplastic which doesn't go with the findings in our patient. Major presentations of cyclic neutropenia are oral ulcerations with gingivitis, periodontitis and a periodic recurring history of fever and malaise, which were not manifested in our case.

Due to the rarity of this disease, there is no standard therapy available. Treatment modalities usually include surgery, radiotherapy, etidronate therapy and the use of α -2b interferon^[1]. Now-a-days researches are being conducted regarding the potential use of stem cell therapy.

Conclusion

Controversy remains regarding the therapeutic procedure of Massive osteolysis, owing to the

rarity and progressive osteolysis of this disease, whereas reconstructive treatments are used in certain cases in an attempt to recover the function of the bone involved. It is a severe, poorly understood condition predominantly affecting children and young adults with consequential morbidity and mortality. The present case report emphasises that it is important for oral diagnosticians to be aware of the existence of this disease as a cause of osteolysis in the facial skeleton and tooth mobility in the dentition. Massive osteolysis can be as a rare differential diagnosis for lesions of facial skeleton. To the best of our knowledge, our case report represents the fourth case in the literature to document massive osteolysis in a female pediatric patient with mandibular involvement.

Acknowledgement

Sincere thanks to the entire team of Oral Medicine & Radiology in Vydehi Institute of Dental Sciences & Research institution for the support provided.

References

- Dong Q, Zhang Y, Sun C and Guo J. Gorham Stout syndrome affecting the left mandible: A Case Report. *Experimental and therapeutic medicine* 2013;5:162-164.
- Gondivkar SM, Gadbill AR: Gorham-Stout syndrome: a rare clinical entity and review of literature. *Oral Surg Oral Med Oral Pathol Oral Radiol Endod* 2010;109:41-48.
- Kotecha R, Mascarenhas L, Jackson H A, Venkatramani R. Radiological features of Gorhams disease. *Clinical Radiology* 2012; 67:782-788.
- Sharma A, Iyer N, Mittal A, Das D, Sharma S. Vanishing Mandible. *Journal of Oral Science*, 2010; 52(3):513-516.
- Ng SE, Wang YT. Gorham's syndrome with pleural effusion and colonic carcinoma. *Singapore Med J* 1995; 36:102-104.
- Römer O. Die Pathologie der Zahne, *Handbuch der Speziellen Pathologischen Anatomie und Histologie*. Vol 4. Berlin: Springer Verlag; 1924,135-499.
- Thoma KH. A case of progressive atrophy of the facial bones with complete atrophy of the mandible. *J Bone Joint Surg* 1933;15:494-501.
- Steenhuis DJ, Nauta JH. Osteolyse der ganzen mandibula durch chronische entzündung. *Röntgen-Praxis* 1936;8:607-9.
- Pasnikowski T, Grec S. Mandibular atrophy (Gorham's disease). Case report. *Pol Tyg Lek* 1960;15:1277-9.
- Knolle G, Meyer D. Massive osteolysis in the mandibular region caused by hemangiomas of the bone. *Dtsch Zahn Mund Kieferheilkd Zentralbl Gesamte* 1965;45:433-63.
- Hampton J, Arthur JF. Massive osteolysis affecting the mandible. *Br Dent J* 1966;120:538-41
- Ellis DJ, Adams TO. Massive osteolysis: report of case. *J Oral Surg* 1971;29:659-63.
- El-Mofty S. Atrophy of the mandible (massive osteolysis). *Oral Surg Oral Med Oral Pathol* 1971;31:690-700.
- Cherrick HM, King OH Jr, Dorsey JN Jr. Massive osteolysis (disappearing bone, phantom bone, acute absorption of bone) of the mandible and maxilla. *J Oral Med* 1972;27:67-74.
- Malter IJ. Massive osteolysis of the mandible: report of case. *J Am Dent Assoc* 1972;85:148-50.
- Phillips RM, Bush OB Jr, Hall HD. Massive osteolysis (phantom bone, disappearing bone). Report of a case with mandibular involvement. *Oral Surg Oral Med Oral Pathol* 1972;34:886-96.
- Kriens O. Progressive maxillofacial osteolysis. A case report. *Dentomaxillofac Radiol* 1973;2:73-80.
- Black MJ, Cassisi NJ, Biller HF. Massive mandibular osteolysis. *Arch Otolaryngol* 1974;100:314-6.
- Booth DF, Burke CH. Massive osteolysis of the mandible: an attempt at reconstruction. *J Oral Surg* 1974;32:787-91.
- Cadenat H, Bonnefont J, Barthelemy R, Fabie M, Combelles R. [The phantom mandible.] *Rev Stomatol Chir Maxillofac* 1976;77:877-89.
- Murphy JB, Doku HC, Carter BL. Massive osteolysis: phantom bone disease. *J Oral Surg* 1978;36:318-22.
- Heuck F. Case report 78. *Skeletal Radiol* 1979;3:241-3.
- Frederiksen NL, Wesley RK, Sciubba JJ, Helfrick J. Massive osteolysis of the maxillofacial skeleton: a clinical, radiographic, histologic, and ultrastructural study. *Oral Surg Oral Med Oral Pathol* 1983;55:470-80.
- Heffez L, Doku HC, Carter BL, Feeney JE. Perspectives on massive osteolysis. Report of a case and review of the literature. *Oral Surg Oral Med Oral Pathol* 1983;55:331-43.
- Mathias K, Hoffmann J, Martin K. Gorham-Stout syndrome of the mandible. *Radiologe* 1986;26:439-41.
- Takeda Y, Kuroda M, Suzuki A, Fujioka Y, Takayama K. Massive osteolysis of the mandible. *Acta Pathol Jpn* 1987;37:677-84.
- Anavi Y, Sabes WR, Mintz S. Gorham's disease affecting the maxillofacial skeleton. *Head Neck* 1989;11:550-7.
- Fisher KL, Pogrel MA. Gorham's syndrome (massive osteolysis): a case report. *J Oral Maxillofac Surg* 1990;48:1222-5.
- Ohya T, Shibata S, Takeda Y. Massive osteolysis of the maxillofacial bones. Report of two cases. *Oral Surg Oral Med Oral Pathol* 1990;70:698-703.
- Freedly RM, Bell KA. Massive osteolysis (Gorham's disease) of the temporomandibular joint. *Ann Otol Rhinol Laryngol* 1992;101:1018-20.
- Ohnishi T, Kano Y, Nakazawa M, Sakuda M. Massive osteolysis of the mandible: a case report. *J Oral Maxillofac Surg* 1993;51:932-4.
- Kayada Y, Yoshiga K, Takada K, Tanimoto K. Massive osteolysis of the mandible with subsequent obstructive sleep apnea syndrome: a case report. *J Oral Maxillofac Surg* 1995;53:1463-5.
- Moore MH, Lam LK, Ho CM. Massive craniofacial osteolysis. *J Craniofac Surg* 1995;6:332-6.
- Diaz-Ramon C, Fernandez-Latorre F, Revert-Ventura A, Mas- Estelles F, Domenech-Iglesias A, et al. Idiopathic progressive osteolysis of craniofacial bones. *Skeletal Radiol* 1996;25:294-7.
- Klein M, Metelmann HR, Gross U. Massive osteolysis (Gorham- Stout syndrome) in the maxillofacial region: an unusual manifestation. *Int J Oral Maxillofac Surg* 1996;25:376-8.
- Holroyd I, Dillon M, Roberts GJ. Gorham's disease: a case (including dental presentation) of vanishing bone disease. *Oral Surg Oral Med Oral Pathol Oral Radiol Endod* 2000;89:125-9.

37. Oujilal A, Lazrak A, Benhalima H, Boulaich M, Amarti A, Saidi A, et al. [Massive lytic osteodystrophy or Gorham-Stout disease of the craniomaxillofacial area.] *Rev Laryngol Otol Rhinol* 2000;121:255-60.
38. Hirayama T, Sabokbar A, Itonaga I, Watt-Smith S, Athanasou NA. Cellular and humoral mechanisms of osteoclast formation and bone resorption in Gorham-Stout disease. *J Pathol* 2001;195:624-30.
39. Plontke S, Koitschev A, Ernemann U, Pressler H, Zimmermann R, Plasswilm L. [Massive Gorham-Stout osteolysis of the temporal bone and the craniocervical transition.] *HNO* 2002;50:354-7.
40. Kawasaki K, Ito T, Tsuchiya T, Takahashi H. Is angiomatosis an intrinsic pathohistological feature of massive osteolysis? Report of an autopsy case and a review of the literature. *Virchows Arch* 2003;442:400-6.
41. Lee S, Finn L, Sze RW, Perkins JA, Sie KC. Gorham Stout syndrome (disappearing bone disease): two additional case reports and a review of the literature. *Arch Otolaryngol Head Neck Surg* 2003;129:1340-3.
42. Ricalde P, Ord RA, Sun CC. Vanishing bone disease in a five year old: report of a case and review of the literature. *Int J Oral Maxillofac Surg* 2003;32:222-6.
43. Paley MD, Lloyd CJ, Penfold CN. Total mandibular reconstruction for massive osteolysis of the mandible (Gorham-Stout syndrome). *Br J Oral Maxillofac Surg* 2005;43:166-8.
44. Escande C, Schouman T, Françoise G, Haroche J, Menard P. Histological features and management of a mandibular Gorhams disease: a case report and review of maxillofacial cases in literature. *Oral Surg Oral Med Oral Pathol Oral Radiol Endod* 2008;106:e30-e37.
45. Prasanna R, Sankar J, Ramachandran P. Gorhams disease: Vanishing bone syndrome. *Indian Pediatrics* 2009;46.
46. Lata J, Sharma R, Parmar M. Massive osteolysis of hemimandible: a case report. *J Maxillofac Oral Surg* 8(4):381-383.
47. Raghuvver HP, Jayalekshmy R. Gorhams Massive Osteolysis of Mandible: a progressive radiographic presentation. *Dentomaxillofacial Radiology* 2009;38:292-295.
48. Tong AC, Leung TM, Cheung PT. Management of massive osteolysis of the mandible: a case report. *Oral Surg Oral Med Oral Pathol Oral Radiol Endod* 2010;109:238-241.
49. Huang Y, Wang L, Wen Y, Zhang Q. Progressively bilateral resorption of mandible. *Journal of Cranio-Maxillo-Facial Surgery* 40 (2012) e174ee177.
50. Al-Jamali J, Glaum R, Kaseem A, Voss PJ. Gorham stout syndrome of the facial bones: a review of pathogenesis and treatment modalities and report of a case with a rare cutaneous manifestation. *Oral Surg Oral Med Oral Pathol Oral Radiol* 2012;114:e23-e29.
51. Toma MS, Al-khudari S, Schweitzer VG. A paediatric case of Gorham disease with extensive maxillofacial involvement. *Otolaryngology* 2013;3:139.
52. Rao P, Kotwal PP and Goel S: Painless destruction of the shoulder joint: a case report. *Clin Rheumatol* 2001;20:143-146.
53. Johnson PM, McClure JG. Observations of massive osteolysis radiology. *Radiology* 1958;71:28-42.
54. Speith ME, Greenspan A, Forrester DM, Ansari AN, Kimura RL, Gleason-Jordan I. Gorham's disease of the radius: radiographic, scintigraphic and MRI findings with pathologic correlation. A case report and review of literature. *Skeletal Radiol* 1997;26:659-663.