



Original Research Article

Soft palate morphology in OSMF patients: Radiographic evaluation

Jigna S Shah¹, Himali A Shah^{1,*}¹Dept. of Oral Medicine & Radiology, Government Dental College & Hospital, Ahmedabad, Gujarat, India

ARTICLE INFO

Article history:

Received 21-12-2020

Accepted 18-05-2021

Available online 14-07-2021

Keywords:

Oral submucous fibrosis

Radiographic evaluation

Morphology of soft palate

ABSTRACT

Introduction: Oral submucous fibrosis (OSMF) is a chronic progressive, scarring disorder of oral cavity, which includes buccal mucosa, tongue, lips, anterior faucial pillars, soft palate, and oropharynx. Changes in soft palate morphology will start even before the OSMF, present itself clinically. These changes can lead to sleep apnea, difficulty in speech, swallowing & respiration. Various radiographs are good diagnostic aid to assess the soft palate and its morphology or any changes in morphology.

Aim: To evaluate and compare soft palate morphology and dimensions in various stages of OSMF with control by radiographic evaluation.

Materials and Methods: 60 patients were evaluated and compared for soft palate morphology, its length, width and angle by using lateral cephalogram and Cone beam computed tomography (CBCT).

Results: Most common type of soft palate was found to be type 1 (leaf shaped) in both groups as well as by both radiographic techniques. Significant decrease in length and increase in width with increasing grades of OSMF group. As per p value CBCT gave more precise result.

Conclusion: As the OSMF progresses soft palate becomes stout and bulky and significant changes occur in soft palate dimensions and are better evaluated by CBCT. As involvement of the soft palate is the earliest change to be noticed, radiographs should be used as one of the diagnostic aids in OSMF patients.

© This is an open access article distributed under the terms of the Creative Commons Attribution License (<https://creativecommons.org/licenses/by/4.0/>) which permits unrestricted use, distribution, and reproduction in any medium, provided the original author and source are credited.

1. Introduction

Schwartz(1952) described a condition called "atrophiaidiopathica (tropica) mucosae oris", which was later termed as 'Oral Submucous fibrosis' (OSMF).^{1,2} According to Joshi(1953), involvement of the soft palate and faucial pillars is perhaps the earliest feature to develop in the natural course of OSMF.³ Haider et al. in 2000 concluded that the bands formed initially in the fauces, soft palate (91.4%), followed by buccal (72.4%) and retro-molar areas (70.7%), labial areas, and tongue(8.6%).⁴

Soft palate morphology can be assessed by various radiographic methods such as Lateral Cephalometry, computed tomography and cone beam computed tomography (CBCT).⁵⁻⁷

The aim of this study was to evaluate and compare soft palate morphology and dimensions in various stages of OSMF by taking LC and CBCT. Perhaps this would be first attempt where comparative evaluation was carried out in 2D and 3D radiographic technique.

2. Materials and Methods

The study was undertaken at Oral medicine and radiology department(OMRD), Government dental college and Hospital, Ahmedabad. Ethical approval and consent of all patients had been taken for study. Patients were explained about the purpose of study and its procedure. Total 60 patients were included in the study. Out of this, 30 patients of clinically diagnosed OSMF (group 1) and 30 patients non-OSMF(control-group 2) were selected. In group 2, patients who had been advised radiographs for prosthetic or endodontic purpose were selected. In group 1, out of 30

* Corresponding author.

E-mail address: himalishah06@gmail.com (H. A. Shah).

cases of OSMF, 10 cases of each mild, moderate and severe OSMF were selected. Very early OSMF patients were not selected as there will be minimal changes so as to minimize unnecessary radiographic exposure and extremely severe OSMF patients were not selected as inaccessibility to see any other etiology and inability to take proper radiograph. OSMF patients were diagnosed and selected as per clinical criteria of grading of OSMF given in Table 1. Subjects with history of trauma or fracture of head and neck, surgery of cleft lip and palate, trismus, systemic diseases, any syndromic cases, reduced mouth opening due to impacted third molar or any space infections, temporomandibular joint pathology, pregnant and lactating mothers, patient who underwent surgeries for carcinoma of soft palate, hard palate or tongue were excluded from the study. In the present study only newly clinically diagnosed cases of OSMF, who have not taken any treatment for OSMF were selected. [Table 1]

All selected subjects were evaluated by LC and CBCT taken on VATECH 3D imaging CBCT machine to see soft palatal changes. All the radiographs of OSMF patients were analyzed by using EzDent-I software for various parameters such as soft palate length (VL), width (VW), angle (AV) with control group.

Soft palate length, width and angle were determined by following method⁵ as shown in Figure 1.

During resting position of soft palate,

Velar length = Linear distance from posterior nasal spine to tip of uvula

VW (Velar Width) = Thickest section of velum

AV (Angle of velum): as angle formed between line joining from anterior nasal spine –posterior nasal spine and posterior nasal spine to tip of uvula

Soft palate morphology classification given by You et al.⁸ as shown below (Figure 2):

Type 1: “Leaf-shape,” which is lanceolate, indicating that the middle portion of the soft palate elevated to both the naso-and the oro-side.

Type 2: “Rat-tail shape.” When the soft palate anterior portion is bulged and the free margin has an coarctation.

Type 3: “Butt-like”, soft palate shows a shorter and fatter velum appearance, and the width has almost no distinct difference from the anterior portion to the free margin.

Type 4: “Straight line shape.” Soft palate shows a straight line.

Type 5: S-shape, the distortion of soft palate showing the S-shape.

Type 6: “crook” appearance, which reveals a “crook” appearance of the soft palate, in which the posterior portion of the soft palate crooks anterosuperiorly.

All these parameters were evaluated and compared as shown in figures and tables in results. (Tables 2, 3, 4 and 5)

3. Results

In this study, out of 30 patients in OSMF group, 20 were males & 10 were females. Maximum patients (70%) were found in the age group of 26-55years with male predominance followed by 13-25years (16.6%) & >55years (13.33%). Males have more habit of tobacco chewing. This age group patients usually have more complaints and visit more frequently to the hospital as compared to younger age groups.

3.1. Statistical analysis

After collection of data, the data was encoded and entered in Micro Soft Excel 2019. The proportion between the groups was compared by using Chi square test. The normality of the data was checked by using Shapiro-Wilk test. After applying Shapiro-Wilk test the data for length and width were not normally distributed as $P < 0.05$. So non parametric tests were applied, while parametric test was used to compare mean values of angle as it was normally distributed $P > 0.05$. The data were expressed in mean and standard deviation. The mean values between two groups were compared by using Mann Whitney U test and independent t test as and where appropriate. The mean values among the group were compared by using Kruskal Wallis test and one way ANOVA test as and where appropriate. Statistical Package of Social Science (SPSS, IBM) version 23 was used for statistical analysis. Level of significance was kept at 5%.

Tables 2 and 3 showed the result of soft palate morphology. Most common type of soft palate noted was type-1 (leaf shaped) in both OSMF and control groups with p-value 0.19 and 0.32 in LC and CBCT respectively. In OSMF type 2 was noted in 2 patients in LC and 3 patients in CBCT whereas type 3 was noted in 3 patients in LC and 2 patients in CBCT. Only one case of type 5 and 4 was found in LC and CBCT respectively. Type 2 and 3 were more commonly found as OSMF stage progressed with p value of 0.77 and 0.42 in LC and CBCT respectively. It indicates as the disease progresses soft palate becomes stout and bulky.

Table 4 showed there was significant decrease in length of soft palate in OSMF group as compared to control group with p value of 0.001 in LC. LC was not significant in width and angle as p values were 0.26 and 0.59 respectively. While CBCT was significant in length, width and angle with p values of 0.01 for length and width and 0.04 for angle. Thus, there was significant decrease in length and increase in width in OSMF group as compared to control group.

Table 5 showed as the OSMF stage advances the length of soft palate decreases and width increases. It was non-significant in LC with p values of 0.13, 0.44 and 0.61 for length, width and angle respectively for mild, moderate and severe stages of OSMF. CBCT gave significant results for length and width with p values of 0.01. It was non-significant for angle with p value of 0.60.

Table 1: Clinical criteria for grading of OSMF stages

Grading of OSMF	Clinical criteria
Grade I (Very Early OSMF)	Burning sensation on hot and spicy food; Pale and blanched buccal mucosa without fibrosis; Blanching(white fibrotic band) at the junction of hard and soft palate; History of vesicle/ulcer formation; No restriction of mouth opening
Grade II (Mild OSMF)	Burning sensation on hot and spicy food; Along with blanching, buccal mucosa appears thick, mottled and marble type; Fibrosis of faucial pillars, pterygomandibular raphae and soft palate; Mouth opening- 25-35mm
Grade III (Moderate OSMF)	Burning sensation on hot and spicy food; Fibrosis of buccal mucosa, faucial pillars, pterygomandibular raphae and soft palate extends anteriorly to involve labial mucosa, floor of the mouth and tongue; Tongue movements are restricted to some extents; Loss of flexibility of buccal mucosa; Mouth opening 15mm to 25mm
Grade IV (Severe OSMF)	Burning sensation on absence of stimuli; Severe fibrosis of entire oral cavity; Severe restriction of tongue movements; Severe loss of flexibility of buccal mucosa; Circular band (fibrotic rim) around lips and mouth; Fibrosis of soft palate and shrunken uvula; Difficulty in swallowing and deglutition; Difficulty in speech and nasal voice; Restricted mouth opening less than 15mm
Grade V (Extreme severe OSMF)	All findings of severe OSMF are present along with complete trismus; Loss of puffiness of face and loss of vertical dimension.

Table 2: Distribution of soft palate type in OSMF and control group in LC and CBCT

Types of soft palate	LC(N=60)		CBCT(N=60)	
	OSMF (n=30)	Control (n=30)	OSMF (n=30)	Control (n=30)
Type 1	24	29	24	28
Type 2	02	01	03	02
Type 3	03	-	02	-
Type 4	-	-	01	-
Type 5	01	-	-	-
Type 6	-	-	-	-
P value	0.19		0.32	

LC=lateral cephalogram CBCT=Cone beam computed tomography

P>0.05 statistically not significant

Table 3: Distribution of type of soft palate in different clinical stage of OSMF by using LC & CBCT

Type of Soft Palate	Stage of OSMF						Total (n=30)	
	Mild (n=10)		Moderate (n=10)		Severe (n=10)		LC	CBCT
	LC	CBCT	LC	CBCT	LC	CBCT		
Type 1	9 (30.0)	10(33.30)	7 (23.30)	8(26.70)	8 (26.70)	6(20.0)	24 (80.0)	24(80.0)
Type 2	0	0	1 (3.30)	1(3.30)	1 (3.30)	2(6.70)	2 (6.70)	3(10.0)
Type 3	1 (3.30)	0	1 (3.30)	1(3.30)	1 (3.30)	1(3.30)	3 (10.0)	2(6.70)
Type 4	0	0	0	0	0	1(3.30)	0	1(3.30)
Type 5	0	0	1 (3.30)	0	0	0	1 (3.30)	0
Type 6	0	0	0	0	0	0	0	0

P value: 0.77 for LC 0.42 for CBCT

4. Discussion

Oral submucous fibrosis (OSMF) is a chronic progressive disorder of oral cavity, which includes buccal mucosa, tongue, lips, anterior faucial pillars, soft palate, and oropharynx. OSMF is a highly potent and one of the most common premalignant conditions. 2.5 million people were affected with OSMF worldwide, which has risen to 5 million on the Indian subcontinent.² Dysplasia in OSF may range from 12 to 15%. The malignant transformation rate has been found to be 4–13% worldwide, whereas 7.6% in Indian population.² Changes in soft palate morphology

will start even before the OSMF, present itself clinically. Various radiographs are good diagnostic aid to assess the soft palate and its morphology or any changes in morphology, which can lead to various conditions such as obstructive sleep apnea, difficulty in swallowing, speech, and respiration.⁹ Cephalometry is a relatively inexpensive method and permits a good assessment of the soft tissue elements that defines the soft palate and its surrounding structures.¹ Lateral Cephalogram(LC) & CBCT is useful to see soft palate morphology as well as parameters like its length, width, angle can also be measured as it

Table 4: Comparison of mean dimension between OSMF and control group by using LC & CBCT

Parameters	OSMF (n=30)						Control (n=30)						P Value	
	Mean ± SD			Median			Mean ± SD			Median			LC	CBCT
	LC	CBCT	LC	CBCT	LC	CBCT	LC	CBCT	LC	CBCT	LC	CBCT		
Length	28.40 ± 4.85	30.57 ± 5.01	29.56	31.25	32.23 ± 1.83	33.34 ± 2.05	32.57	33.61	32.57	33.61	0.001 ^a	0.01 ^a		
Width	11.83 ± 1.82	11.62 ± 1.51	11.38	11.50	11.15 ± 1.15	10.69 ± 1.04	11.33	10.64	11.33	10.64	0.26 ^a	0.01 ^a		
Angle	127.27 ± 8.14	125.75 ± 8.33	127.91	125.55	128.13 ± 3.60	129.43 ± 4.25	127.56	129.67	127.56	129.67	0.59 ^b	0.04 ^{a,b}		

Data presented in mean ± standard deviation. ^a Mean values were compared by using Mann Whitney U test; ^b Mean values were compared by using independent t test. *P<0.05 statistically significant

Table 5: Comparison of mean dimension by using LC & CBCT according to severity of OSMF

Parameters	Mild (n=10)						Moderate (n=10)						Severe (n=10)						P Value	
	Mean ± SD			Median			Mean ± SD			Median			Mean ± SD			Median			LC	CBCT
	LC	CBCT	LC	CBCT	LC	CBCT	LC	CBCT	LC	CBCT	LC	CBCT	LC	CBCT	LC	CBCT	LC	CBCT		
Length	31.01 ± 2.23	34.29 ± 3.41	31.03	33.60	28.56 ± 4.49	29.65 ± 3.96	25.63 ± 5.86	27.76 ± 5.33	29.48	29.65	29.65	29.65	25.63 ± 5.86	27.76 ± 5.33	23.03	28.05	0.13 ^a	0.01 ^a		
Width	11.51 ± 1.88	10.62 ± 1.08	11.05	10.60	11.76 ± 2.09	11.67 ± 1.05	12.24 ± 1.65	12.58 ± 1.72	11.40	11.25	11.25	12.24 ± 1.65	12.58 ± 1.72	12.25	12.15	12.15	0.44 ^a	0.01 ^a		
Angle	125.18 ± 9.29	123.67 ± 5.95	127.43	124.05	128.82 ± 5.49	127.47 ± 6.74	127.81 ± 9.44	126.11 ± 11.59	129.74	126.35	126.35	127.81 ± 9.44	126.11 ± 11.59	126.75	120.90	120.90	0.61 ^b	0.60 ^b		

Data presented in mean ± standard deviation. ^a Mean values were compared by using Kruskal Wallis test; ^b Mean values were compared by using one way ANOVA test. P>0.05 statistically not significant.

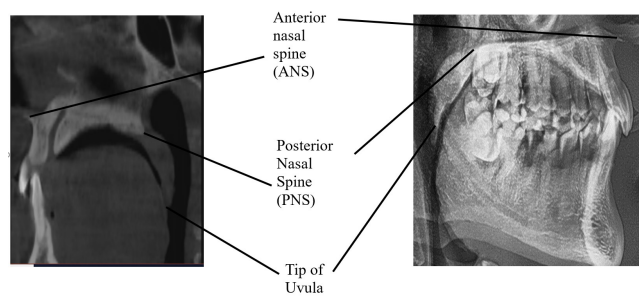


Fig. 1: CBCT (left) and Lateral Cephalogram (right) showing landmarks for measuring VL, VW and AV

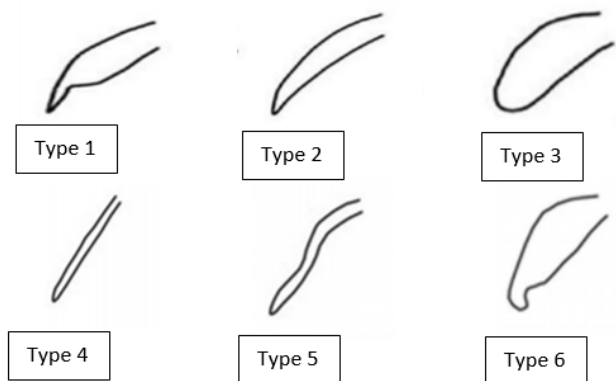


Fig. 2: Morphology of soft palate

shows sagittal view of soft palate.⁵⁻⁷ CBCT provides three dimensional view of soft palate without superimposition and gives actual direct measurements. Better understanding of soft palate morphology and functional abnormality would play a significant role in the success of orthodontic treatment and obstructive sleep apnea, speech abnormality and other related disorders.¹⁰

Our findings suggest that type 1 soft palate is most common in Indian population, whether it is OSMF or non-OSMF patient. Also Domir SK et al² found no significance difference in soft palate morphology between control and OSMF group. Certain studies done on normal patients to evaluate soft palate morphology and type 1 was found to be most common.^{8,11,12} Khare P et al.¹³ also found type 1 soft palate most common in OSMF group using CBCT. Patil, et al¹⁴ found type-1, 6 and 3 to be most common in early, moderate and severe stage of OSMF respectively. Knowledge of alteration in soft palate morphology in radiographic imaging may be helpful in the very early stage of OSMF.¹³

Palatal morphology is altered in OSMF mainly due to 2 reasons:¹³

1. Dimensional changes of soft palatal length, width and angle due to fibrosis.
2. Altered direction of palatal uvula.

Soft palate plays a very crucial role in velopharyngeal closure, that is, approximation of soft palate with pharyngeal walls. This sphincter mechanism separates nasal and oral cavity during speech and deglutition. Thus, changes occur in palatal morphology in OSMF can lead to altered voice and in advance stages difficulty in speech and difficult deglutition. Especially S shaped and hooked shaped soft palate exhibit greater chance of developing sleep apnea and velopharyngeal insufficiency.⁵ Our results were in accordance with Nerkar A et al.⁵ and Deshmukh E et al.¹⁵ Khare P et al.¹³ found only significant width changes between OSMF and control groups using CBCT.

We can say that CBCT is more useful to show length and width changes in OSMF patients. Findings of length, width & angle changes were in accordance with Raja Lakshmi et al,¹⁶ Tekchandani et al.¹ Angle was not measured in their study. Tekchandani et al.¹ compared clinical and histological grades of OSMF with radiographic variables.

This study can aid to observe the extent of disease progress, to devise a comprehensive treatment plan with regards to the morphological and anatomic corrections of the soft palate, postsurgical speech therapy and treatment of associated dysphagia. Knowledge about the varied morphological pattern of soft palate in OSMF patients can give us a clear understanding about disease progress in oropharyngeal region. Thorough understanding and knowledge of associated changes will help in successful structural and functional corrections associated with this disorder.¹

As clinically we can only see shrunken or deviated uvula, this method provides all changes of soft palate in OSMF patient. One can measure airway space also using this method. Gaining meticulous knowledge regarding changes in soft palate morphology due to OSMF will be helpful for proper diagnosis and successful structural and functional outcome.⁵

5. Conclusion

As the OSMF progresses soft palate becomes stout and bulky and significant changes occur in soft palate dimensions and are better evaluated by CBCT. As involvement of the soft palate is the earliest change to be noticed, radiographs should be used as one of the diagnostic aids in OSMF patients. Significant correlation exists between the variants of soft palate in different population in normal as well as diseased state.

6. Source of Funding

None.

7. Conflict of Interest


The authors declare that there is no conflict of interest.

References

1. Tekchandani V, Thakur M, Palve D, Mohale D, Gupta R. Co-relation of clinical and histologic grade with soft palate morphology in oral submucous fibrosis patients: A histologic and cephalometric study. *J Dent Spec*. 2015;15(1):68–75.
2. Domir SK, Gargava A, Deoghare A, Agrawal R. Morphometric Evaluation of Soft Palate in OSMF Patients Using Cephalometrics. *Indian J Otolaryngol Head Neck Surg*. 2019;71(S1):1018–22. doi:10.1007/s12070-019-01702-1.
3. Joshi SG. Submucous fibrosis of the palate and pillars. *Indian J Otolaryngol*. 1953;4(1):1–4.
4. Haider SM, Merchant AT, Fikree FF, Rahbar MH. Clinical and functional staging of oral submucous fibrosis. *Br J Oral Maxillofac Surg*. 2000;38(1):12–5. doi:10.1054/bjom.1999.0062.
5. Nerkar A, Gadgil R, Bhoosreddy A, Bhadage C, Vedpathak P. Comparative morphometric analysis of soft palate between OSMF and normal individuals: A digital cephalometric study. *Int J Maxillofac Imaging*. 2017;3(1):1–7.
6. Elkunchwar G, Gulve N, Nehete A, Shah K, Aher S. Evaluation of airway in different types of soft palate according to growth pattern. *Int Organ Sci Res J Dent Med Sci*. 2018;17:53–8.
7. Shankar VN, Hegde K, Ashwini NS, Praveena V, Prakash SMR. Morphometric evaluation of soft palate in oral submucous fibrosis—A digital cephalometric study. *J Cranio-Maxillofac Surg*. 2014;42(1):48–52. doi:10.1016/j.jcms.2013.02.001.
8. You M, Li X, Wang H, Zhang J, Wu H, Liu Y, et al. Morphological variety of the soft palate in normal individuals: a digital cephalometric study. *Dentomaxillofac Radiol*. 2008;37:344–9. doi:10.1259/dmfr/55898096.
9. Rathore S, Patil N, Sareen M, Meena M, Baghla P, Tyagi N. Morphological evaluation of soft palate in various stages of oral submucous fibrosis and normal individuals: A digital cephalometric study. *J Indian Acad Oral Med Radiol*. 2019;31:51.
10. Bhambri E, Ahuja V, Ahuja S, Bhambri G, Choudhary A, Sukhija S. The association between soft palate shape and Need's ratio in various sagittal skeletal malocclusions: A digital lateral cephalometric study. *Int J Orthod Rehabil*. 2018;9(1):8. doi:10.4103/ijor.ijor_41_17.
11. Agrawal P, Gupta A, Phulambrikar T, Singh SK, Sharma BK, Rodricks D. A focus on variation in morphology of soft palate using cone-beam computed tomography with assessment of Need's ratio in central Madhya Pradesh population. *J Clin Diagn Res*. 2016;10(2):68.
12. Khaitan T, Pachigolla R, Uday G, Balmuri PK, Chennou SK, Pattipati S. Digital cephalometric analysis illustrating morphological variation of the soft palate. *J Indian Acad Oral Med Radiol*. 2015;27:532. doi:10.4103/0972-1363.188745.
13. Khare P, Reddy R, Gupta A, Sharva V, Gupta M, Singh P. Morphometric assessment of soft palate in oral submucous fibrosis using cone beam computed tomography: A cross-sectional study. *J Indian Acad Oral Med Radiol*. 2019;31:203. doi:10.4103/jiaomr.jiaomr_121_19.
14. Patil BM, Ara SA, Katti G, Ashraf S, Roohi U. Velar morphological variants in oral submucous fibrosis: A comparative digital cephalometric study. *Indian J Dent Res*. 2017;28(6):623. doi:10.4103/ijdr.ijdr_275_16.
15. Deshmukh RA, Bagewadi AS. Morphometric evaluation and comparison of soft palate in individuals with and without oral submucous fibrosis: A digital cephalometric study. *SRM J Res Dent Sci*. 2015;6(4):220. doi:10.4103/0976-433x.170245.
16. Lakshmi CR, Thabusum DA, Bhavana SM. An Innovative Approach to Evaluate the Morphological Patterns of Soft Palate in Oral Submucous Fibrosis Patients: A Digital Cephalometric Study. *Int J Chronic Dis*. 2016;2016:1–6. doi:10.1155/2016/5428581.

Author biography

Jigna S Shah, Professor and Head

Himali A Shah, PG Student  <https://orcid.org/0000-0003-0712-9387>

Cite this article: Shah JS, Shah HA. Soft palate morphology in OSMF patients: Radiographic evaluation. *IP Int J Maxillofac Imaging* 2021;7(2):74–79.