



## Case Report

# Coronoid hypoplasia with developmental anomaly: A rare clinical-radiographic finding

Shilpa J Parikh<sup>1</sup>, Harmi P Patel<sup>1,\*</sup>, Jigna S Shah<sup>1</sup>

<sup>1</sup>Dept. of Oral Medicine and Radiology, Government Dental College and Hospital, Ahmedabad, Gujarat, India



### ARTICLE INFO

#### Article history:

Received 01-06-2021

Accepted 21-06-2021

Available online 14-07-2021

#### Keywords:

Coronoid hypoplasia

Condylar hypoplasia

Developmental disorders

TMJ

### ABSTRACT

A unique case of unilateral coronoid and condylar hypoplasia in 11 year old male patient who presented with progressive facial asymmetry is reported here. It is very rare developmental anomaly, usually condylar hypoplasia is found with coronoid hyperplasia. The patient reported here with complain of facial asymmetry. Clinical examination, conventional radiographs, and three dimensional computed tomography images revealed hypoplasia of both coronoid process and condyle on left side. Early diagnosis by correlating clinical and imaging features is paramount in the management of such patients.

© This is an open access article distributed under the terms of the Creative Commons Attribution License (<https://creativecommons.org/licenses/by/4.0/>) which permits unrestricted use, distribution, and reproduction in any medium, provided the original author and source are credited.

## 1. Introduction

The condyle is necessary for mandibular growth.<sup>1</sup> Morphologic changes may occur on the basis of developmental variability and remodeling.<sup>2</sup> Condylar hypoplasia characterized by the decreased development of the mandibular condyles. It shows progressive facial asymmetry, usually asymptomatic.

The coronoid process gives attachment to muscles of mastication (temporalis and masseter) which shows morpho-functional dependence.<sup>3</sup> The posterior muscles near temporalis helps in development of condyle and coronoid process, and may result in hyperplasia or hypoplasia. It's size influenced mainly by the activity of the temporalis muscle, dietary habit, genetic constitution, and hormones.<sup>4</sup> Coronoid hypoplasia is a defective or underdeveloped coronoid process which is considered to be extremely rare. No definite clinical findings were mentioned in literatures. A unique case of non syndromic developmental unilateral coronoid and condylar hypoplasia associated with ankyloglossia is presented here. The diagnosis is arrived by a correlation of clinical findings with

imaging features. This case highlights the importance of imaging in arriving diagnosis.

## 2. Case Report

11-year-old male child represented to department of oral medicine and radiology with chief complaint of facial asymmetry. Patient was relatively asymptomatic before 10 years, at the age of 1 year they noticed facial asymmetry which was gradually increasing. No any systemic illness was reported.

On extraoral examination, obvious facial asymmetry on left side with chin deviated to the same side during mouth opening was noticed without restricted mouth opening. There was flattening of ramus, deepening of antegonial notch, retruded chin on left side.(Figure 1) There was underdeveloped tragus and small nodules anterior to tragus was noticed. No restriction of TMJ movements, tenderness in muscles of mastication and clicking sound were present.

On Intra-oral examination, Patient had mixed dentition with Angle's class I molar relation with midline shift on right side and the cant of the occlusal plane was tilted to the left. Ankyloglossia was also noticed. (Figure 1) Provisional diagnosis of condylar hypoplasia on left

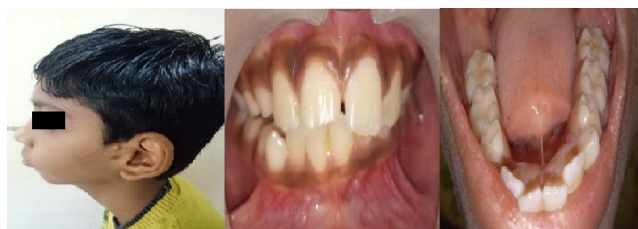
\* Corresponding author.

E-mail address: [patelharmi220@gmail.com](mailto:patelharmi220@gmail.com) (H. P. Patel).

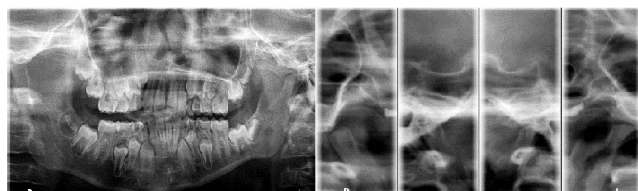
side was considered. Fibrous TMJ ankylosis and Facial hemiatrophy were kept as differential diagnosis.

OPG revealed mixed dentition, decreased height of left mandibular ramus, decreased height and mesiodistal diameter of head of left condyle with underdeveloped left coronoid process suggestive of coronoid and condylar hypoplasia. TMJ OPG (left) also showed hypoplastic coronoid process and condyle. (Figure 2)

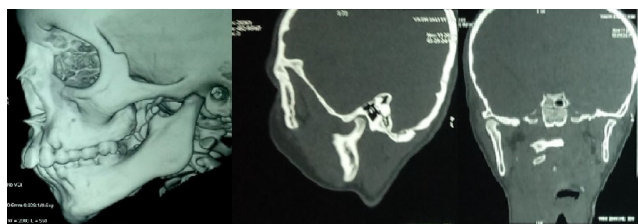
The 3D CT scan of head and neck region confirmed the findings of panoramic radiograph. (Figure 3) After radiographic confirmation patient was advised complete systemic evaluation and referred to general medicine, cardiology, ophthalmology, ENT, and orthopedics to rule out any syndromes. Medical evaluation revealed no abnormalities. Final diagnosis of developmental coronoid and condylar hypoplasia of left side with ankyloglossia was given. Patient was referred to department of oral surgery for further management.



**Fig. 1:** Showing extraoral and intraoral findings



**Fig. 2:** OPG, TMJ OPG showing hypoplasia of coronoid process and condyle on left side



**Fig. 3:** CT scan shows underdeveloped coronoid process and condyle on left side

### 3. Discussion

TMJ disorders cannot be diagnosed only on basis of clinical examinations. An imaging assessment of TMJ is

helpful to graphically depict clinically suspected disorders of the joint. Panoramic and postero-anterior radiograph are useful for surveying the shapes of the mandibular rami and condyles on both sides. The lateral radiograph provides information about ramal height and mandibular condyle length. However, conventional radiography should be used with caution in making measurement of anatomic structures. Advanced imaging techniques like 3D CT or CBCT must be considered in the investigation of the osseous morphology of TMJ.

Coronoid hypoplasia is a rare entity with an unclear etiopathogenesis. It is usually considered as a developmental abnormality due to activity of the temporalis muscle in prenatal and early postnatal life. However, it has also been suggested that coronoid hypoplasia may occur in individuals with unchanged muscle activity.<sup>4,5</sup> There is no definite clinical findings and management of coronoid hypoplasia is mentioned in different literatures. As per our knowledge, only four cases of coronoid hypoplasia is reported in literature till now. First case in 1978, reported by Gorlin et.al, coronoid hypoplasia in a patient with Melnick-Needles syndrome.<sup>6</sup> In 2002, Nedim et.al found case of isolated bilateral mandibular coronoid hypoplasia in 33 year old female.<sup>7</sup> Other two cases were reported in 2015, Kudva et.al reported case of an isolated bilateral coronoid hypoplasia in 24 year old male<sup>4</sup> and case of bilateral coronoid hypoplasia associated with complex odontoma in 20 year old female patient is reported by Mohd et al.<sup>5</sup> congenital deformities and developmental abnormalities of mandibular condyle can be classified as hypoplasia or aplasia, hyperplasia, and bifidity. Hypoplasia or aplasia of the mandibular condyle indicates underdevelopment or non development associated with various craniofacial abnormalities. These may be either congenital or acquired.<sup>8</sup> Congenital condylar hypoplasia is characterized by unilateral or bilateral underdevelopment of the mandibular condyle and occurs as a part of systemic condition originating in the first and second branchial arches, such as Treacher Collins syndrome, Pierre Robin syndrome, Hemifacial microsomia, Goldenharsyndrome, Hallermann-Streiff syndrome, Hurler's syndrome, Proteus syndrome, Morquio syndrome and Auriculocondylar syndrome. Acquired condylar hypoplasia takes place if condyle is injured during active growth, because of which development may be arrested. The most common causes are mechanical injury, such as trauma, infection of joint itself or the middle ear, childhood rheumatoid arthritis, radiotherapy, and parathyroid hormone-related protein deficiency.<sup>1</sup> In condylar hypoplasia, affected side fails to grow downward and forward leading to three-dimensional asymmetry. The mandibular skeletal midline deviates to affected side, a lack of vertical growth on same side produces a can't of occlusal plane, and mandibular retrognathia is seen as a result of the

hypoplasia.<sup>9</sup> The severity of the deformity depends on the degree of hypoplasia or agenesis of tissues involved, and more severe the deformity, greater the probability that it will worsen with growth.

Plain film radiography is generally inadequate for assessing disorders of the TMJ. Three dimensional imaging in form of CT or Cone Beam Computed Tomography (CBCT) must be considered in the investigation of osseous morphology of TMJ. In the present case report, clinical and radiographic features were similar to the cases discussed in various literatures.<sup>4–7,9</sup>

Various treatment approaches have been proposed. It is treated by multimode with the help of oral surgeon, general surgeon, plastic surgeon, and orthodontist. Treatment consists of surgical shortening of the unaffected side of the mandible or lengthening of the affected side with costochondral graft transplant, preferably before growth spurt, orthognathic surgery at the end of the growth period, or both.<sup>1</sup>

#### 4. Conclusion

In literature, condylar hypoplasia was found usually associated with coronoid hyperplasia. Coronoid hypoplasia is a rare developmental abnormality of oral and maxillofacial region. Here, we came across a unique case of coronoid and condylar hypoplasia affecting same side. Careful history, clinical, and radiographic examination will usually reveal the true nature of these conditions. As these conditions can cause challenges in diagnosis, they have to be carefully differentiated with other similar conditions and syndromes for planning and initiating the proper treatment modality for both functional activity and esthetic appearance.

#### 5. Source of Funding

None.

#### 6. Conflict of Interest

The authors declare that there is no conflict of interest.

#### References

1. Shivhare P, Shankarnarayan L, Kumar M, Sowbhagya MB. Condylar aplasia and hypoplasia: A rare case. *Case Rep Dent.* 2013;doi:10.1155/2013/745602.
2. Hegde S, Praveen BN, Shetty SR. Morphological and radiological variations of mandibular condyles in health and diseases: a systematic review. *Dentistry.* 2013;03(01):154. doi:10.4172/2161-1122.1000154.
3. Nayak S, Patra S, Singh G, Mohapatra C, Rath S. Study of the size of the coronoid process of mandible. *J Anat Soc India.* 2016;65(6):S2–S3. doi:10.1016/j.jasi.2016.08.014.
4. Kudva A, Chowdhary S, Kamath AT, Cariappa KM. Bilateral hypoplasia of the coronoid process. *Br J Oral Maxillofac Surg.* 2016;54:114. doi:10.1016/j.bjoms.2015.10.032.
5. Dar MA, Alaparathi R, Yalamanchili S, Santosh AB. Bilateral coronoid hypoplasia and complex odontoma: a rare concurrence of developmental pathology and odontogenic tumour of the mandible. *BMJ Case Rep.* 2015;2015:bcr2015212022. doi:10.1136/bcr-2015-212022.
6. Gorlin RJ, Langer LO. Melnick-Needles Syndrome: Radiographic Alterations in the Mandible. *Radiology.* 1978;128(2):351–3. doi:10.1148/128.2.351.
7. Sarifakioğlu N, Ateş L, Aslan G, Terzioğlu A. Bilateral mandibular coronoid hypoplasia. *J Oral Maxillofac Surg.* 2002;60(1):131. doi:10.1053/joms.2002.30238.
8. Punyani SR, Jasuja VR. Unilateral acquired condylar hypoplasia and coronoid hyperplasia of the mandible. *Med J Dr DY Patil Univ.* 2017;10(2):198. doi:10.4103/0975-2870.202093.
9. Arun T, Kayhan F, Kiziltan M. Treatment of condylar hypoplasia with distraction osteogenesis: a case report. *Angle Orthod.* 2002;72:371–6.

#### Author biography

**Shilpa J Parikh**, Professor

**Harmi P Patel**, Postgraduate Student

**Jigna S Shah**, Professor and HOD

**Cite this article:** Parikh SJ, Patel HP, Shah JS. Coronoid hypoplasia with developmental anomaly: A rare clinical-radiographic finding. *IP Int J Maxillofac Imaging* 2021;7(2):80-82.