



Case Report

Prosthetic management of an adult cleft patient with velopharyngeal appliance and airway evaluation by acoustic pharyngometry

Pramod K Chahar¹, Abir Sarkar², Vaibhav Jain^{3,*}, Vishvnathe Udayshankar⁴

¹Dept. of Prosthodontics and Crown & Bridge, Military Dental Centre, Roorkee, Uttarakhand, India

²Dept. of Prosthodontics and Crown & Bridge, Military Dental Centre, Meerut, Uttar Pradesh, India

³Dept. of Prosthodontics and Crown & Bridge, INDC Danteshwari, Mumbai, Maharashtra, India

⁴Dept. of Prosthodontics and Crown & Bridge, Military Dental Centre, Wellington, Tamil Nadu, India



ARTICLE INFO

Article history:

Received 18-06-2021

Accepted 21-06-2021

Available online 14-07-2021

Keywords:

Cleft palate

Obturator

Speech aid prosthesis

Velopharyngeal insufficiency

Acoustic pharyngometry

ABSTRACT

Cleft lip and palate is the most common congenital malformation in oro-facial region. In adult cases where defect is large and paucity of tissue is there, prosthetic management of the defect with palatal obturator and velopharyngeal appliance is the treatment of choice. It requires scrupulous clinical skills and detailed knowledge of anatomy to prevent airway obstruction and discomfort during function. Acoustic pharyngometry (AP) is an advanced tool to evaluate the airway in 3D during function without radiation exposure. In this case report palatal obturator with speech aid prosthesis was fabricated to rehabilitate an adult cleft palate patient. AP test was done to ensure adequate airway space with prosthesis.

© This is an open access article distributed under the terms of the Creative Commons Attribution License (<https://creativecommons.org/licenses/by/4.0/>) which permits unrestricted use, distribution, and reproduction in any medium, provided the original author and source are credited.

1. Introduction

Cleft lip and palate is the most common congenital malformation in the craniofacial region. Also, it present severe problems in normal functioning like impaired speech intelligibility, difficult deglutition, seepage of nasal secretions into the oral cavity and vice versa.^{1,2} Many patients have impaired facial growth, dental anomalies, and poor hearing. It not only affects the function but also social life and psychosocial well being. A study from Denmark showed that the incidence of suicides is almost twice in untreated patient for cleft lip and palate aged between 20 and 30 years.³ These cases are managed by specialist multidisciplinary teams in consultation with each other. If surgical management is not possible, because of inadequate tissue to bridge the defect or excessively large defect, prosthetic management is the treatment of choice.⁴ The objective of this article is to enumerate the procedure to rehabilitate an adult patient having wide hard and soft palate

congenital defect.

2. Case Report

2.1. Diagnosis and treatment planning

A 38-year old male patient was referred to the Department of Dental Surgery and Oral Health sciences at Armed Forces Medical College from department of reconstructive surgery for prosthetic rehabilitation of cleft palate. Reconstructive surgery was not undertaken because of wide defect and paucity of residual palatal tissue to repair it. The history revealed that he had undergone surgery for repair of the cleft lip at age of 3 years. Intra oral examination revealed wide cleft of hard and soft palate (Figure 1) causing unintelligible speech due to velopharyngeal insufficiency. It was decided to rehabilitate the patient with speech aid prosthesis and palatal obturator. Patient was explained about the procedure and counseling was done.

Primary impressions of both arches were made in irreversible hydrocolloid with stock trays. Casts were

* Corresponding author.

E-mail address: drvaibhav40@gmail.com (V. Jain).

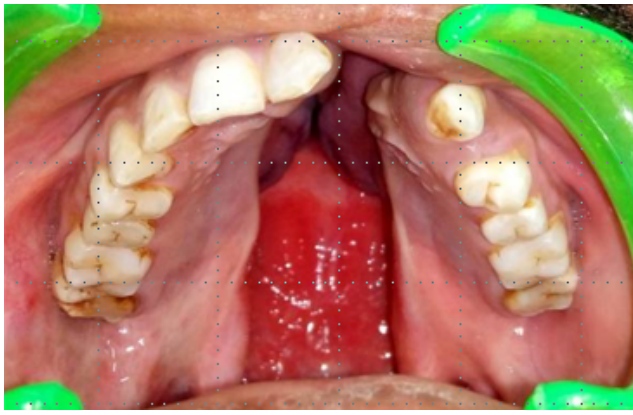


Fig. 1: Pre-op intraoral

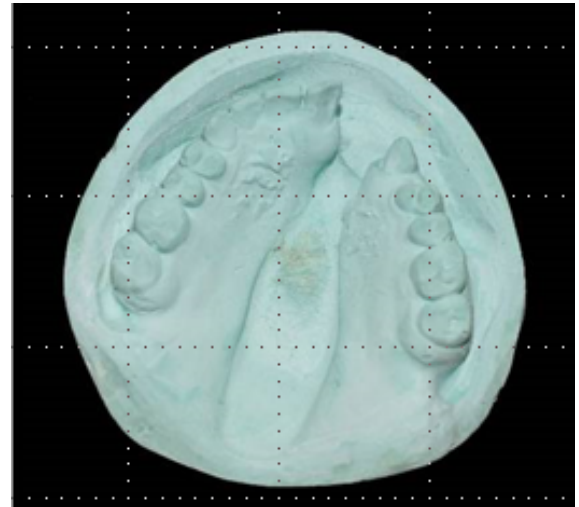

Fig. 2: Diagnostic cast maxillary arch

obtained in type 3 dental stone. A perforated self cure acrylic impression tray was fabricated with spacer of 3mm thickness with an extension to record the soft palate defect.

Diagnostic casts (Figure 2) were obtained and evaluated. Surveying of diagnostic cast was done for designing of cast partial denture. Complete palate major connector with loops extending to the soft palate cleft and circumferential clasps as direct retainers were designed (Figure 3). Mouth preparation was done, impression was made in addition silicone putty and light body. Cast was fabricated in type 4 dental stone and design was transferred to the master cast. Wax pattern was made, casting was carried out and framework was tried in the mouth (Figure 4 a & 4b). Modeling compound was added to the loops to record the soft palate defect. Patient was asked to swallow luke warm water and to carry out the head movements like flexion–extension of neck, rotation, side by side downward movement of the head (Figure 5 a-d) while the material was still soft. The framework with molded compound was taken out of the mouth and examined for any pressure point or deficiency of material. Procedure was repeated till the satisfactory impression was made. For final recording of posterior and lateral wall of pharynx, 2 mm material was scraped and soft liner/tissue conditioner was added and placed in patient's mouth. Patient was asked to repeat all the functional movements as made earlier. After examining the impression, it was again placed in patient's mouth and asked to drink water to check any escape from the nose. Speech was compared and evaluated with and without the prosthesis. A marked improvement was seen and also reduction in hyper nasal twang was there.

The whole assembly was placed in flask to replace the functionally molded low fusing impression compound and missing 22 by heat cure acrylic resin. Flasking, de-waxing, curing and polishing of the prosthesis was done (Figure 6 a). After placing the prosthesis in situ (Figure 6 b), the airway assessment was done by using Acoustic Pharyngometry (AP) (Figure 7 a). AP has an advantage of recording

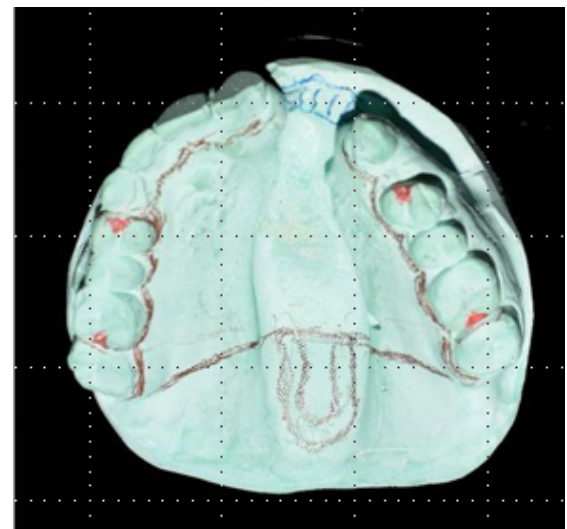


Fig. 3: Cast partial denture designing

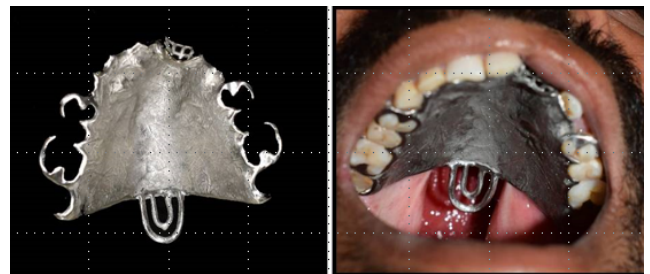


Fig. 4: a: Cast partial denture framework; **b:** Framework try-in

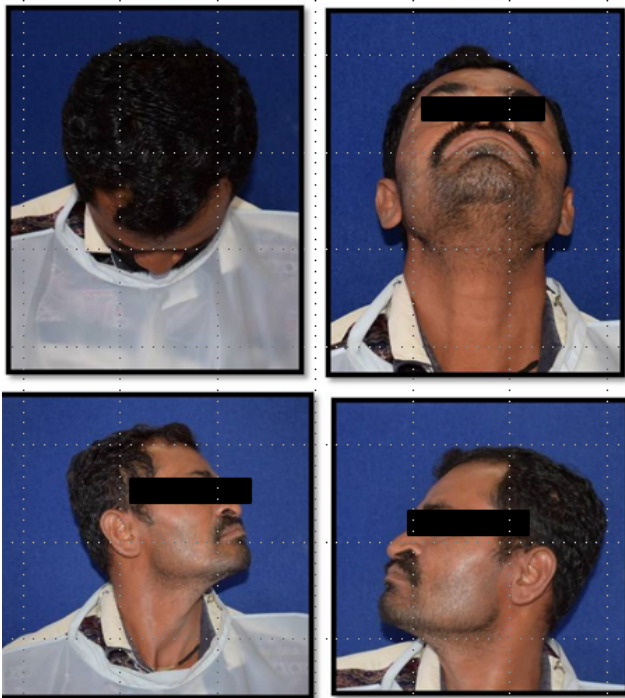


Fig. 5: a-d: Functional molding of impression by head and neck movements

3D dynamic airway without any radiation effect. This test showed adequate availability of functional respiratory space after placing the prosthesis without compromising the airway (Figure 7 b & c). The patient was taken to the ENT department for nasal endoscopy to check airway patency and to visualize the posterior and lateral walls of pharynx during function like head and neck movement, deglutition and to rule out any impingement of the prosthesis over the soft tissue. Post insertion lateral cephalogram was taken to confirm the position of obturator and velopharyngeal appliance.

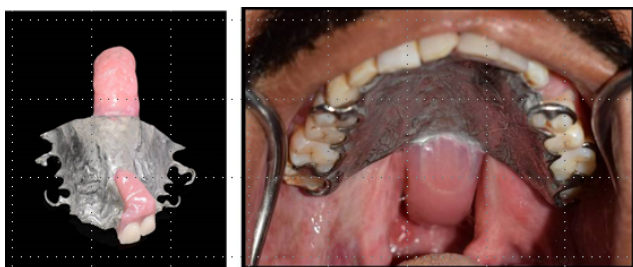


Fig. 6: a: Finished and polished prosthesis; **b:** Prosthesis in-situ

Prosthesis was placed, post insertion instructions were given and patient was referred to the speech therapist. Patient was recalled after 1 month and evaluated for the function with prosthesis. Patient was highly satisfied and motivated with marked improvement in the speech.

3. Discussion

The designing and placing of an adequate obturator is based upon an exact knowledge of the location and action of the muscles of upper throat. Muscle action varies in cleft palate from healthy palate. The closure of nasopharynx is required to use the expired air by lips and tongue for articulation of speech.⁵ In cleft patients, the obturator along with the velopharyngeal appliance helps in separating the oral and nasal cavity and, provides closure by contacting the posterior and lateral wall of nasopharynx during function.⁶ The Acoustic Pharyngometry is an advanced diagnostic tool to determine the airway space during function without radiation exposure.^{7,8} This tool was used in cleft patient for the first time in this case to ensure adequate air way volume and also to compare the air way with and without prosthesis. With prosthesis in situ, the excessive space due to defect was reduced to that of healthy patient. Cleft adult patients have distorted and hyper nasal speech, so, it is very important for the patient to undergo speech therapy to achieve overall physical and functional rehabilitation.⁶

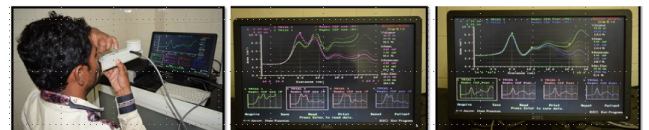


Fig. 7: a: Acoustic pharyngometry test; **b:** Pharyngogram without prosthesis showing excessive airway; **c:** Pharyngogram with prosthesis showing normal airway space

4. Conclusion

Patient education and motivation is very important for the success of any treatment. In this case report, patient was made aware of the treatment options available and educated to improve the quality of life. After complete rehabilitation, patient was highly satisfied, motivated with improved overall psychosocial-well being.

5. Source of Funding

None.

6. Conflict of Interest

The authors declare that there is no conflict of interest.

References

1. Marazita ML, Mooney MP. Current concepts in the embryology and genetics of cleft lip and cleft palate. *Clin Plast Surg.* 2004;31(2):125–40. doi:10.1016/s0094-1298(03)00138-x.
2. Chambers MS, Lemon JC, Martin JW. Obturation of the partial soft palate defect. *J Prosthet Dent.* 2004;91(1):75–9. doi:10.1016/j.prosdent.2003.10.006.

3. Habel A, Sell D, Mars M. Management of cleft lip and palate. *Arch Dis Child*. 1996;74(4):360–6. doi:10.1136/adc.74.4.360.
4. Hickey AJ, Salter M. Prosthodontic and psychological factors in treating patients with congenital and craniofacial defects. *J Prosthet Dent*. 2006;95(5):392–6. doi:10.1016/j.prosdent.2006.03.002.
5. Merkeley HJ. Cleft palate prosthesis. *J Prosthet Dent*. 1959;9(3):506–13. doi:10.1016/0022-3913(59)90083-6.
6. Torn DB. Speech and cleft palate partial denture prosthesis. *J Prosthet Dent*. 1952;2(3):413–7. doi:10.1016/0022-3913(52)90033-4.
7. Kamal I. Acoustic Pharyngometry (objective assessment of the upper airway). The normal standard curve. *Egypt J Otolaryngol*. 2000;17:105–15.
8. Fredberg JJ, Wohl ME, Glass GM, Dorkin HL. Airway area by acoustic reflections measured at the mouth. *J Appl Physiol*. 1980;48(5):749–58. doi:10.1152/jappl.1980.48.5.749.

Author biography

Pramod K Chahar, Graded Specialist

Abir Sarkar, Graded Specialist

Vaibhav Jain, Graded Specialist

Vishvnathe Udayshankar, Graded Specialist

Cite this article: Chahar PK, Sarkar A, Jain V, Udayshankar V. Prosthetic management of an adult cleft patient with velopharyngeal appliance and airway evaluation by acoustic pharyngometry. *IP Int J Maxillofac Imaging* 2021;7(2):87-90.