



Case Report

The diagnostic dilemma of the most common malignancy in orofacial region involving maxillary tubercosity: A case report

M K Sunil¹, Deepak Grover^{2,*}, Arpan Manna¹, Vasundhara Singh¹

¹Dept. of Oral Medicine and Radiology, Teerthanker Mahaveer Dental College and Research Center, Bagadpur, Uttar Pradesh, India

²Dept. of Periodontics & Oral Implantology, National Dental College & Hospital, Dera Bassi, Punjab, India



ARTICLE INFO

Article history:

Received 25-06-2021

Accepted 06-07-2021

Available online 14-07-2021

Keywords:

OSCC

Tobacco

Metastasis

ABSTRACT

Oral squamous cell carcinoma (OSCC) is the most common malignancy affecting the oral cavity. OSCC presents diverse clinical features including small ulcerative lesion to a large growth. The treatment modality of OSCC depends upon the severity, progress and spread of the disease. The purpose of this case report is to emphasize the etiological factors, clinical features as well as the management protocols of OSCC.

© This is an open access article distributed under the terms of the Creative Commons Attribution License (<https://creativecommons.org/licenses/by/4.0/>) which permits unrestricted use, distribution, and reproduction in any medium, provided the original author and source are credited.

1. Introduction

OSCC becomes the most common malignancy of oral cavity by comprising about 90- 95% is all oral malignancies.¹ The incidence of oral cancer is highly variable, but it is said that oral cavity ranges from 6th to 9th most commonly affected location for carcinoma.² It is more commonly seen in elderly age group people, greater than 40 years of age.³ The most common risk factors for OSCC are said to be tobacco and alcohol.⁴ OSCC mainly occurs on tongue making it the most common site, followed by alveolar ridge.⁵ According to the found literature, Oral squamous cell carcinoma affecting the mandible has the lowest survival rate and thus the poorest prognosis.⁶ Clinical presentation of OSCC can show variations ranging from white plaque, inflammatory lesion to more severe ulcerated lesion.⁷ The significant complication of OSCC includes metastasis in regional lymph nodes as well as distant metastasis which ultimately worsen the prognosis.⁸ OSCC can often be misdiagnosed as other lesion of inflammatory origin by the clinician, thus delaying the treatment procedure. So it is important for oral

clinician to diagnose the disease at an earlier stage so that proper treatment measures can be given.

2. Case Report

A 35-year old female patient reported to the department of Oral Medicine and Radiology with the chief complaint of swelling on right side of the face since 2 months. The patient noticed the swelling 2 months back. But she didn't consult any physician at that time. Suddenly since one week started feeling pain in her right upper back tooth region. She also mentioned that she had a mobile tooth in her right upper back tooth region.

So having thought of that tooth to be the root cause of the pain, she went to a local practitioner and got her mobile tooth extracted. After extraction, within one day, a small growth appeared on right lower back tooth region and the swelling of the right side of the face also started increasing. The growth started a pea nut in size and gradually increased in size and attained to the present state. The patient also taken a medication of the same for 4 days after extraction. The patient's medical history and family history was non contributory.

* Corresponding author.

E-mail address: preet342@yahoo.com (D. Grover).

General clinical examination revealed restricted mouth opening. On extra-oral examination, a diffused swelling was present on right side of the face at the middle of alar-tragus line measuring approximately 3*4 cm. On palpation, the swelling was non-tender, non-fluctuant and hard in consistency. On palpation, right submandibular lymph node was tender and palpable (approximately 3 cm in diameter) and were bony hard in consistency and fixed to the underlying skin.

The intraoral examination revealed a proliferative lesion measuring approximately 2*2 cm and was erythematous appearance. It extends Anteroposteriorly, from the distal part of the 17 to the posterior aspect maxillary tuberosity and mediolaterally, it was extending from buccal aspect of 17, 18 to lingual aspects of 17, 18 region. The border of the lesion was everted (Figure 1).

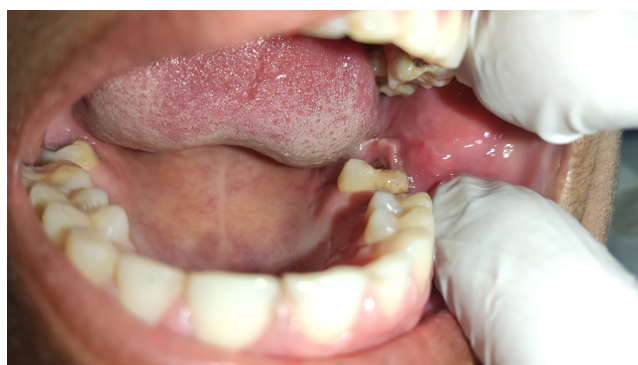

Fig. 1: A proliferative erythematous lesion measuring approximately 2*2 cm

Later the patient is subjected to radiological investigation such as OPG and it revealed as ill-defined radiolucent area with ragged margin measuring 3*2 cm extending from distal aspect of 17 to the anterior aspect of maxillary tuberosity (Figure 2).

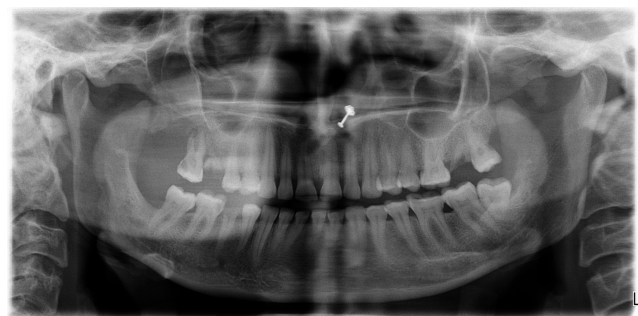


Fig. 2: Ill-defined radiolucent area with ragged margin measuring 3*2 cm extending from distal aspect of 17 to the anterior aspect of maxillary tuberosity

After co-relating all the clinical findings and radiological findings, the provisional diagnosis was made as "Carcinoma

of the maxilla". Later exfoliative cytology was carried out followed by Incisional biopsy to confirm the diagnosis and biopsy confirmed the diagnosis as Oral Squamous cell carcinoma.

The TNM staging of this case is Stage IVA and stage grouping $T_1N_2aM_0$ as the size of the tumor was approximately 2 cm and metastasis was seen in single ipsilateral lymph node approximately 3 cm in size, without any distant metastasis.

3. Discussion

In the Indian subcontinent region OSCC is one of the commonest oral cancer is the most common cause of cancer related death.^{5,9} It is more common in men than female in developing countries, development of oral cancer in Indian subcontinent is much common as a majority of people consume pan-tobacco (a combination of betel leaf, lime, are canut and sun dried tobacco).⁹ In recent studies it is observed that OSCC is 11th most common cancer in male and 15th most common cancer in female.¹⁰ The mean age for diagnosis of oral cancer to be 61 years but 7% diagnosed before 45 years and 2% diagnosed before 35 years of age.⁹

Etiological factors for OSCC is multifactorial. Both the extrinsic and intrinsic factors are there, extrinsic factors are tobacco consumption (both form of tobacco smokeless and with smoke), alcohol, betel quid (paan) and sunlight; and the intrinsic factors are malnutrition, oncogenic viruses, iron deficiency anemia, bacteria, candida, immunosuppression, oncogene and tumour suppressor genes.⁹ Few heritable condition like fanconi anemia,^{11,12} dyskeratosis congenital¹² sometime associated with OSCC has been reported.

In the developed countries tongue is the commonest site for OSCC but in developing countries a large amount of population consume betel quid and tobacco so the commonest site of occurrence is buccal mucosa, as the consumers place the tobacco and/or betel quid in the buccal pouch¹³ but in our present case was observed in maxillary tuberosity area without any tobacco related history.

Prognosis of OSCC is mainly based on distance metastasis and it is better when it is well-differentiated and without metastasis. However, most commonly, cases of OSCC are not diagnosed in early stage which ultimately leads to poor prognosis of the disease. Prognosis also varies on numerous other factors related to the tumor or treatment or to the patient.^{14,15}

Radiographically, the bony defects seen in OSCC can be classified as follows: (a) erosive- well defined margins of the absorbed bone and (b) moth eaten- irregular, ill-defined margins of absorbed bone.¹⁴ This present case shows, ill-defined radiolucency with ragged margin measuring 2*2 cm.

Treatment modalities of OSCC includes primarily a surgical excision followed by radiation therapy and

chemotherapy as an adjunct treatment modalities.¹⁵ But it depends on the severity of the growth.

4. Conclusion

As OSCC has various clinical displays, dentists should be aware of all the traits of this disease. Numerous diagnostic investigations have to be considered immediately after the provisional diagnosis so that you can lessen the morbidity and mortality rate. Accurate and timely diagnosis of the disease is of extreme importance to deliver right treatment modalities to the patients.

5. Source of Funding

None.

6. Conflict of Interest

There is no conflict of interest.

References

- Wallace ML, Neville BW. Squamous Cell Carcinoma of the Gingiva With an Atypical Appearance. *J Periodontol*. 1996;67(11):1245–8. doi:10.1902/jop.1996.67.11.1245.
- Pires FR, Ramos AB, Oliveira JB, Tavares AS, Luz PS, Santos TC. Oral squamous cell carcinoma: clinicopathological features from 346 cases from a single oral pathology service during an 8-year period. *J Appl Oral Sci*. 2013;21(5):460–7.
- Warnakulasuriya S. Global epidemiology of oral and oropharyngeal cancer. *Oral Oncol*. 2009;45(4-5):309–16. doi:10.1016/j.oraloncology.2008.06.002.
- Mehrotra R, Yadav S. Oral squamous cell carcinoma: Etiology, pathogenesis and prognostic value of genomic alterations. *Indian J Cancer*. 2006;43(2):60–6. doi:10.4103/0019-509x.25886.
- Ildstad ST, Bigelow ME, Remensnyder JP. Squamous Cell Carcinoma of the Alveolar Ridge and Palate. *Ann Surg*. 1984;199(4):445–53. doi:10.1097/0000658-198404000-00012.
- Vicente JC, Recio OR, Pendás SL, López-Arranz JS. Oral squamous cell carcinoma of the mandibular region: A survival study. *Head Neck*. 2001;23(7):536–43. doi:10.1002/hed.1075.
- Yoon TY, Bhattacharyya I, Katz J, Towle HJ, Islam M. Squamous cell carcinoma of the gingiva presenting as localized periodontal disease. *Quintessence Int*. 2007;38(2):97–102.
- Abraham S, Mallika B, Reshma A, Kassim RMM. An Atypical Case of Oral Squamous Cell Carcinoma of Mandibular Alveolus. *Case Rep Dent*. 2019;2019:1–6. doi:10.1155/2019/2521685.
- Manna A, Handa R, Nayak A, Lehri S. Non-healing ulcer of tongue: The most commonest yet the most camouflaged lesion of oral cavity. *J Pearldent*. 2020;11(2):27–31. doi:10.5958/2229-4457.2020.00011.2.
- Chan KKW, Glennly AM, Weldon JC, Furness S, Worthington HV, Wakeford H. Interventions for the treatment of oral and oropharyngeal cancers: targeted therapy and immunotherapy. *Cochrane Database Syst Rev*. 2015;12:10341. doi:10.1002/14651858.cd010341.pub2.
- Subapriya R, Thangavelu A, Mathavan B, Ramachandran CR, Nagini S. Assessment of risk factors for oral squamous cell carcinoma in Chidambaram, Southern India: a case-control study. *Eur J Cancer Prev*. 2007;16(3):251–6. doi:10.1097/01.cej.0000228402.53106.9e.
- Bray F, Ren JS, Masuyer E, Ferlay J. Global estimates of cancer prevalence for 27 sites in the adult population in 2008. *Int J Cancer*. 2013;132(5):1133–45. doi:10.1002/ijc.27711.
- Ogden GR. Alcohol and oral cancer. *Alcohol*. 2005;35(3):169–73. doi:10.1016/j.alcohol.2005.04.002.
- Marichalar-Mendia X, Acha-Sagredo A, Rodriguez-Tojo MJ. Alcohol-dehydrogenase (ADH1B) Arg48His polymorphism in Basque country patients with oral and laryngeal cancer: preliminary study. *Anticancer Res*. 2011;31:677–80.
- Chole RH, Patil RN, Basak A, Palandurkar K, Bhowate R. Estimation of serum malondialdehyde in oral cancer and precancer and its association with healthy individuals, gender, alcohol, and tobacco abuse. *J Cancer Res Ther*. 2010;6(4):487–91. doi:10.4103/0973-1482.77106.

Author biography

M K Sunil, Professor and HOD

Deepak Grover, Associate Professor

Arpan Manna, PG Student

Vasundhara Singh, PG Student

Cite this article: Sunil MK, Grover D, Manna A, Singh V. The diagnostic dilemma of the most common malignancy in orofacial region involving maxillary tuberosity: A case report. *IP Int J Maxillofac Imaging* 2021;7(2):91-93.