

Content available at: <https://www.ipinnovative.com/open-access-journals>

IP International Journal of Maxillofacial Imaging

Journal homepage: <https://www.ijmi.in/>

Original Research Article

Assessment of temporomandibular joint morphology and mandibular length in various skeletal malocclusions- A prospective CBCT study

K S Premkumar^{1,*}, N. Kurunji kumaran¹, K. Prabhusankar², S. Sumalatha³, N. Narendran³¹Dept. of Orthodontics and Dentofacial Orthopedics, Annamalai University, Annamalainagar, Tamil Nadu, India²Dept. of Oral & maxillofacial Surgery, Best Dental Science College & Hospital, Madurai, Tamil Nadu, India³Dept. of Orthodontics and Dentofacial Orthopedics, Best Dental Science College & Hospital, Madurai, Tamil Nadu, India

ARTICLE INFO

Article history:

Received 24-09-2021

Accepted 12-10-2021

Available online 25-01-2022

Keywords:

Cone beam computed tomography
Temporomandibular joint disorder

ABSTRACT

Introduction: Temporomandibular joint (TMJ) is a complex structure which may be loaded differently in every individual leading to chances of differential condyle and fossa patterns. The aim of this study was to assess the changes in mandibular length, condyle and glenoid fossa in individuals with various skeletal malocclusions.

Materials and Methods: This study was carried out with CBCT images of 45 patients divided into three groups, comprising of 15 patients in each group within the age group of 18-25years having Class I, Class II and Class III skeletal patterns respectively. Images were analyzed for the mandibular length, condylar and glenoid fossa shape variations.

Results: The measurements showed that Group III had significantly larger values of condylar width, depth, height and volume than other groups ($P < 0.05$). Superior joint space was significantly lesser in Group III ($P < 0.001$), whereas anterior joint space was significantly lesser in Group III and II than Group I ($P < 0.001$ & < 0.05 respectively). The posterior joint space was found to be larger in Group II than Group I and III ($P < 0.001$ & < 0.005 respectively). Mandibular length was significantly increased in Group III ($P < 0.001$) and reduced in Group II ($P < 0.05$).

Conclusion: Significant differences of mandibular length, condylar width, height, length, condylar volume and joint spaces among the three sagittal groups were noted and hence can be concluded that TMJ morphology differed according to the difference in sagittal relationship of maxilla and mandible. Still, larger sample size is needed to study along with the soft tissue considerations in future.

This is an Open Access (OA) journal, and articles are distributed under the terms of the [Creative Commons Attribution-NonCommercial-ShareAlike 4.0 License](https://creativecommons.org/licenses/by-nc-sa/4.0/), which allows others to remix, tweak, and build upon the work non-commercially, as long as appropriate credit is given and the new creations are licensed under the identical terms.

For reprints contact: reprint@ipinnovative.com

1. Introduction

The relationship between Temporomandibular Disorders (TMD) and malocclusion is an extremely critical issue in dentistry. A lawsuit was declared in 1980's that orthodontic treatment was the one of the main causes of TMD, making the evaluation of TMJ as a mandatory procedure prior to any kind of orthodontic as well as Dentofacial orthopedic

corrections.¹

TMJ might be loaded differently in persons with diverse dentofacial morphologies. So, it can be hypothesized that the condyle and the fossa might differ in shape between people with various malocclusions. Most importantly, mandibular condyle is considered to be the prominent site of growth in the mandible which determines the relation between the maxillary and mandibular bases.²

Cone beam computed tomography (CBCT) has become an important milestone of imaging processes in orthodontics

* Corresponding author.

E-mail address: kskprem@gmail.com (K. S. Premkumar).

which helps in complete assessment and diagnosis of various factors three-dimensionally.¹ As the Orthodontic and Dentofacial apparatus changes three-dimensionally during the growth and treatment processes, the evaluation of all these structures done three-dimensionally gives the accurate readings of those changes. Several studies have reported that three-dimensional (CBCT) evaluation of TMJ showed higher accuracy than the two dimensional images of the same.³

CBCT imaging has been found to accurately measure the volume of the mandibular condyle based on the Cavalieri principle.⁴ In a study conducted by Gribel and Lascala, CBCT measurements were found to be as accurate as direct craniometric measurements taken on dry skull specimens.^{5,6} CBCT constructed images have also been determined to be as accurate as conventional images for representations of the lateral cephalogram.⁷

But till date the three-dimensional evaluation of TMJ is still under researched since it differs in every individual according to the sagittal and vertical relationship of the maxilla and mandible. Thus the purpose of this study was to determine the changes in morphology of the condyle, mandible and glenoid fossa among the various malocclusions in adult patients.

2. Material and Methods

This cross-sectional study was carried out with CBCT images of 45 patients (22males and 23 females) within the age group of 18-25years reported to Best Dental College, Madurai. The study group was divided into three groups (Group I,2&3) with Class I, Class II and Class III skeletal patterns respectively in each group comprising of 15 patients with the mean age of 21.5years. The patient's inclusion criteria for the study group was described as with all the permanent teeth erupted with normal occlusion and normal function of TMJ without any transverse discrepancies in both the arches. Normal TMJ function was described as lack of history of pain, the joint sound, the clenching, and without limitation in the range of motion and posterior bite collapse.

CBCT scans were obtained for the all the participants of the study using KODAK CS-9300 CBCT machine (Carestream Health Eastman Kodak Company) delivering high-resolution images of 0.09 - 0.3 mm slice thickness with a large field of view (FOV) of 17 X 13.5cm (Figures 1 and 2). This study was designed to analyze the mandibular length, condylar and glenoid fossa shape variation in all Class I, II & III skeletal malocclusion patients. 11 anatomic landmarks have been selected for measuring the following parameters: Condylar volume, condylar width, length, and height, condylar joint spaces at the anterior, superior, and posterior condylar poles and mandibular length (Figures 3 and 4).

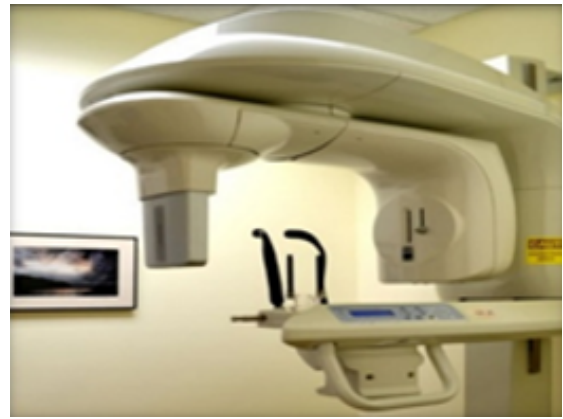

Fig. 1: CBCT imaging device

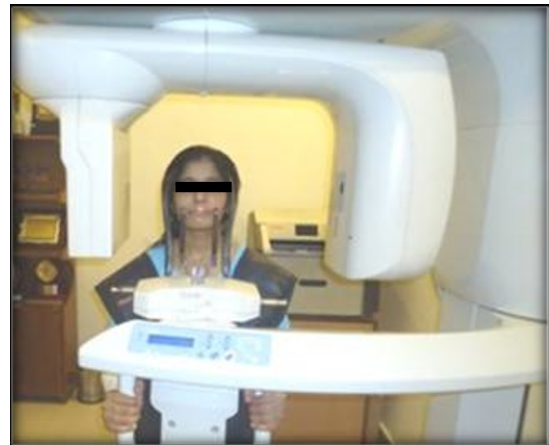

Fig. 2: Patient undergoing CBCT imaging (CBCT KODAK-CS 9300 machine)

The CBCT scans were evaluated by importing the Dicom images in Xelis dental software (Dental3D version 1.0.5.0 BN4). Three linear measurements that directly characterizing the size of the condyles (width, length, and height) were measured from the CBCT projection after the coordination of condyle in three planes (Figure 3).

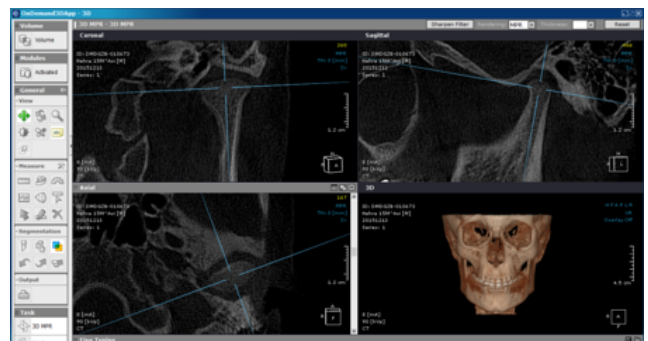


Fig. 3: Co-ordination of scans in all three planes (coronal, axial and sagittal)

Condylar length, width and height were measured using metric analysis given by Kinzinger et al.⁸ and Hoppenreijns et al.⁹ According to their study the condylar sizes were measured as follows:

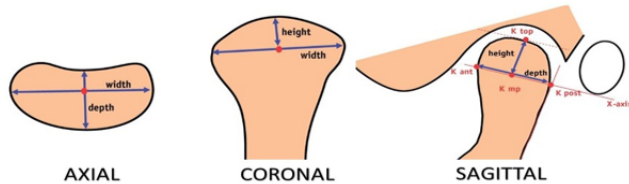


Fig. 4: Schematic diagram of measurement of condylar width, depth and height

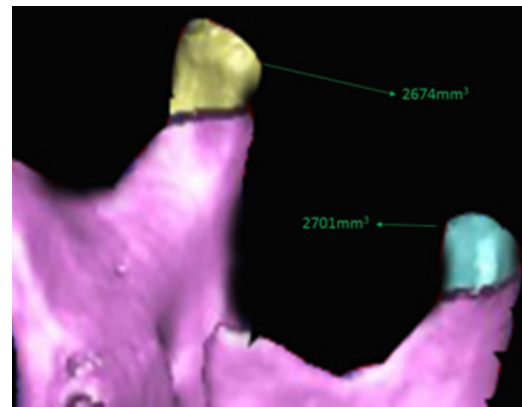


Fig. 8: Measuring the condylar volume by 3D reconstruction

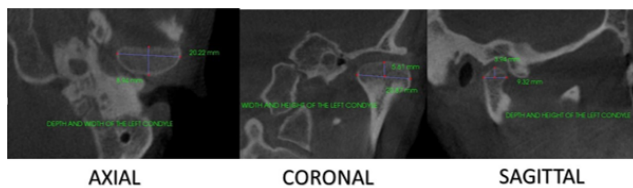


Fig. 5: Measuring the condylar length, width and height in sagittal and coronal planes

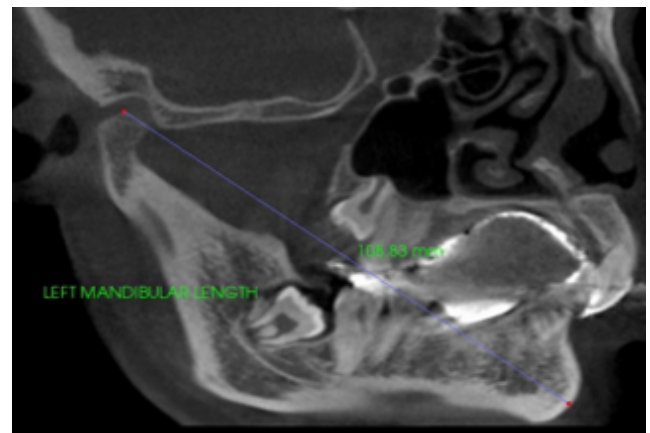


Fig. 9: Measuring the mandibular length on sagittal section of the CBCT images

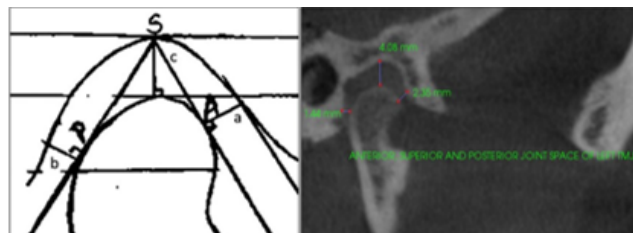


Fig. 6: Measuring the anterior, posterior and superior joint spaces in the glenoid fossa

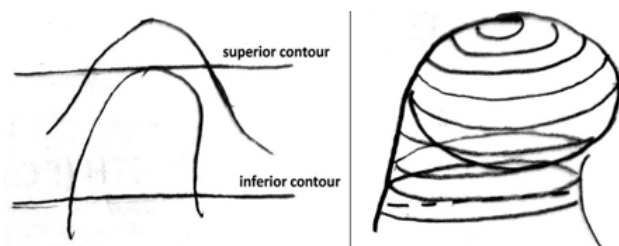


Fig. 7: Defining the condylar contours for the measurement of condylar volume

1. *Condylar width*- linear distance between the most prominent points on anterior and posterior borders of the condyle in axial and coronal sections.(Figures 4 and 5).

2. *Condylar depth*-linear distance between the most prominent points on medial and lateral borders of the condyle in sagittal section and liner distance between the uppermost and lowermost borders at midpoint of the condyle in axial section (Figures 4 and 5).
3. *Condylar height*- perpendicular distance between superior most point in condyle to the line connecting most prominent points on the medial and lateral surfaces of condyle in sagittal section (Figures 4 and 5). In the frontal section it was measured as the perpendicular distance between the superior most point on the condyle and the transverse line passing through anteriormost and posterior most prominent points (Figures 4 and 5).
4. *Joint spaces*- The joint spaces in TMJ were measured as per Ideka and Kawamura's study¹⁰ in which a horizontal line on uppermost area of glenoid fossa was drawn and the intersection of this line with glenoid fossa was selected as superior reference point (S). Two lines were drawn on anterior and posterior aspects of the condyle connecting the most prominent

points A & P to the superior reference point S. The anterior and posterior joint spaces were measured as perpendicular distance from points A and P to glenoid fossa respectively. Superior joint space (Sjs) was measured as the perpendicular distance between the S point and superior most point of the condylar head. To enclose, the mean of the mentioned measurements on two central cuts was regarded as the final Ajs, Sjs and Pjs (Figure 6).

5. *Condylar volume*- 3D reconstruction of the condyle was done by progressively removing the other structures surrounding it using various sculpting tools for the upper, lower, and side condylar contours. The superior contour of the condyle was defined where the first radiopaque point was viewed in the image depicting the synovia; the lateral contours for each section were easily identified through clear visualization of the cortical bone. The inferior contour of the condyle was traced where its section passed from an “elipsoidal” shape (owing to the presence of anterior crest of the condylar head) to a more “circular” shape (suggesting that the view was at the level of the condylar neck). After the condylar segmentation, 3-D multiplanar reconstructions were produced, and volumetric (mm^3) were made for each condyle³ (Figures 7 and 8).
6. *Mandibular length*- Mandibular length was measured as the linear measurement from the point condylion (superior most point on the condyle) to Gnathion point as given by McNamara et al.¹¹ (Figure 9)

The Condylar length, width, height, volume, condylar joint spaces and mandibular length were measured on both the right and left condyles in each patient. The CBCT scans were evaluated by importing the Dicom images in OnDemand™ dental software. The scans were coordinated in all the three planes along the long axis of the condyle i.e. coronal, sagittal and axial plane to minimize any error. Before taking the measurements, brightness and contrast were adjusted accordingly. Image segmentation of the anatomic structures based on 2-D Digital Imaging and Communications in Medicine (DICOM) formatted data provided different planes of view as well as three-dimensionally reconstructed volumes using OnDemand™ dental software.

2.1. Statistical analysis

All measurements were conducted by single examiner. For assessing the intra-examiner reliability, the examiner re-analyzed 20 randomly selected subjects within a 2-week interval. Intraexaminer reliability was assessed using kappa statistics (0.995), which confirmed acceptable reproducibility of the measurements. The data collected was analyzed using IBM SPSS Statistics software (version 23.0;

IBM Corp., Armonk, NY, USA). The normal distribution of the data was confirmed by Kolmogorov-Smirnov test. One-way ANOVA and Turkey HSD test were used to compare Class I, II, and III groups according to the sagittal skeletal patterns.

3. Results

Since there were no significant differences between the right and left values of the condylar measurements, joint spaces and mandibular length, the mean value of the right and left were calculated for representing the same. After comparing the condylar measurements and joint spaces in between all the three groups, significant differences were found.

According to the results obtained in this study, Group III showed significantly larger values of condylar width, depth, height and volume than the Group I and Group II ($P < 0.05$; Table 2). It was also observed that superior joint space was significantly lesser in Group III than the other two groups ($P < 0.001$), whereas anterior joint space was significantly lesser in Group III and Group II than Group I ($P < 0.001$ & < 0.05 respectively). The posterior joint space was found to be larger in Group II significantly than the Group I and Group III ($P < 0.001$ & < 0.005 respectively).

As per the measurement of mandibular length in all the three groups, it was significantly increased in Group III ($P < 0.001$) and reduced in Group II ($P < 0.05$)

4. Discussion

As per the results obtained in this study, Class III skeletal pattern group showed higher values of condylar width and height than the Class I and Class II groups. Whereas condylar depth was found to be more in Class I than the other groups. This was similar to the results obtained by Krisjane et al.¹² that condylar height was significantly increased in Class III individuals. The condylar height is generally increased in all the Class III patients as they have excessive vertical growth of the mandibular ramus of the mandible. Katsavrias and Halazonetis¹³ had done the study on condylar morphology in various skeletal malocclusion patients and they also found the same results as per our study that condylar height was found to be increased in Class III patients than the other groups.

Saccucci et al.¹⁴ reported that Class III subjects showed a higher condylar volume and surface than Class I and Class II subjects, which was not significant. Katayama et al.¹⁵ also reported that there was no statistical difference in the mandibular condylar volume among anteroposterior skeletal patterns. But in this study on comparison of all the groups, Class III group showed significantly increased condylar volume than the other groups which is contrary to previous studies.

Condylar position in the glenoid fossa was assessed by measuring the joint spaces in anterior, posterior and superior

Table 1: Showing the various condylar measurements, joint space and mandibular length measurements in all the three skeletal malocclusion

| Measurements | Group I | Group II | Group III |
|-----------------------|-----------------------------|--------------------------------|-------------------------------|
| Condylar width | 19.30+1.22mm | 19.10+1.61mm | 20.04+1.10mm |
| Condylar depth | 7.27+0.84mm | 6.76+1.04 mm | 7.08+1.12mm |
| Condylar height | 5.74+0.50 mm | 5.52+0.33 mm | 6.35+0.65mm |
| Anterior joint space | 2.05+0.38 mm | 1.62+0.27 mm | 1.77+0.24 mm |
| Posterior joint space | 1.93+0.37mm | 2.61+0.37 mm | 2.22+0.59mm |
| Superior joint space | 2.96+0.64mm | 2.70+0.52mm | 1.87+0.71mm |
| Condylar volume | 3002.02+632 mm ³ | 2676.09+587.90 mm ³ | 3387.25+499.5 mm ³ |
| Mandibular length | 121.21+6.07mm | 116.98+3.77mm | 132.39+4.3mm |

Table 2: Showing the intergroup comparison between Group I, Group II and Group III

| Dependent Variable | Groups (I) | Groups (J) | Mean Difference (I-J) | Sig. | 95% Confidence Interval | |
|----------------------------|------------|------------|-----------------------|------|-------------------------|-------------|
| | | | | | Lower Bound | Upper Bound |
| Condylar width | Group I | Group II | .19687 | .908 | -.9407 | 1.3344 |
| | | Group III | -.74844 | .258 | -1.8860 | .3891 |
| | | Group II | -.94531 | .120 | -2.0829 | .1922 |
| Condylar depth | Group I | Group II | .51375 | .331 | -.3528 | 1.3803 |
| | | Group III | .18844 | .859 | -.6781 | 1.0550 |
| | | Group II | -.32531 | .637 | -1.1918 | .5412 |
| Condylar height | Group I | Group II | .22719 | .427 | -.2114 | .6658 |
| | | Group III | -.60531* | .005 | -1.0439 | -.1667 |
| | | Group II | -.83250* | .000 | -1.2711 | -.3939 |
| Anterior joint space(AJS) | Group I | Group II | .42844* | .001 | .1672 | .6897 |
| | | Group III | .27969* | .033 | .0185 | .5409 |
| | | Group II | -.14875 | .360 | .1125 | .4100 |
| Posterior joint space(PJS) | Group I | Group II | -.68063* | .000 | -1.0720 | -.2893 |
| | | Group III | -.28875 | .185 | -.6801 | .1026 |
| | | Group II | .39187* | .050 | .0005 | .7832 |
| Superior joint space(SJS) | Group I | Group II | .25844 | .484 | -.2822 | .7990 |
| | | Group III | 1.08844* | .000 | .5478 | 1.6290 |
| | | Group II | .83000* | .002 | .2894 | 1.3706 |
| Condylar volume | Group I | Group II | 326.15625 | .255 | 819.5226 | 167.2101 |
| | | Group III | -.385.00187 | .153 | -.878.3683 | 108.3645 |
| | | Group II | -.711.15812* | .003 | -1204.5245 | -217.7917 |
| Mandibular length | Group I | Group II | 4.23937* | .043 | .1099 | 8.3688 |
| | | Group III | -.11.17688* | .000 | -15.3063 | -7.0474 |
| | | Group II | -.15.41625* | .000 | -19.5457 | -11.2868 |

position of the condyle. On measuring these values, it was found that anterior joint space was significantly reduced in Class II and Class III patients than the Class I patients. In comparison with Class II and Class III patients, it showed that Class II patients showed reduced anterior joint space than the Class III patients. This was in accordance with study done by Pullinger et al.¹⁶ and Kikuchi et al.¹⁷ which reported more anteriorly situated condyle in Class II patients than the Class I and Class III patients. Similar type of result was obtained in a study done by Seren et al.,¹⁸ stating that a smaller anterior joint space was observed in Class III subjects and there was no difference in posterior joint space between all the groups. But in our study the posterior joint space was found to be significantly increased in Class II individuals than the Class I and Class III groups.

The increase in posterior joint space in our study may be because of the anterior positioning of the mandible in Class II individuals than the other groups which was similar to the results in the study done by Pullinger et al.¹⁶ Cohlma et al.¹⁹ also found a more anterior condyle position in Class III patients than Class I, and no difference in condylar position between Class I and Class II. But these results were contrary to the results obtained in studies done by Gianelly et al.²⁰ and Burke et al.²¹ in which no differences were found in condylar positions of Class II persons and normal individuals. The superior joint space was found to be reduced significantly in Class III individuals than the Class I and Class II groups in this study. This was similar to the results obtained in the study done by Katsavrias and Halazonetis¹³ which showed decreased superior joint space

in accordance with the increased condylar height.

As per measurements done in this study, the mandibular length was found to be significantly more in Class III individuals and less in Class II individuals. This was in accordance with the study done by Jacob HB and Buschang BH²² showing that skeletal Class II individuals had significantly lesser mandibular length than the Class I individuals.

5. Limitations

The articular disc and other soft tissue structures were not evaluated in this study as only CBCT images were used in this study. So patients with internal derangement who were asymptomatic could have been included in this study. This could have been avoided by diagnosing all the soft tissue structures associated to TMJ using magnetic resonance imaging before including the individuals into the study. Sample size is not sufficient in this study to withdraw a conclusive evidence about the sagittal variations and TMJ changes. If this study is done with MRI scanning and more number of CBCT samples, the study results will be much validated than the present study.

6. Conclusions

From the study results it had been concluded that,

1. Sagittal variation between the maxilla and mandible led to the morphological changes in TMJ leading to the significant variations in Condylar volume, Condylar length, width and height, joint spaces and the mandibular length.
2. It was found that condylar width, height and volume is increased in Class III individuals.
3. In the joint spaces, Anterior joint space is reduced and Posterior joint space is increased in Class II individuals. Whereas Superior joint space is found to be reduced in Class III individuals.
4. The mandibular length is increased in Class III individuals and reduced in Class II individuals.

7. Ethical Approval Code

(2021-STF-BrV-KSP-02)

8. Source of Funding

None.

9. Conflict of Interest

None.

References

1. Caldas W, Conti A, Janson G, Conti PCR. Occlusal changes secondary to temporomandibular joint conditions: a critical review and implications for clinical practice. *J Appl Oral Sci.* 2016;24(4):411–20. doi:10.1590/1678-775720150295.
2. Hasebe A, Yamaguchi T, Nakawaki T, Hikita Y, Katayama K, Maki K. Comparison of condylar size among different anteroposterior and vertical skeletal patterns using cone-beam computed tomography. *Angle Orthod.* 2019;89(2):306–17. doi:10.2319/032518-229.1.
3. Tecco S, Saccucci M, Nucera R, Pagnoni M. Condylar volume and surface in Caucasian young adult subjects. *BMC Med Imaging.* 2010;10:28. doi:10.1186/1471-2342-10-28.
4. Bayram M, Kayipmaz S, Sezgin OS, Kuçuk M. Volumetric analysis of the mandibular condyle using cone beam computed tomography. *Eur J Radiol.* 2012;81(8):1812–8. doi:10.1016/j.ejrad.2011.04.070.
5. Gribel BF, Gribel MN, Frazao DC, Mcnamara JA, Manzi FR. Accuracy and reliability of craniometric measurements on lateral cephalometry and 3D measurements on CBCT scans. *Angle Orthod.* 2011;81(1):26–35. doi:10.2319/032210-166.1.
6. Lascala CA, Panella J, Marques MM. Analysis of the accuracy of linear measurements obtained by cone beam computed tomography. *Dentomaxillofac Radiol.* 2004;33(5):291–5. doi:10.1259/dmfr/25500850.
7. Park CS, Park JK, Han KH. Comparison of conventional lateral cephalograms with corresponding CBCT radiographs. *Imaging Sci Dent.* 2012;42(4):201–6. doi:10.5624/isd.2012.42.4.201.
8. Kinzinger G, Kober C, Diedrich P. Topography and morphology of the mandibular condyle during Fixed Functional orthopedic treatment - A magnetic resonance imaging study. *J Orofac Orthop.* 2007;68(2):124–71. doi:10.1007/s00056-007-0650-0.
9. Hoppenreijts TJM, Freihofer HPM, Stoelinga PJM. Condylar remodeling and resorption after Le Fort I and bimaxillary osteotomies in patients with anterior open bite. A clinical and radiological study. *Int J Oral Maxillofac Surg.* 1998;27(2):81–91. doi:10.1016/s0901-5027(98)80301-9.
10. Ikeda K, Kawamura A. Assessment of optimal condylar position with limited cone-beam computed tomography. *Am J Orthod Dentofacial Orthop.* 2009;135(4):495–501. doi:10.1016/j.ajodo.2007.05.021.
11. Mcnamara JA. Components of Class II malocclusion in children 8-10 years of age. *Angle Orthod.* 1981;51(3):177–202. doi:10.1043/0003-3219(1981)051<0177:COCIMI>2.0.CO;2.
12. Krisjane Z, Urtane I, Krumina G, Bieza A, Zepa K, Rogovska I. Condylar and mandibular morphological criteria in the 2D and 3D MSCT imaging for patients with Class II division 1 subdivision malocclusion. *Stomatologija.* 2007;9(3):67–71.
13. Katsavrias EG, Halazonetis DJ. Condyle and fossa shape in Class II and Class III skeletal patterns: A morphometric tomographic study. *Am J Orthod Dentofacial Orthop.* 2005;128(3):337–83. doi:10.1016/j.ajodo.2004.05.024.
14. Saccucci M, Attilio D, Rodolfo M, Festa D, Polimeni F, Tecco A, et al. Condylar volume and condylar area in Class I, Class II and Class III young adult subjects. *Head Face Med.* 2012;8:34. doi:10.1186/1746-160X-8-34.
15. Katayama K, Yamaguchi T, Sugiura M, Haga S, Maki K. Evaluation of mandibular volume using cone-beam computed tomography and correlation with cephalometric values. *Angle Orthod.* 2014;84(2):337–79. doi:10.2319/012913-87.1.
16. Pullinger AG, Hollender L, Solberg WK, Petersson A. A tomographic study of mandibular condyle position in an asymptomatic population. *J Prosth Dent.* 1985;53(5):706–19.
17. Kikuchi K, Takeuchi S, Tanaka E, Tanne ST. Association between condylar position, joint morphology and craniofacial morphology in orthodontic patients without temporomandibular joint disorders. *J Oral Rehabil.* 2003;30(11):1070–5. doi:10.1046/j.1365-2842.2003.01194.x.
18. Seren E, Akan H, Toller MO, Akyar S. An evaluation of the condylar position of the temporomandibular joint by computerized tomography in Class III malocclusions: A preliminary study. *Am J Orthod Dentofacial Orthop.* 1994;105(5):483–91. doi:10.1016/S0889-5406(94)70009-5.
19. Cohlmiä JT, Ghosh J, Sinha PK, Nanda RS, Currier GF. Tomographic assessment of temporomandibular joints in patients with

- malocclusion. *Angle Orthod.* 1996;66(1):27–35. doi:10.1043/0003-3219(1996)066<0027:TAOTJI>2.3.CO;2.
20. Gianelly AA, Brosnan P, Martignoni M, Bernstein L. Mandibular growth, condyle position and Fränkel appliance therapy. *Angle Orthod.* 1983;53(2):131–73. doi:10.1043/0003-3219(1983)053<0131:MGCPAF>2.0.CO;2.
21. Burke G, Major P, Glover K, Prasad N. Correlations between condylar characteristics and facial morphology in Class II preadolescent patients. *Am J Orthod Dentofacial Orthop.* 1998;114(3):328–64. doi:10.1016/s0889-5406(98)70216-1.
22. Jacob HB, Buschang BH. Mandibular growth comparisons of Class I and Class II division 1 skeletofacial patterns. *Angle Orthod.* 2014;84(5):755–61. doi:10.2319/100113-719.1.

Author biography

K S Premkumar, Research Scholar

N. Kurunji kumaran, Research Guide

K. Prabhusankar, Research Co-Guide

S. Sumalatha, Reader

N. Narendran, Lecturer

Cite this article: Premkumar KS, Kurunji kumaran N, Prabhusankar K, Sumalatha S, Narendran N. Assessment of temporomandibular joint morphology and mandibular length in various skeletal malocclusions- A prospective CBCT study. *IP Int J Maxillofac Imaging* 2021;7(4):149-155.