

Content available at: <https://www.ipinnovative.com/open-access-journals>

IP International Journal of Maxillofacial Imaging

Journal homepage: <https://www.ijmi.in/>

Review Article

Artifacts — A hitch in CBCT

Sujeev N¹, Anusha R.L.^{2,*}, Renita Castelino³, Praveenkumar Ramdurg⁴

¹Dept. of Dentistry, PK DAS Institute of Medical Sciences Hospital and Medical College, Palakkad, Kerala, India

²Dept. of Oral Medicine & Radiology, Dr.shaji's MRI and Medical Research Centre (P) Ltd, Calicut, Kerala, India

³Dept. of Oral Medicine and Radiology, A.B Shetty Memorial Institute of Dental Sciences Nitte (Deemed to be) University, Mangaluru, Karnataka, India

⁴Dept. of Oral Medicine and Radiology, PMNM Dental College and Hospital, Bagalkote, Karnataka, India



ARTICLE INFO

Article history:

Received 23-12-2021

Accepted 03-01-2022

Available online 25-01-2022

Keywords:

Artifacts

Cone beam computed tomography

Noise

ABSTRACT

Cone beam computed tomography (CBCT) has gained an unmissable importance nowadays because of its accuracy in detecting the pathologies of head and neck region. It has become part and parcel as a salient diagnostic aid in dentistry. But everything in this world has two faces of the coin. Similarly, CBCT has a small hitch in it that is “Artifacts”. Artifacts are discrepancies between the reconstructed visual image and the actual content of the subject which degrade the quality of CBCT images, making them diagnostically unusable. This article directs on the different kinds of artifacts and the reasons behind it.

This is an Open Access (OA) journal, and articles are distributed under the terms of the [Creative Commons Attribution-NonCommercial-ShareAlike 4.0 License](https://creativecommons.org/licenses/by-nc-sa/4.0/), which allows others to remix, tweak, and build upon the work non-commercially, as long as appropriate credit is given and the new creations are licensed under the identical terms.

For reprints contact: reprint@ipinnovative.com

1. Introduction

Since the introduction of the CBCT machine in 1998, it has transformed in the field of dentistry. It is used as a prime diagnostic aid and imaging tool in maxillofacial region. Despite of several advantages, it too has a disadvantage. In broader sense, artifact means to an object observed in an investigation that is not naturally present but it will occur due to preparative procedure.¹ Specifically, in CBCT and CT, artifacts refer to any systemic discrepancy between numerical data in reconstructed image and true attenuation coefficient of the object.² These artifacts need to be differentiated from the pathologies for proper diagnosis and treatment planning. So, a thorough knowledge about the various artifacts prompts all general physician in accurate diagnosis and therein management of the same.

1.1. Classification of the artifacts

Classification of artifacts is not standardized. But it can be classified for easier understanding and its given below in the Figure 1.³

1.2. Different types of artifacts

1.2.1. X-ray related artifacts

A wide range of energies is seen in the individual photons of the X-ray beam. When an object is penetrated by this beam the lower energy photons get absorbed faster than high energy photons.⁴ The resultant beam will be harder. Due to the high absorbing nature of the metals, it behaves as a filter.⁵

The beam hardening out-turns in two different types of artifacts:⁶

1. Cupping artifacts and
2. Appearance of dark bands or streaks.

* Corresponding author.

E-mail address: dr.anushar1@gmail.com (Anusha R.L).

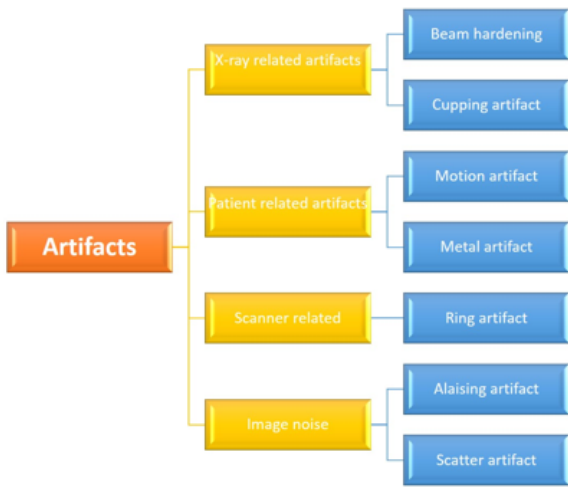


Fig. 1: Classification of the artifacts.³

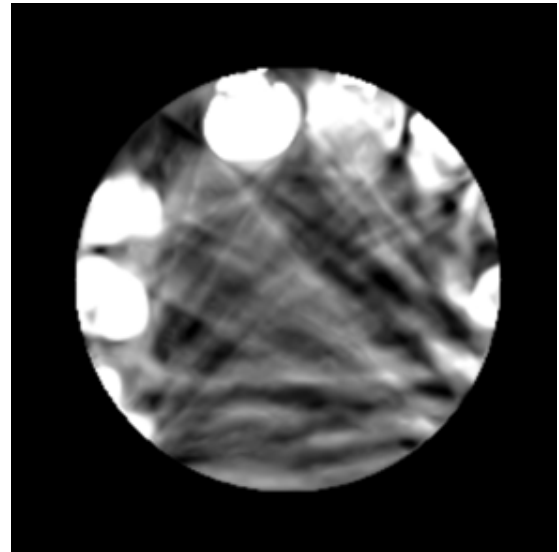


Fig. 4: Metal artifact.

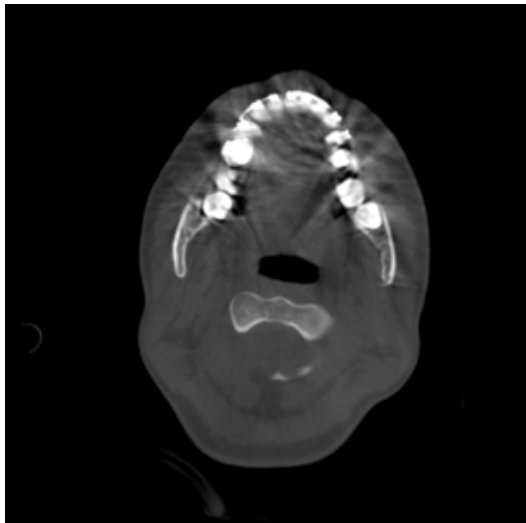


Fig. 2: Streak artifact

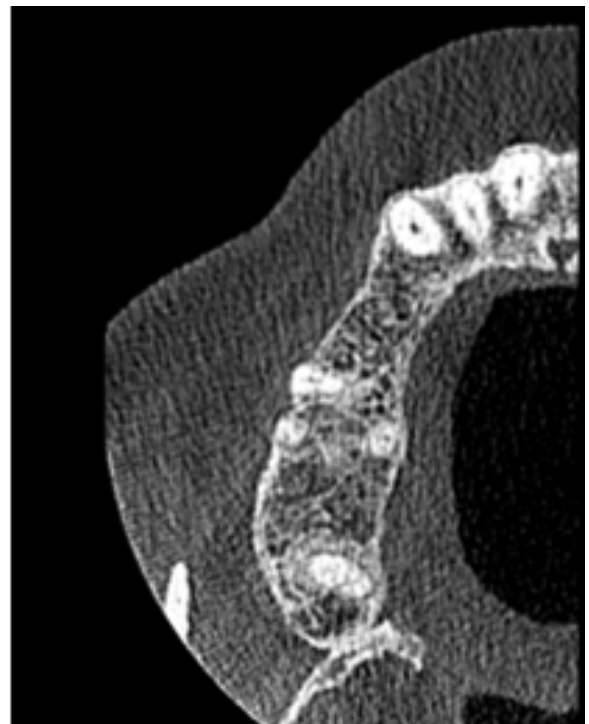


Fig. 5: Image noise

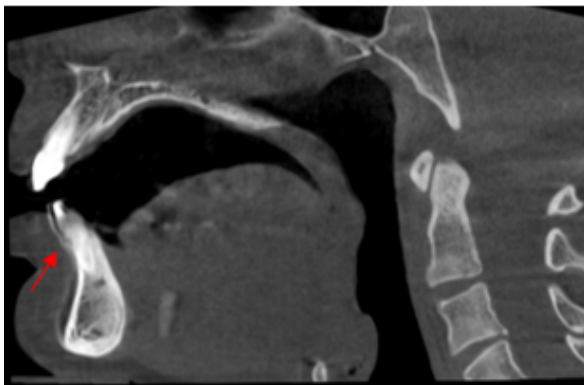


Fig. 3: Movement artifacts presenting as double contours.

1.2.1.1. Cupping artifacts.

1. Imaging of any cylindrical objects give rise to this artifact. The photons penetrating through the centre of the cylinder come across more material than those penetrating through the edges which causes lowering in the rate of attenuation at the middle part compared to periphery due to increased beam hardening in the same. The resultant modified attenuation form reveals a characteristic cup shaped artifact.⁷
2. *Rectification:* Use of smaller field of view (FOV) by collimation, changing of position of the patient or by imaging the dental arch individually; by avoiding the beam hardening prone regions during exposure like metallic restorations or crowns and implants; will be an empirical and realistic solution to prevent these artifacts.⁷

1.2.1.2. Dark bands or streaks .

1. In the span of beam hardening procedure, a non-linear error is established into the recorded data and when the 3D reconstruction is formed, this mistake will lead to the dark streaks.⁶(Figure 2) This artifact is more evident on the CBCT images when compared to the conventional CT due to the lower mean kilovolt (peak) energy and because of heterochromatic X-ray beam.⁶⁻⁸
2. *Rectification:* These can be reduced using iterative reconstruction.

1.2.2. Patient related artifacts

Patient related artifacts are of two types: one motion artifact and another one is due to metal wearing by the patient.

1.2.2.1. Motion artifacts.

1. Movement of the patient can lead to misregistration artifacts within the image. During the scanning procedure, if an object intent to move, no data will be accounted in the reconstruction process due to the motion.^{9,10}
2. As a consequence of this, the lines along which the back projection takes place do not correspond to the lines along which the attenuation had been recorded, due to the motion of the object during the imaging process.⁹⁻¹²
3. Motion artifacts unveil as double contours. (Figure 3)
4. *Rectification:* By reducing the size of the voxel or by increasing the spatial resolution, will result in the smaller movement of the patient's structures out of the "correct" voxels.⁹⁻¹²

1.2.2.2. Avoidance of metal artifacts by the operator.

1. Before the scanning process, patients are instructed to remove all the removable metallic objects like jewellery or hair pins.

2. For fixed items like dental fillings (Figure 4), prosthetic devices, and surgical clips, by angulating the gantry, it is possible few times to exclude these metallic objects from the adjacent scanning structures.
3. *Rectification:* When it is not possible to remove and avoid the metallic objects in the area of interest, by increasing the technique, especially kilovoltage, may help penetrate some objects, and by using thin sections will reduce the contribution due to partial volume artifact.¹²

1.2.3. Scanner related artifacts

1.2.3.1. Ring artifacts.

1. Ring artifacts are seen as concentric rings which are located at the centre of the axis of rotation due to the imperfections seen in scanner detection or poor calibration.
2. They become very evident when the homogenous objects are exposed. Owing to the circular trajectory and the discrete sampling process. These defects appear as rings in the planes coplanar with the movement plane of the source (axial planes in CBCT).⁹⁻¹⁵
- *Rectification:* Avoidance and software corrections are needed. Recalibration or repair of the software or machine is required if circular artifacts are seen. By selecting the smaller FOV, can reduce this artifact.¹⁶ Advanced software techniques which rectifies detector variations are used in the modern scanners such as solid-state detectors prevent these ring artifacts.¹²

1.2.4. Image noise

1. *Definition:* It is an unwanted, randomly and/or non-randomly distributed disturbance of a signal that tends to obscure the signal's information content from the observer.
2. The CBCT images are affected by reduced low contrast resolution produced by the noise¹⁷ (Figure 5), making it hard to differentiate low density tissues by bringing down the ability to segment effectively.

1.2.5. Exponential edge gradient effect

1. The effect is seen at the sharp edges as high contrast to the adjacent structures. It is caused by averaging the measured intensity over a finite beam width (and finite focal spot width), while the mathematics used for the reconstruction assumes zero width. The width is calculated by the focal spot and detector pixel size and is integrated with the imaging geometry of the machine.
2. The EEGE is known to cause streaks tangent to long straight edges in the projection direction. For example, metallic crown borders used in oral cavity as FPD.⁹⁻¹³

1.2.6. Extinction artifacts or missing value artifacts

- The presence of high absorbing materials such as gold restorations in the area of interest of scanning results in this artifact where the recorded signal in the pixels behind these objects will be zero or close to zero.¹⁸

1.2.6.1. Aliasing artifacts.

- These artifacts present as moire patterns or line patterns seen in the reconstructed volume and they usually diverge towards the periphery. These can be a reason of a crude interpolation between the back projected lines and the voxel traversed by them.¹⁹

1.2.6.2. Stair step artifacts.

1. By the use of wide collimations and non-overlapping reconstruction intervals, the above artifacts come into sight around the edges of structures especially in the multiplanar and 3D reconstructed images. They can be reduced or avoided by the use of helical scanning. In helical scanning, reconstruction of the overlapping sections can be achieved if overlapping axial scans are available without more exposure to the patient.
2. These artifacts can be prevented by the use of multi-section scanners which provides thin section data.^{12–20}

1.2.6.3. Zebra artifacts:.

1. In the multiplanar and 3D reformatted images of helical data shows unclear or faint stripes due to the helical interpolation process gives rise to a degree of noise inhomogeneity along the z axis.
2. This “zebra” effect becomes more pronounced away from the axis of rotation because the noise inhomogeneity is worse off axis.¹²

2. Conclusion

Artifacts are the hitch in the CBCT. It is every physician’s duty to know and learn about these artifacts so that it doesn’t hinder in the diagnosis and treatment management. These artifacts can be avoided by use of modern approaches to avoid reconstruction errors. Advances in the reconstruction methods in the near future might reduce the artifacts.

3. Source of funding

None.

4. Conflict of Interest

None.

References


1. Syam TNS, Maheswari U. Artifacts in Cone Beam Computed Tomography - A Retrospective study. *J Pharm Sci Res.* 2019;11(5):1914–7.


2. Perrella A, Lopes P, Rocha RG, Pereira MF, Cavalcanti MG. Influence of dental metallic artifact from multislice CT in the assessment of simulated mandibular lesions. *J Appl Oral Sci.* 2010;18(2):149–54. doi:10.1590/S1678-77572010000200009.
3. Malav DR, Thakrar DR. Aakash Solanki et al. Artifacts-The Black Spot of CBCT. *J Government Dent Coll Hosp.* 2016;2(2):5–10.
4. Chindasombatjareon J, Kakimoto N, Murakami S, Maeda Y, Furukawa S. Quantitative analysis of metallic artifacts caused by dental metals: comparison of cone-beam and multi-detector row CT scanners. *Oral Radiol.* 2011;27:114–20.
5. Holberg C, Steinhäuser S, Geis P, Janson IR. Cone-beam computed tomography in orthodontics: benefits and limitations. *J Orofac Orthop.* 2005;66(6):434–44. doi:10.1007/s00056-005-0519-z.
6. Esmaeili F, Johari M, Haddadi P. Beam hardening artifacts by dental implants: comparison of cone-beam and 64-slice computed tomography scanners. *Dent Res J.* 2013;10(3):376–81.
7. Liang X, Jacobs R, Hassan B. A comparative evaluation of cone beam computed tomography (CBCT) and multi-slice CT (MSCT). Part I. On subjective image quality. *Eur J Radiol.* 2010;75(2):265–9. doi:10.1016/j.ejrad.2009.03.042.
8. Jin SO, Kim JG, Lee SY, Kwon OK. Bone‑induced streak artifact suppression in sparse‑view CT image reconstruction. *Biomed Eng Online.* 2012;11:44. doi:10.1186/1475-925X-11-44.
9. Schulze R, Heil U, Groß D, Bruellmann DD, Dranischnikow E, Schwanecke U. Artefacts in CBCT: A review. *Dentomaxillofac Radiol.* 2011;40(5):265–73. doi:10.1259/dmfr/30642039.
10. Makins RS. Artifacts interfering with interpretation of cone beam computed tomography images. *Dent Clin North Am.* 2014;58(3):485–95. doi:10.1016/j.cden.2014.04.007.
11. Bhoosreddy AR, Sakhavalkar UP. Image deteriorating factors in cone beam computed tomography, their classification, measure to reduce them: A pictorial essay. *J Indian Acad Oral Med Radiol.* 2014;26(3):293–7. doi:10.4103/0972-1363.145009.
12. Barrett JF, Keat N. Artifacts in CT: Recognition and avoidance. *Radiographics.* 2004;24(6):1679–91.
13. Scarfe WC, Farman AG. What is cone beam CT and how does it work? *Dent Clin North Am.* 2008;52(4):707–30. doi:10.1016/j.cden.2008.05.005.
14. Lu W, Parikh PJ, Hubenschmidt JP, Polite DG, Whiting BR, Bradley JD. Reduction of motion blurring artifacts using respiratory gated CT in sinogram space: A quantitative evaluation. *Med Phys.* 2005;32(11):3295–304. doi:10.1118/1.2074187.
15. Kincade K. Cone beam CT artifacts: What’s a dentist to do? *Dentomaxillofac Radiol.* 2011;5(6):440–5. doi:10.4103/2231-0762.170523.
16. Nabha W, Hong YM, Cho JH, Hwang HS. Assessment of metal artifacts in three dimensional dental surface models derived by cone‑beam computed tomography. *Korean J Orthod.* 2014;44(5):229–35. doi:10.4041/kjod.2014.44.5.229.
17. Bechara B, McMahan CA, Moore WS, Noujeim M, Geha H, Teixeira FB. Contrast noise ratio difference in small field of view cone beam computed tomography machines. *J Oral Sci.* 2012;54(3):227–32. doi:10.2334/josnusd.54.227.
18. Watanabe H, Honda E, Tetsumura A, Kurabayashi T. A comparative study for spatial resolution and subjective image characteristics of a multi-slice CT and a cone-beam CT for dental use. *Eur J Radiol.* 2011;77(3):397–402. doi:10.1016/j.ejrad.2009.09.023.
19. Ludlow JB, Ivanovic M. Comparative of dental cbct devices and 64-slice ct for oral and maxillofacial radiology. *Oral Surg Oral Med Oral Pathol Oral Radiol Endod.* 2008;106(1):106–14. doi:10.1016/j.tripleo.2008.03.018.
20. Hunter AK, McDavid WD. Characterization and correction of cupping effect artefacts in cone beam CT. *Dentomaxillofac Radiol.* 2012;41(3):217–23. doi:10.1259/dmfr/19015946.

Author biography

Sujeev N, Associate Professor  <https://orcid.org/0000-0003-1248-800X>

Anusha R.L., Consultant Oral and Maxillofacial Radiologist
 <https://orcid.org/000-0001-8390-7203>

Renita Castelino, Reader  <https://orcid.org/0000-0002-8696-549X>

Praveenkumar Ramdurg, Professor  <https://orcid.org/0000-0001-8575-3666>.

Cite this article: Sujeev N, Anusha R.L, Castelino R, Ramdurg P. Artifacts — A hitch in CBCT. *IP Int J Maxillofac Imaging* 2021;7(4):169-173.