

Content available at: <https://www.ipinnovative.com/open-access-journals>

IP International Journal of Maxillofacial Imaging

Journal homepage: <https://www.ijmi.in/>

Case Report

Mandibular first molar with radix entomolaris: A case report

Sampann Chowdhry¹, Ashish Kamboj^{2,*}, S S Chopra³, Nishant Sinha¹, Atul Bali²,
Gagandeep Kochar²

¹Dept. of Endodontics, Govt. Dental Center, Leh, Ladakh, India

²Dept. of Orthodontics, Govt. Dental Center, Leh, Ladakh, India

³Dept. of Dental Surgery, Armed Forces Medical College Pune, Maharashtra, India



ARTICLE INFO

Article history:

Received 10-12-2021

Accepted 25-12-2021

Available online 25-01-2022

Keywords:

Anatomic variations

Endodontic treatment

Mandibular first molar

Radix entomolaris

ABSTRACT

Anatomic variations of mandibular molars are documented in literature. Variations in the anatomy are not appreciated by a great number of general dental practitioners. One such variation is occurrence of radix entomolaris, a supernumerary root occurring on the disto-lingual aspect of mandibular molars. This anomaly is rarely known to occur in the Indian population. Literature has also shown that the knowledge about the variations in the distal root anatomy in mandibular molars is not commonly known. This case reports the occurrence of radix entomolaris in mandibular first molar with three roots and four root canals. The case report discusses the frequency of occurrence, diagnostic means and endodontic management of radix entomolaris.

This is an Open Access (OA) journal, and articles are distributed under the terms of the [Creative Commons Attribution-NonCommercial-ShareAlike 4.0 License](https://creativecommons.org/licenses/by-nc-sa/4.0/), which allows others to remix, tweak, and build upon the work non-commercially, as long as appropriate credit is given and the new creations are licensed under the identical terms.

For reprints contact: reprint@ipinnovative.com

1. Introduction

The main objective of root canal treatment is thorough mechanical and chemical shaping and cleaning of the entire pulp canal cavity followed by complete obturation which prevents the development of any periapical pathology and also promotes healing of already existing endodontic pathology.¹ Therefore, it is of utmost importance for the clinician to be familiar and aware of the unusual canal anatomy for the successful outcome of endodontic therapy.

Mandibular first molar is known to display several anatomical variations.¹ In most cases the mesial root has two root canals ending in two different foramina, or sometimes they may merge and exit as a single foramen.² The distal root typically has kidney shaped canal anatomy but a round apical foramen.³

Other major variant in this tooth is the presence of an additional third root. The literature reports the presence of an extra disto-lingual root, Radix Entomolaris (RE)³ and mesio-buccal root, Radix Paramolaris (RP).⁴

2. Case Report

A 38 year old patient reported to dental care facility, with a chief complaint of severe, continuous pain on the lower left side of his jaw for past one week. On detailed history taking, the patient revealed that the pain was continuous, throbbing in nature, radiating to temporal and auricular region, the pain aggravated on eating anything hot and sweet and he also gave a history of disturbed sleep.

An intra-oral examination revealed a deep occlusal caries with respect to 36, the tooth was tender on vertical percussion and had no signs of sinus opening or swelling. The mobility and probing depths were within normal physiological limits.

* Corresponding author.

E-mail address: aashishkamboj@gmail.com (A. Kamboj).

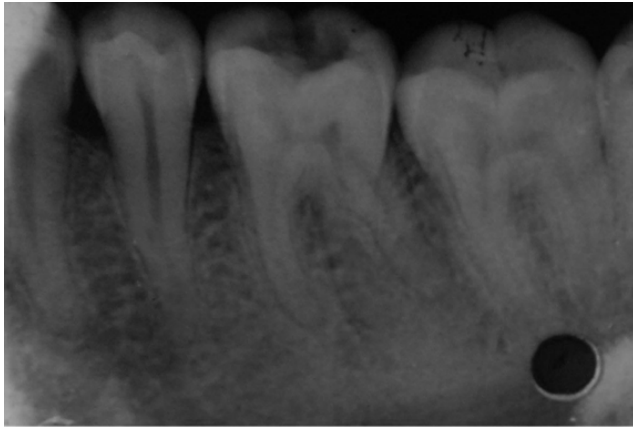


Fig. 1: Pre-operative radiograph

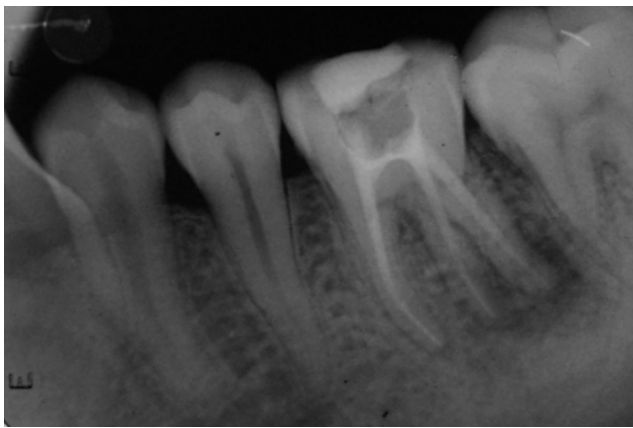

Fig. 2: Post-operative radiograph

Radiographic examination revealed, a radiolucency involving pulp with obliteration of periodontal ligament space periapically with respect to mesial and distal roots. The medical history of the patient was non-contributory.

A final diagnosis of symptomatic irreversible pulpitis with acute apical periodontitis with respect to 36 was arrived at and the patient was advised to undergo endodontic therapy.

The tooth was tender to any type of manipulation, hence a mandibular nerve block was administered using 1.8ml 2% lignocaine with 1:80,000 concentration of adrenaline. The access cavity was established, and three canal orifices were located initially on the pulpal floor and a dentin overhang was observed disto-lingually. Also, it was observed that the canal orifice of the distal root was located disto-buccally, which according to law of orifice location gives an indication about the presence of another canal orifice disto-lingually. Therefore, the triangular access cavity was modified to a trapezoidal shape to aid in the location of the fourth canal orifice. On clinical examination mesio-buccal, mesio-lingual, disto-buccal and disto-lingual orifices were observed. The presence of radix entomolaris was evident on the radiograph which was taken from mesial angulation of 30° [Figure 1].

3. Discussion

The occurrence of a radix entomolaris is known to show racial and genetic prevalence (Table 1). In Indian population the prevalence has been reported to be as low as 0.2%.⁵ In Indians of Canadian origin the occurrence being as high as 16%.⁶ This macro structure shows highest racial prevalence in Eskimos (Keewatin 27% and Baffin 21.7%)^{7,8} and Chinese 21.5%.⁷ Thai and Japanese also show a prevalence of 19% to 17.8%.^{9,10}

The occurrence of radix entomolaris shows a dominant genetic pattern which was reflected in the fact that the pure Eskimos and the Eskimo-Caucasian mixed populations had the similar prevalence rate of the trait. The genetic prevalence also showed Atavism or polygenetic system, which is the re-appearance of a trait after several generations of absence. Its presence has also been attributed to the presence of external factors during Odontogenesis. Radix Entomolaris can be found on the first, second and third molars, occurring least commonly on the second molar.

The presence of radix entomolaris has clinical implications in endodontics, therefore an accurate diagnosis of these supernumerary roots can avoid any complications. A proper pre-operative evaluation of radiograph is of foremost importance while diagnosing radix entomolaris because it generally occurs in the same bucco-lingual plane as the disto-buccal root causing superimposition of both. Hence, the tooth involved should be studied from three different horizontal projections i.e, the standard bucco-lingual projections (ortho-axial projection), 30° from the

Table 1: Showing incidence of racial prevalence of Radix Entomolaris.

Author/Year	Prevalence (%)	Population Group
Taylor (1899)	3.4	United Kingdom
Tratman (1938)	5.8	Chinese
Tratman (1938)	0.2	Indians
Skidmore and Bjorndal (1972)	2.2	Caucasians
Yones et al (1990)	2.92	Saudi
Loh (1990)	7.9	Chinese (Singapore)
Yew and Chan (1993)	21.5	Chinese
Sperber and Moreau (1998)	3.0	Senegalese
Gulabivala et al (2001)	10.1	Burmese

mesial and 30° from the distal reveals the basic information regarding the anatomy of the tooth in order to perform endodontic treatment.

Apart from a radiographical diagnosis and analysis, the clinical inspection of orifice of RE during access cavity preparation is very important. The orifice of RE is generally located disto-lingual from the main canal and generally a calcification is known to be present over the orifice which should be removed for better view and access.¹¹ Visual aids such as loupes, intra-oral camera, surgical operating microscope can also be useful adjuncts. Clinically, an extra cusp or more prominent occluso-distal or disto-lingual lobe, in combination with a cervical prominence and convexity can indicate the presence of an extra additional root.¹²

4. Conclusion

The high frequency of variations in mandibular first molars makes it essential to anticipate and find all canals during root canal treatment. The possibility of an extra root should also be considered and looked for carefully. Proper angulation and interpretation of radiographs help to identify chamber and root anatomy. In the case of an RE the conventional triangular opening cavity is modified to a trapezoidal form in order to better locate and access the disto-lingually located orifice of the additional root.

The presence of a supernumerary root can have clinical implications in endodontics hence, an accurate diagnosis prior to the commencement of treatment is of paramount importance.

5. Source of Funding

None.

6. Conflict of Interest

None.

References

1. Barker BC, Parson KC, Mills PR, Williams GL. Anatomy of root canals III. Permanent mandibular molars. *Aust Dent J*. 1974;19:403–

416.

2. Campos F, H. Unusual root anatomy of mandibular first molar. *Int Endod J*. 1985;11:568–77.
3. Bolk L. Welcher Gebibreihe gehören die Molaren. *Z Morphol Anthropol*. 1914;17:83–116.
4. Carabelli G.
5. Sperber GH, Moreau JL. Study of the number of roots and canals in the Senegalese first mandibular molars. *International Electr. Journal*. 1998;31:117–139.
6. Tratman EK. Three rooted lower molars in man and their racial distribution. *British Dent J*;1938:264–74.
7. Turner CG, II. Three rooted mandibular molars and the question of American Indian Origins. *American J of Physc Anthropol*. 1971;34:229–270.
8. Curzon M. Miscegenation and the prevalence of three rooted mandibular first molars in Baffin Eskimos. *Community dentistry and Epidem*. 1974;2:130–131.
9. Sc Y, Chan K. A retrospective study of endodontically treated mandibular first molars in a Chinese population. *J of Endod*. 1993;19:471–474.
10. Calberson FL, Reoland J. The radix entomolaris and paramolaris: clinical approach in endodontics. *J of Endodon*. 2007;33(1):58–63.
11. Garg A, Tewari R, Kumar A, Hashmi SH, Aggarwal N, Mishra S. Prevalence of three rooted mandibular first molar among Indian population. *J Endod*. 2010;36:1302–1308.
12. Nagaven NB, Umashankara KV. *J Indian Soc Pedod Prev Dent*. 2012;30(2):94–102.

Author biography

Sampann Chowdhry, Graded Specialist

Ashish Kamboj, Classified Specialist

S S Chopra, Professor

Nishant Sinha, Graded Specialist

Atul Bali, Classified Specialist

Gagandeep Kochar, Classified Specialist

Cite this article: Chowdhry S, Kamboj A, Chopra SS, Sinha N, Bali A, Kochar G. Mandibular first molar with radix entomolaris: A case report. *IP Int J Maxillofac Imaging* 2021;7(4):186-188.