

Content available at: <https://www.ipinnovative.com/open-access-journals>

IP International Journal of Maxillofacial Imaging

Journal homepage: <https://www.ijmi.in/>

## Case Report

# Rehabilitation of partial edentulous patient with tooth supported over denture retained with metal coping-A case report

Poonam Wakure<sup>1,2,\*</sup>, Maqbul Alam<sup>2</sup>, Manu Rathee<sup>2</sup>, Sanju Malik<sup>2</sup>, Divakar. S<sup>2</sup>

<sup>1</sup>Dept. of Prosthodontics, Pandit Bhagwat Dayal Sharma University of Health Science, Rohtak, Haryana, India

<sup>2</sup>Dept. of Prosthodontics, Post Graduate Institute of Dental Science & PGIDS, Rohtak, Haryana, India



### ARTICLE INFO

#### Article history:

Received 26-11-2021

Accepted 12-01-2022

Available online 25-01-2022

#### Keywords:

Bone Prevention

Bone Resorption

Metal Copings

Proprioception

Tooth Supported Overdenture

### ABSTRACT

Overdenture treatment is a removable dental prosthesis that covers or rest on one or more remaining natural teeth, roots of natural teeth, or dental implants. The conventional tooth-retained overdenture is a simple and cost-effective treatment than the implant overdenture. This treatment is not a new concept and practitioners have successfully employed existing tooth structures to assist with complete denture treatment for more than a century. Furthermore, the use of copings on the remaining teeth enhances the retention of the denture. This clinical report describes a method of fabricating a tooth supported overdenture retained with custom made metal coping.

This is an Open Access (OA) journal, and articles are distributed under the terms of the [Creative Commons Attribution-NonCommercial-ShareAlike 4.0 License](https://creativecommons.org/licenses/by-nc-sa/4.0/), which allows others to remix, tweak, and build upon the work non-commercially, as long as appropriate credit is given and the new creations are licensed under the identical terms.

For reprints contact: [reprint@ipinnovative.com](mailto:reprint@ipinnovative.com)

## 1. Introduction

Overdenture treatment is a removable dental prosthesis that covers or rest on one or more remaining natural teeth, roots of natural teeth, or dental implants.<sup>1</sup> We can consider tooth-supported overdentures as a useful treatment choice for older patients since it provides better retention, support, and stability than conventional removable dentures, as well as provide proprioception and prevent alveolar bone loss.<sup>2</sup> The loss of teeth, especially mandibular teeth, frequently leads to a rapid reduction in the height of the alveolar process. The inherent problems with mandibular complete denture can be easily overcome by fabrication of tooth supported overdenture.<sup>3</sup> Timely planned root supported overdenture has been proven mainstay of preventive prosthodontics therapy as it attempts to conserve the remaining natural teeth and reducing alveolar bone resorption.<sup>4,5</sup> This clinical report describes a method of fabricating a tooth supported overdenture retained with custom made metal coping.

## 2. Case Report

A 60-year-old male patient reported to the Department of Prosthodontics, with the chief complaint of difficulty in chewing due to broken lower teeth. There was no relevant medical history. On extraoral examination, face was bilaterally symmetrical, lips were thick and adequately supported, temporomandibular joint had no abnormality and no palpable nodes were seen (Figure 1). On intraoral examination, it had been found that the patient had a complete edentulous maxillary arch and a partially edentulous mandibular arch. The patient had a low well-round maxillary arch. 31, 32, 33, 38, 41, 42, 44 were present in the mandibular arch and radiographic examination revealed good bone support and long roots. Phonetic examination revealed sufficient inter-arch space (Figure 2).

The different treatment options available for this patient's rehabilitation were-extraction of the remaining teeth followed by a conventional complete denture, implant-supported overdenture, and tooth-supported overdenture. The patient rejected the choice of an implant-retained

\* Corresponding author.

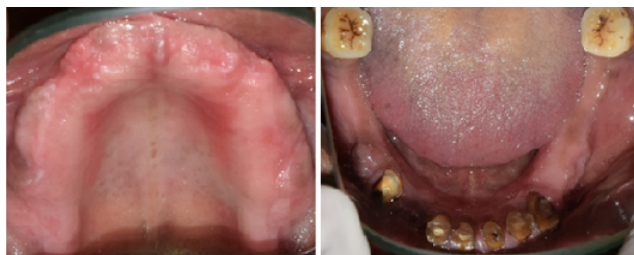E-mail address: [drpoonamwakure@gmail.com](mailto:drpoonamwakure@gmail.com) (P. Wakure).

prosthesis due to the necessity for extra surgery, the longer duration of the treatment phase, and related expenditure. Complete upper denture and tooth-supported lower overdenture were planned for the patient.

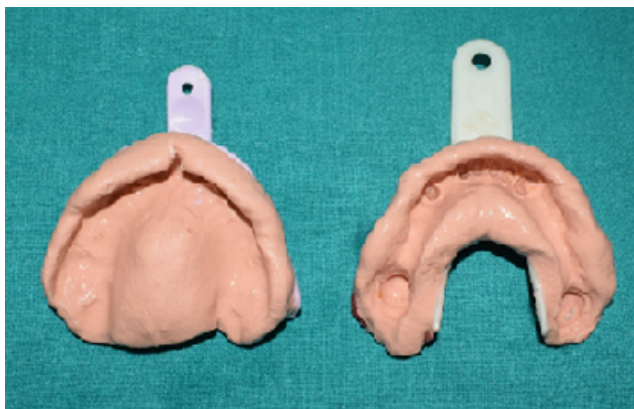
Diagnostic primary impressions were made with reversible hydrocolloid (Zelgan, Dentsply) impression material using edentulous stock trays (Figure 3). To obtain a favourable crown root ratio and avoid encroachment of the teeth into the interocclusal space, endodontic treatment was carried out for remaining teeth and tooth preparation was completed. The abutment teeth were reduced in vertical height to 2mm above crest of the ridge. A dome-shaped preparation with a chamfer finish line was done for all the teeth. The preparation rounded to minimize the horizontal torque on the roots (Figure 4).



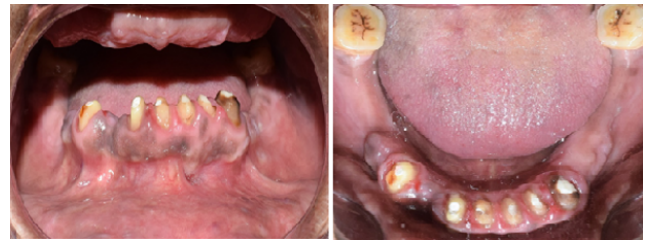**Fig. 1:** Preoperative view



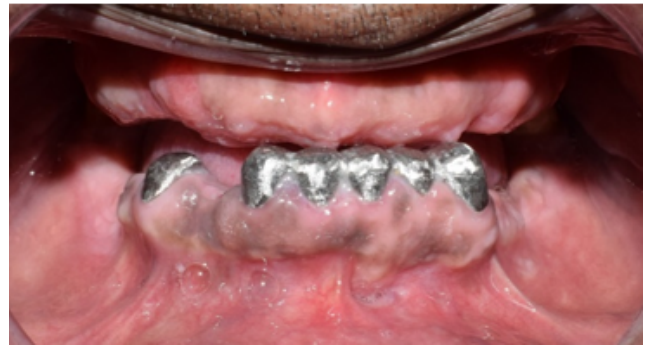**Fig. 2:** Intraoral examination



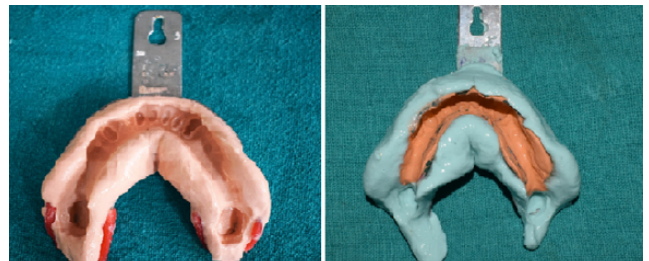**Fig. 3:** Diagnostic impression



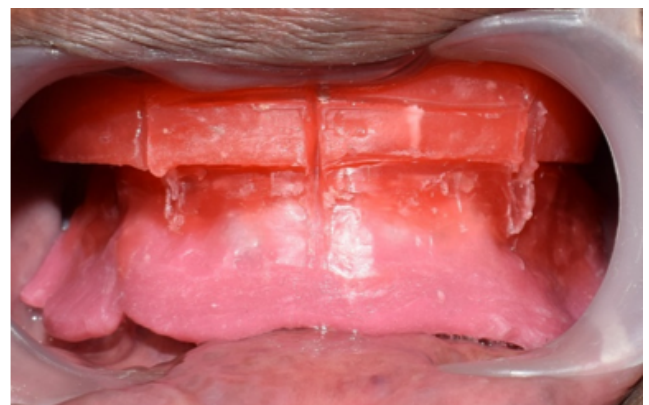
**Fig. 4:** Intraoral view after teeth preparation



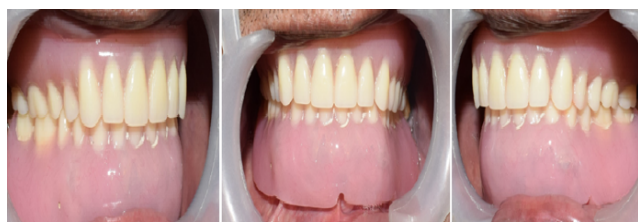**Fig. 5:** Metal coping luted on prepared teeth



**Fig. 6:** Primary and final impression for mandibular arch.



**Fig. 7:** Maxillomandibular relation



**Fig. 8:** Final prosthesis.

The metal copings were fabricated on the obtained casts and finished and tried in the patient's mouth and were luted on the abutment teeth (Figure 5).

A primary impression of the maxillary and mandibular arch were made with irreversible hydrocolloid (Zelgan, Dentsply) impression material followed by the fabrication of special tray (2 mm shorter), with handle in palatal region. The final pick-up impression was made using zinc oxide eugenol paste (DPI impression paste) and alginate. The impression was poured in a dental stone and base denture base was fabricated on secondary cast (Figure 6). Occlusal wax rims were made and facebow transfer was done, which was followed by a recording the maxillomandibular relation (Figure 7). Teeth arrangement was done and a try-in was accomplished. After a satisfactory try-in, the waxed-up denture was processed using heat cure acrylic. The mandibular denture has recess areas on the intaglio surface of the denture to accommodate the abutments. The dentures were finished, polished, and inserted into the patient's mouth (Figure 8). Proper oral hygiene instructions along with practice for removal and insertion of the mandibular denture were given to the patient. The patient was recalled for periodic follow-up appointments.

### 3. Discussion

There has been an increase in the provision of implant-supported prostheses in patients who are unable to tolerate conventional dentures. Unfortunately, many patients are still not able to take benefit from this treatment option because of anatomical, medical, or financial constraints.<sup>6</sup> Preventive prosthodontics deals with the use of procedures to delay or eliminate any kind of future problems that may be faced by the patient.<sup>7</sup> Tooth supported overdenture is a part of preventive prosthodontics which helps to increase masticatory performance, positive psychological behaviour, periodontal health of the abutment roots and decrease the progressive reduction of the residual ridges. Benefits of conventional overdenture are that it has better retention in many situations, relieves pressure on alveolar ridge. The coping protects the abutment tooth from caries and thermal irritations and provides the basic element for retention and stabilization for the outer part.<sup>1</sup>

Langer et al., use of telescope retainers for stabilization and retention of removable dental restorations. A double

crown design is used in the telescope unit. The unit is made up of a primary coping that is permanently attached to the abutment tooth and a secondary or outer crown that is tightly anchored in the removable denture. To form a telescope retainer unit, the secondary crown engages the first coping.<sup>8</sup> Crum and Rooney et al., graphically demonstrated in 5 years study an average loss of 0.6 mm of vertical bone in the anterior part of the mandible of overdenture patients through cephalometric radiographs as against 5.2 mm loss in complete denture patients.<sup>9</sup>

Miller et al., in his study concluded that alveolar bone resorption depends upon three variables which are the character of the bone, the health of the individual, the amount of trauma to which the structures are subjected.<sup>10</sup> Rissin et al., compared masticatory performance in patients with natural dentition, complete denture, and overdenture. They found that the overdenture patients had a chewing efficiency one third higher than the complete denture patients.<sup>11</sup>

### 4. Conclusion

The overdenture has innumerable advantages and applications compared to a conventional complete denture. Complete upper denture and tooth-supported lower overdenture were planned for this patient. This technique is simple to execute and follows the principles of preventive prosthodontics at every step of fabrication. Regular recall visits were maintained and the patient was very comfortable, happy and confident with new dentures.

### 5. Source of Funding

None.

### 6. Conflict of Interest

None.

### References

1. Samara RK, Bhide SV, Goyal C, Kaur T. Tooth supported overdenture: A concept overshadowed but not yet forgotten. *J Oral Res Rev.* 2015;7(1):16–21. doi:10.4103/2249-4987.160172.
2. Kaur A, Padiyar N, Kaurani P, Meena S. Tooth and implant supported over denture: a case report. *Int J Commun Health Med.* 2017;3(2):33–6.
3. Bansal S, Aras MA, Chitre V. Tooth Supported Overdenture Retained with Custom Attachments: A Case Report. *J Indian Prosthodont.* 2014;14(1):283–6. doi:10.1007/s13191-013-0340-0.
4. Morrow RM. Handbook of immediate overdentures; 1978. p. 48.
5. Castleberry DJ. Philosophies and principles of removable partial overdentures. *Dent Clin North Am.* 1990;34(4):589–92.
6. Vere J, Deans RF. Tooth-supported, magnet-retained overdentures: a review. *Dental Update.* 2009;36(5):308–8. doi:10.12968/denu.2009.36.5.305.
7. Kalp C, Prasad KV. Seeing the unseen: Preventive Prosthodontics: use of overlay removable dental prosthesis. *Annals Essences Dent.* 2010;2(3):44–9. doi:10.5368/aedj.2010.2.3.44-49.pdf.

8. Langer A. Telescope retainers and their clinical application. *J Prosthetic Dent.* 1980;44(5):516–22. doi:10.1016/0022-3913(80)90070-0.
9. Crum RJ, Rooney GE. Alveolar bone loss in overdentures: a 5-year study: . *J Prosthetic Dent.* 1978;40(6):610–3. doi:10.1016/0022-3913(78)90054-9.
10. Miller PA. Complete dentures supported by natural teeth. *J Prosthetic Dent.* 1965;8(6):924–8. doi:10.1016/0022-3913(58)90122-7.
11. Rissin L, House JE, Manly RS, Kapur KK. Clinical comparison of masticatory performance and electromyography activity of patients with complete dentures, overdentures, and natural teeth. *J Prosthetic Dent.* 1978;39(5):508–19. doi:10.1016/s0022-3913(78)80181-4.

### Author biography

**Poonam Wakure**, P G Student

**Maqbul Alam**, P G Student

**Manu Rathee**, Professor and Head of Department

**Sanju Malik**, Senior Resident

**Divakar. S**, P G Student

**Cite this article:** Wakure P, Alam M, Rathee M, Malik S, Divakar. S. Rehabilitation of partial edentulous patient with tooth supported over denture retained with metal coping-A case report. *IP Int J Maxillofac Imaging* 2021;7(4):191-194.