

Content available at: <https://www.ipinnovative.com/open-access-journals>

IP International Journal of Maxillofacial Imaging

Journal homepage: <https://www.ijmi.in/>

Case Report

Infected dentigerous cyst in maxillary antrum mimicking maxillary sinusitis

Chandan Misra¹, Ashish Kamboj^{1,*}, SS Chopra², Nishant Sinha¹,
Debapreeti Mohanty³, Barnali Mandal⁴

¹Government Dental Centre, Leh (UT of Ladakh), India

²Dept. of Dental Surgery, Armed Forces Medical College Pune, Maharashtra, India

³Dept. of Conservative Dentistry, KIDS, KIIT-DU, Bhubaneswar, Odisha, India

⁴Smilekraft Multispeciality Dental Clinic, Kolkata, India



ARTICLE INFO

Article history:

Received 21-09-2022

Accepted 29-09-2022

Available online 10-10-2022

Keywords:

Cyst

Dentigerous cyst

Maxillary antrum

ABSTRACT

Cyst is defined as a pathological cavity which may or may not be lined by an epithelium and is usually filled with solid, semisolid or gaseous material. Dentigerous cyst is of odontogenic origin and is usually associated with an impacted tooth. Dentigerous cyst in maxillary antrum is often misdiagnosed in peripheral health care centers due to initial complaints mimicking maxillary sinusitis with patients reporting to general physicians/otolaryngologist for treatment. This article intends to report a case of infected dentigerous cyst initially managed as recurrent maxillary sinusitis in a peripheral rural health care center in high altitude region with limited health care facilities.

This is an Open Access (OA) journal, and articles are distributed under the terms of the [Creative Commons Attribution-NonCommercial-ShareAlike 4.0 License](https://creativecommons.org/licenses/by-nc-sa/4.0/), which allows others to remix, tweak, and build upon the work non-commercially, as long as appropriate credit is given and the new creations are licensed under the identical terms.

For reprints contact: reprint@ipinnovative.com

1. Introduction

Kramer (1974) has defined a cyst as ‘a pathological cavity having fluid, semifluid or gaseous contents and which is not created by the accumulation of pus’. Most cysts, but not all, are lined by epithelium.¹ Odontogenic cysts are the variety in which the lining of the lumen is usually derived from epithelium or its remnants produced during tooth development.

Dentigerous cyst, sometimes known as a follicular cyst is a true odontogenic cyst which encloses the crown of an unerupted tooth by expansion of its follicle, and is attached to its neck at the cemento-enamel junction. Dentigerous cyst is the second most common odontogenic cyst in the Indian population.² These cysts may be classified into two major types based on etiology and stage of development. The first type is formed due to the degeneration of stellate reticulum

cells in the early stages and is often associated with enamel hypoplasia. The other type, not associated with enamel hypoplasia is formed due to fluid accumulation between the reduced enamel epithelium (REE) and the completed crown.^{3,4}

Dentigerous cyst are usually asymptomatic, unless secondarily infected or attaining dimensions large enough to cause bony expansion or pain. They are usually incidentally detected during radiographic examination of a missing tooth. The most common site for the occurrence is mandibular posterior region involving the mandibular third molars followed by the maxillary third molar, maxillary premolar or the maxillary canine.⁵ Dentigerous cyst encompasses for about 16.2% to 37.5% incidence of epithelium-lined cysts in the maxilla.⁶

Due to the nonconspicuous clinical features, secondarily infected dentigerous cyst in the maxillary antrum is often misdiagnosed by general physicians in peripheral health care centres where patients usually report due to the lack

* Corresponding author.

E-mail address: aashishkamboj@gmail.com (A. Kamboj).

of specialised dental care facilities in the rural areas. A cyst in the maxillary sinus may displace and obliterate the nasal cavity and maxillary antrum mimicking signs of maxillary sinusitis.

In this article, we report a case of a 21 year old girl having a giant infected dentigerous cyst in relation to right maxillary antrum who was initially treated for recurrent maxillary sinusitis in a rural health care facility.

2. Case Report

A 21 year old girl was referred to our dental centre with chief complaints of pain, nasal stuffiness and recurrent swelling in right side mid face region since last 7 months. (Figure 1) The patient, native to a remote location in Ladakh region of India, had initially reported to the primary health centre where she was diagnosed as a case of recurrent maxillary sinusitis and managed with antibiotics and steam inhalation therapy. With the complaints recurring every 15-20 days and swelling in the midface region gradually increasing in dimensions, she was referred to our dental centre which is attached to a speciality hospital for further management.

Initial clinical examination revealed mild, diffused, non tender, non fluctuant swelling in right maxillary region. Intraorally, there was no obliteration of maxillary buccal vestibule or areas of tenderness. 18 was clinically missing and 14, 15 were tender on vertical percussion. Radiographic examination with Paranasal sinus and Lateral skull view radiograph revealed well defined unilocular radiolucent lesion in rt maxillary antrum with signs of adjacent bone expansion and destruction and impacted 18 located within the lesion around posterolateral margin of the maxillary antrum. (Figures 2 and 3) Aspiration through the weakened anterolateral wall of rt maxillary antrum revealed straw coloured fluid mixed with pus conglomerates. Based on clinicoradiologic parameters, a provisional diagnosis of cystic lesion in rt maxillary antrum was made.

Patient was managed with enucleation of cystic lesion with impacted tooth via Caldwell-Luc approach. (Figures 4, 5 and 6) Histopathologic examination of the specimen revealed hyperplastic stratified squamous epithelium lining the cystic lumen. The cyst wall contained young fibroblast separated by stroma and acid mucopolysaccharide rich ground substance. The fibrous connective tissue had diffuse chronic inflammatory infiltrate.

All the histopathologic along with clinicoradiologic features led to confirmatory diagnosis of secondarily infected giant dentigerous cyst of right maxillary antrum. The patient is under follow up for the past two years with no recurrence of clinical symptoms.




Fig. 1: Pretreatment extraoral frontal view photograph

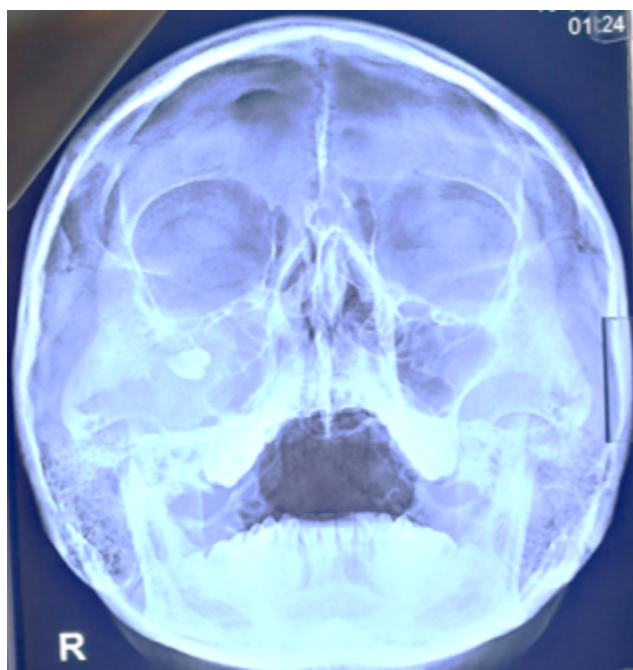


Fig. 2: Paranasal sinus view

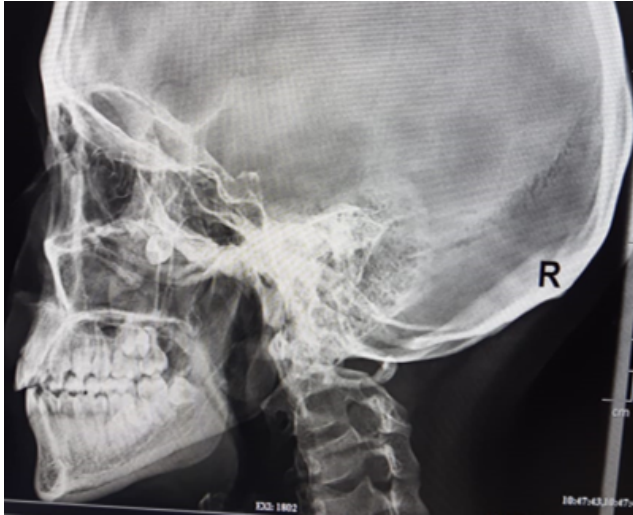


Fig. 3: Lateral skull view

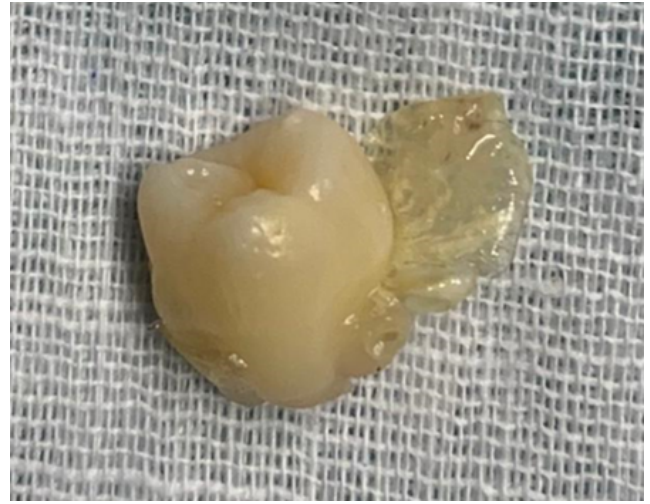

Fig. 6: Impacted molar

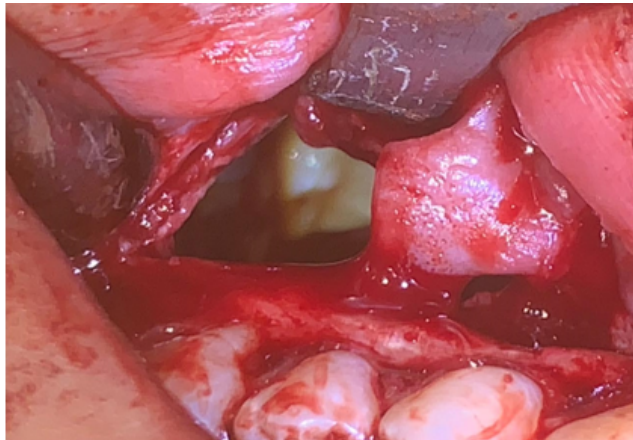


Fig. 4: Caldwell-luc approach

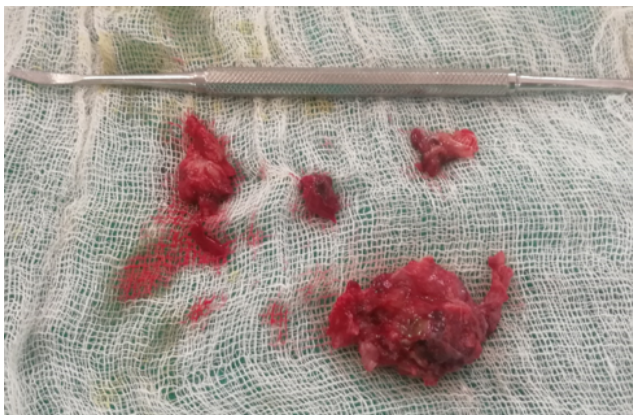


Fig. 5: Enucleated cystic lesion

3. Discussion

The dentigerous cyst is defined as a cyst that originates by the separation of the follicle from around the neck of crown of an unerupted tooth secondary to fluid accumulation between the reduced enamel epithelium and the enamel surface. It is important that this definition be applied strictly and that the diagnosis of dentigerous cyst is not made uncritically on radiographic evidence alone, otherwise keratocysts (OKCs) of the envelopmental variety (Main, 1970a), follicular OKCs (Altini and Cohen, 1982, 1987) and unilocular ameloblastomas involving adjacent unerupted teeth, are at risk of being misdiagnosed as dentigerous cysts.⁷

Carcinoma arising in a dentigerous cyst is extremely rare, with a review of literature showing fewer than 20 cases.⁸ Gardner in 1969 had published an excellent review of epidermoid carcinoma arising from cystic linings. Gardner's criteria for diagnosis of carcinoma arising in a dentigerous cyst are as follows:

1. a microscopic transition area from benign cystic epithelial lining to invasive malignant squamous cell carcinoma
2. no carcinomatous change(s) in the overlying epithelium
3. no source of carcinoma in the adjacent structures.

These criteria have been widely accepted.^{9,10} However, transition of the cystic lining is possible only during the earliest stages of malignant transformation; identifying the precise area of origin can be difficult.¹¹

Radiographically, dentigerous cyst presents as unilocular radiolucent areas with well-defined sclerotic margins associated with the crown of unerupted teeth. Occasionally, trabeculations may be seen and this may give an erroneous impression of multilocularity. A dentigerous cyst should be

suspected when the follicular space around an impacted tooth is more than 5 mm.⁷

Several lesions may radiographically morph a dentigerous cyst and must be differentiated. These include unicystic ameloblastoma, adenomatoid odontogenic tumor, early stages of Gorlin cyst/calcifying epithelial odontogenic tumor, ameloblastic fibroma, ameloblastic fibro-odontoma and odontogenic keratocyst.^{4,12}

The accepted modality of management of dentigerous cysts is either marsupialization (Partsch I), enucleation or marsupialization followed by enucleation (Partsch II) depending on the age of the patient, location and dimensions of the lesion. Surgical intervention usually cures the lesion with minimal incidences of recurrence.

4. Conclusion

Dentigerous cyst may be occasionally found in the maxillary antrum with a patient presenting with local sinonasal symptoms commonly attributed to recurrent sinusitis, rhinorrhoea, unilateral nasal obstruction or epiphora. Considering the incidences of various odontogenic lesions in maxillary sinus and potential for malignant conversions of untreated dentigerous cysts, it is imperative that patients with repeated episodes of maxillary sinusitis be referred to dental speciality to rule out and if diagnosed, ensure definitive prompt management of odontogenic cystic lesions.

5. Source of Funding

None.

6. Conflict of Interest

None.

References

1. Castro J. Cysts of the maxillofacial region ; 2019. p. 241.
2. Kambalimath DH, Kambalimath HV, Agrawal SM, Singh M, Jain N, Anurag B. Prevalence and distribution of odontogenic cyst in Indian

population: A 10 year retrospective study. *J Maxillofac Oral Surg.* 2014;13(1):10–5.

3. Shear M, Speight PM. Odontogenic keratocyst, in cysts of the oral and maxillofacial regions. Copenhagen; 2007. p. 59–75.
4. Pai N, Shemna SS, Dubey PN, Poddar P. Infected dentigerous cyst in the maxilla: Report of two cases. *Indian J Dent Sci.* 2020;12(1):244–51.
5. Neville BW, Damm DD, Allen CM, Chi AC. Oral and Maxillofacial Pathology. Philadelphia: Elsevier Health Sciences; 2015. p. 632–7.
6. Teixeira RG, Moraes P, Jodas CR. Decompression of a maxillary dentigerous cyst. *Porto Alegre.* 2011;59(2):299–303.
7. Malik N. Cysts of the maxillofacial region; 2021. p. 549–75.
8. Cavalcanti MGP, Veltrini VC. Squamous-cell carcinoma arising from an odontogenic cyst—The importance of computed tomography in the diagnosis of malignancy. *Am Ass Oral Maxillofac Surg.* 2000;100(3):900–5.
9. Fanibunda K, Soames JV. Malignant and premalignant change in odontogenic cysts. *J Oral Maxillofac Surg.* 1995;53(12):1469–72.
10. Gardner AF. The odontogenic cysts as a potential carcinoma: A clinicopathologic appraisal. *J Am Dent Assoc.* 1969;78(4):746–55.
11. Johnson LM, Sapp JP, Mcintire DN. Squamous cell carcinoma arising from a dentigerous cyst. *J Oral Maxillofac Surg.* 1994;40(8):355–7.
12. Girish G, Kumar M, Umashankar DN, Sharma R, Matamari V, Bhandari A. Dentigerous cyst in maxillary sinus: a rare occurrence. *Int J Oral Maxillofac Pathol.* 2011;2(1):20–3.

Author biography

Chandan Misra, Maxillofacial Surgeon  <https://orcid.org/0000-0002-6971-7021>

Ashish Kamboj, Orthodontist  <https://orcid.org/0000-0002-1836-6786>

SS Chopra, Professor  <https://orcid.org/0000-0002-7983-2541>

Nishant Sinha, Endodontist

Debapreeti Mohanty, Senior Lecturer

Barnali Mandal, Consultant Endodontist

Cite this article: Misra C, Kamboj A, Chopra SS, Sinha N, Mohanty D, Mandal B. Infected dentigerous cyst in maxillary antrum mimicking maxillary sinusitis. *IP Int J Maxillofac Imaging* 2022;8(3):115–118.