



Case Report

A case report of multiple supernumerary teeth: Post-permanent dentition or hyperactivity of dental lamina

Sumalatha CH¹, Srikanth T^{2,*}, Sankeerti Mala B³, Srikanth E⁴, Gowtham P⁵

¹Dept. of Conservative Dentistry and Endodontics, Meghna Institute of Dental Sciences, Nizamabad, Telangana, India

²Dept. of Dentistry, School of Dentistry University of Rwanda, Kigali, Rwanda

³Dept. of Oral and Maxillofacial Pathology, KIMS Dental College & Hospital, Amalapuram, Andhra Pradesh, India

⁴Dept. of Orthodontics and Dentofacial Orthopedics, Meghna Institute of Dental Sciences, Nizamabad, Telangana, India

⁵Private Practitioner, Hyderabad, Telangana, India



ARTICLE INFO

Article history:

Received 20-11-2022

Accepted 06-12-2022

Available online 28-12-2022

Keywords:

Supernumerary teeth

Paramolar

Distomolar

Supplementary teeth

ABSTRACT

Supernumerary teeth in simple terms could be defined as those supernumerary teeth which are well aligned in the arch resembling the normal anatomical structures of teeth. There has been evidences of supplementary premolars and molars since from beginning of the civilization. According to Darwin's theory of evolution which stated that during the course of humans evolution the organs which do not have greater use in regular became vestigial which included the appendix, tail bone, fourth molar. Supernumerary teeth often remain asymptomatic, and only get diagnosed incidentally during a routine dental visit on radiographs. Nevertheless, various complications have been reported in literature related to supernumerary teeth such as disturbed eruption, malpositioning or rotation, root resorption of neighbouring teeth, and development of dentigerous cysts in impacted supernumeraries. Root resorption of neighbouring teeth can be radiographically diagnosed in up to 22.8% of the cases. Here we report an unusual case of multiple supernumerary teeth in a non-syndromic patient of African native.

This is an Open Access (OA) journal, and articles are distributed under the terms of the [Creative Commons Attribution-NonCommercial-ShareAlike 4.0 License](https://creativecommons.org/licenses/by-nc-sa/4.0/), which allows others to remix, tweak, and build upon the work non-commercially, as long as appropriate credit is given and the new creations are licensed under the identical terms.

For reprints contact: reprint@ipinnovative.com

1. Introduction

Any additional teeth in dental arch could be defined as "Supernumerary teeth". The prevalence of these teeth in permanent and primary dentition in various populations is found to be between 0.5- 5.3% and 0.2-0.8%¹ Supernumerary teeth in other terms regarded as hyperdontia which also defined in simpler terms as the presence of an extra number of teeth in relation to the normal dental formula, which might develop at any location in either upper or lower dental arch. While it also has been observed and analyzed that single tooth impaction is not uncommon, development of multiple impacted teeth is a rare condition and often is found in association with syndromes or

developmental anomalies such as Cleidocranial dysplasia, Gardner's syndrome, tricho-rhino-phalangeal syndrome, and cleft lip and palate. The presence of supernumerary teeth has been indicated to cause some modifications in the neighbouring teeth which has been commonly observed as retained teeth or delayed eruption, ectopic eruption, dental malposition, occlusal problems, diastema, and rotation.² General characteristics of supernumerary teeth are as follows:

1.1. Prevalence

Supernumerary teeth are more commonly seen in the Mongoloid racial group with a reported frequency higher than 3%.^{3,4} Koch et al.⁵ stated that the prevalence of supernumerary teeth in the permanent dentition was 1-

* Corresponding author.

E-mail address: gdchhyd@gmail.com (Srikanth T).

3% and the prevalence in primary dentition according to Primosch⁶ was 0.3-0.6%. Rajab and Hamden⁷ stated prevalence in the primary dentition as 0.3-0.8% and in the permanent dentition as 0.1-3.8%.

1.2. Sexual predilection

Rajab and Hamdan reported in their study which was conducted in Jordan, that males were more commonly affected as compared to females, the ratio being 2.2:1.⁷ However, Mitchell reported a 2:1 ratio in favour of males. Hogstrum and Andersson⁸ reported a 2:1 ratio of sex distribution, whereas Luten⁹ reported a sex distribution of 1.3:1. So LLY¹⁰ also found a greater male to female distribution of 5.5:1 in Japanese and 6.5:1 in children in Hong Kong.

1.3. Location

Supernumerary teeth are estimated to occur about 8.2 times more frequently in the maxillary arch than the mandible¹¹ and more commonly affect the premaxilla. Multiple supernumerary teeth are also commonly found in the mandibular premolar region.¹²

1.4. Classification

Supernumerary teeth are classified mainly based on their morphology and location. Garvey et al.¹³ classified them as single or multiple. Single supernumeraries were further classified based on morphology as conical, tuberculate, supplemental and composite odontoma which could be compound or complex. Multiple supernumeraries were classified as those being associated with syndromes and others which are not associated with syndromes.

Primosch⁶ classified supernumeraries into two types according to their shape: supplemental and rudimentary. Supplemental or eumorphic refers to supernumerary teeth of normal shape and size, were also termed as incisiform. Rudimentary or dysmorphic defines teeth of an abnormal shape and smaller in size, including conical, tuberculate, and molariform types.

Kalra also classified supernumerary teeth or hyperdontia according to morphology and number. According to morphology, supernumerary teeth may be further classified as accessory and supplemental. Accessory teeth do not resemble the normal form and have a morphology that deviates from the normal appearance of the teeth. Supplemental teeth are extra teeth but have the shape and size of normal teeth.

Nevertheless, various complications have been reported in the literature for supernumerary teeth such as disturbed eruption, malpositioning/rotation, root resorption of neighbouring teeth, and development of dentigerous cysts in impacted supernumeraries. Root resorption of neighbouring teeth can be radiographically diagnosed in up

to 22.8% of the cases.¹⁴ Here we report an unusual case of multiple supernumerary teeth in a non-syndromic patient of African native.

2. Case Report

A 25-year-old African female reported to the outpatient department with chief complaint of pain in right upper back tooth region for last two days. Familial history and medical history were non contributory. On clinical examination, Extra orally no abnormality was revealed. Intra orally deep dentinal caries was noted in 15 (FDI Notation). Thorough examination of oral cavity revealed 3 supernumerary premolars, two in upper and one in lower arch each. (Figure 1). OPG showed One Supernumerary teeth in relation to 15, Two in relation to^{13,15} Three in relation to 34,35, Two in relation to 44,45. A total of 8 supernumerary teeth were noticed of which 3 were clinically apparent and 5 were impacted. According to the notation given by Sarjeev (2013),¹⁶ these teeth can be notated as α 4S, β 4S, β 5S, γ 4S, γ 5S, γ 3S, δ 3S, δ 5S (Figure 2) The patient was referred to a general physician to rule out the presence of any syndromic etiology. The patient had no complaint with the erupted supernumerary teeth. She was educated with the radiographic findings and adequately counselled regarding the unerupted supernumerary teeth and their associated complications. A regular follow up was undertaken to monitor the.

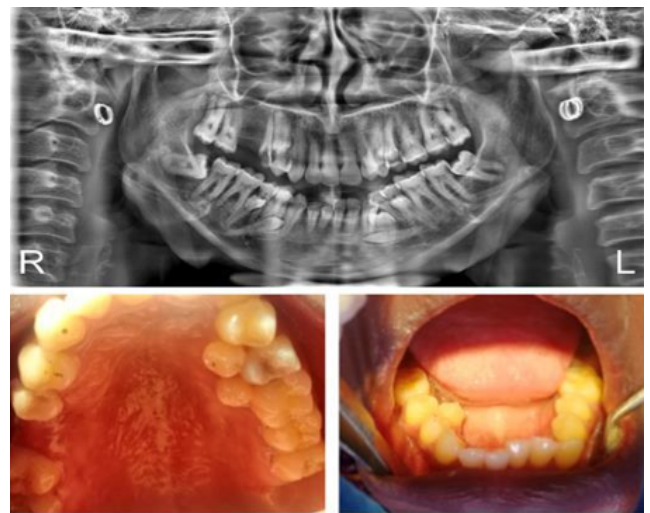

Fig. 1: Clinical and OPG

3. Discussion

Supernumerary teeth are one of the routinely encountered developmental disturbances representing one or more extra teeth in the jaws. These may resemble the teeth of the

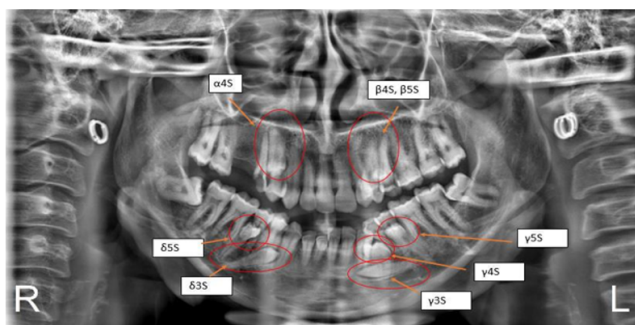


Fig. 2: OPG of supernumerary teeth according to notation.

group to which it belongs, i.e., molars, premolars, or incisors, or it may bear little or no resemblance.¹⁷ The prevalence rates of supernumerary premolars are variedly reported in different studies due to the differences in the respective populations, age, ethnicity, and applied radiographic techniques.¹⁸ Supernumerary teeth are single teeth in 76-86% of cases, while two supernumerary teeth are found in 12-23% of cases and three or more such teeth in the same individual are only found in 2-8% of cases. However according to Rajab and Hamdan this percentage is less than 1% when hyperdontia comprises 5 or more supernumerary teeth.¹⁹ Whenever a supernumerary tooth is diagnosed, the long term possibility of the progressive and delayed appearance of further supernumeraries should be taken into consideration.²⁰ However, Similarly this case has an unusual presentation of hyperdontia with 8 supernumerary teeth of which 3 are erupted and 5 unerupted. Occurrences of non-syndromic supernumerary teeth has often been observed in the maxilla than in mandible, also more in male than in female, in permanent dentition than in primary dentition, and unilaterally than bilaterally.² Supernumerary teeth are classified based on morphology as accessory and supplemental and based on syndrome as syndrome associated and non-syndrome associated.

Aetiology of supernumerary teeth is not well known. The higher prevalence of these anomalies among first-degree relatives in individuals affected as compared to general population suggests a significant genetic component in their development.²¹ Both genetic and environmental factors have been taken into consideration.

3.1. Few theories have been suggested to explain their occurrence

Although all theories are hypothetical because of the inability to obtain sufficient embryological material, most literature supports the dental lamina hyperactivity theory.¹² The presence of supernumerary teeth can produce certain complications such as eruption disturbances, dilaceration and resorption of roots of adjacent teeth, various malocclusions like rotation, axial inclination etc. A deviated

	It was originally suggested that supernumerary teeth were a consequence of phylogenetic reversion to extinct primates with three pairs of incisors
Atavism	This theory has been largely discarded ¹²
ichotomy	This stated that the tooth bud splits into two equal or different-sized parts,
Ttheory	Resulting in the formation of two teeth of equal size, one normal and other
	Dysmorphic tooth, respectively. However, this theory has been discarded. ¹²
Dental	This theory involves localized, independent and conditioned hyperactivity of the dental lamina. According to this theory a supplemental form would develop from the lingual extension of an accessory tooth bud.
Hyperactivity	Whereas a rudimentary form would develop from the proliferation.
Theory	of epithelial remnants of the dental lamina. ¹²

path of eruption may show supernumerary teeth erupting in abnormal locations like nasal cavity, orbit, inferior border of the mandible etc, sometimes weakening the bone structure to form a more prone site for fracture.²²

Supernumerary premolars are usually asymptomatic and most cases are diagnosed by chance during inspection of the intra oral radiographs. Bodin et al. Have reported that only 2% of the supernumerary premolars are likely to undergo any pathological changes. Nevertheless, the most commonly encountered complications with them are dentigerous cyst and root resorption of the adjacent tooth.¹ However in this case the supernumerary teeth did not show any pathological changes.

Supernumerary teeth are usually not symptomatic and most cases are seen as an incidental finding during a dental visit. Usually if the teeth are asymptomatic, it can be left in place as such and kept under observation. Surgical removal is to be considered based on the pathological sequelae that might be associated with it.¹⁸ If supernumerary teeth are associated with complications, it is a usual practice to extract them, which usually involves a surgical procedure. Early extraction of supernumeraries, causing incisor impaction, may have the benefit of minimizing loss of eruptive potential, space loss and centre line displacement. Even in cases where the unerupted incisors are severely rotated, early removal of the causative supernumerary tooth can result in self-correction and correction of alignment also.¹²

Occasionally, supernumerary teeth may lead to complications like deep dental caries in adjacent teeth which may require restoration or endodontic therapy of the adjacent teeth Removal is recommended where:²³

1. There is pathology associated
2. Permanent tooth eruption delayed
3. Inaccessibility to oral hygiene leading to increased risk of caries
4. Altered eruption or adjacent tooth displacement
5. If they are severely rotated causing further complication
6. If orthodontic treatment has to be done for alignment
7. If its placement compromises the alveolar bone integrity, grafting and implant placement.
8. In case of compromised esthetic and functional status of adjacent and involved tooth.

In general, the extraction of supernumerary premolars is the recommended treatment of choice but the time of their surgical removal is said to be controversial. If supernumerary teeth are close to the inferior alveolar nerve, increasing the risk of surgery, the teeth should be left in situ and have to be monitored clinically and radiographically. When dealing with the unerupted supernumerary teeth, we need to understand that each case must be thoroughly planned with a multidisciplinary team (including Paediatric Dentist, Orthodontist and Oral Surgeon) and the decision should be made whether to go for extraction or to wait and watch. Evaluative monitoring should be done from this interdisciplinary point of view.²⁰

4. Conclusion

The prevalence of supernumerary teeth in the premolar region has been demonstrated to be between 0.01 to 1 percent depending on the population in which it is studied. Interestingly, populations from the East or Africa are known to be the most affected. Furthermore, it has been suggested that supernumerary premolar teeth belong to a third (post-permanent) series, developing from extensions of the dental lamina.²⁴ Hence it is imperative to evaluate the patient clinically and radiologically when a single supernumerary is detected to rule out its association with syndromes and for its appropriate as well as timely management. Also, it is important on our part to educate the patient about the complications which can arise when the patient is reluctant with regard to its therapy.¹⁸

5. Source of Funding

None.

6. Conflict of Interest

None.

References

1. Aya G, Yapici G, Ömezli MM, Dayi E. Non-syndromic supernumerary premolars. *Med Oral Patol Oral Cir Bucal*. 2011;16(4):2–5.

2. Mali S, Karjodkar FR, Sontakke S, Sansare K. Supernumerary teeth in non-syndromic patients. *Imaging Sci Dent*. 2012;42(1):41–6.
3. Niswander JD, Sujaku C. Congenital anomalies of teeth in the Japanese children. *Am J Phys Anthropol*. 1963;21(4):569–74. doi:10.1002/ajpa.1330210413.
4. Davis PJ. Hypodontia and hyperdontia of permanent teeth in Hong Kong schoolchildren. *Commun Dent Oral Epidemiol*. 1987;15(4):218–20.
5. Koch H, Schwartz O, Klausen B. Indications for surgical removal of supernumerary teeth in the premaxilla. *Int J Oral Maxillofac Surg*. 1986;15(3):273–81.
6. Primosch RE. Anterior supernumerary teeth-assessment and surgical intervention in children. *Pediatr Dent*. 1981;3(2):204–19.
7. Rajab LD, Hamdan MA. Supernumerary teeth: Review of the literature and a survey of 152 cases. *Int J Paediatr Dent*. 2002;12(4):244–54.
8. Mitchell L. Supernumerary teeth. *Dent Update*. 1989;16(2):65–74.
9. Luten JR. The prevalence of supernumerary teeth in primary and mixed dentitions. *J Dent Child*. 1967;34(5):346–53.
10. So LL. Unusual supernumerary teeth. *Angle Orthod*. 1990;60(4):289–92.
11. Hall A, Onn A. The development of supernumerary teeth in the mandible in cases with a history of supernumeraries in the premaxillary region. *J Orthod*. 2006;33(4):250–5.
12. Shah A, Gill DS, Tredwin C, Naini FB. Diagnosis and management of supernumerary teeth. *Dent Update*. 2008;35(8):510–2.
13. Garvey MT, Barry HJ, Blake M. Supernumerary teeth - an overview of classification, diagnosis, and management. *J Can Dent Assoc*. 1999;65(11):612–8.
14. Mossaz J, Suter V, Katsaros C, Bornstein MM. Supernumerary teeth in the maxilla and mandible-an interdisciplinary challenge. *Swiss Dent J*. 2016;126(2):131–49.
15. Kalra N, Chaudhary S, Sanghi S. Non-syndrome multiple supplemental supernumerary teeth. *J Indian Soc Pedod Prev Dent*. 2005;23(1):46–54.
16. Yadav SS, Sonkurla S. Sarjeev's supernumerary tooth notation system: a universally compatible add-on to the Two-Digit system. *Indian J Dent Res*. 2013;24(3):395–401.
17. Panda S, Satish V, Maganur P, Ahmed A. Multiple Bilateral Unerupted Supplemental Premolars: An Unusual Presentation in a Nonsyndromic Patient. *Int J Clin Pediatr Dent*. 2017;10(2):217–22.
18. Ramakrishna A, Rajashekarappa KB. Multiple Supplemental Supernumerary Premolars: Unusual Presentation in a Nonsyndrome Patient. *Case Rep Dent*. 2013;1(1):614807. doi:10.1155/2013/614807.
19. Raj SC, Rath HM, Mishra J, Barik AK. Multiple hyperdontia: Report of an unusual case. *Am J Orthod Dentofac Orthop*. 2018;140(4):580–4.
20. Nirmala S, Chilamakuri S, Challa RR, Gokhale N. Recurrent mandibular supplemental premolars: A case report with 5 year follow up and review of literature. *J Clin Diagnostic Res*. 2015;9(2):4–6. doi:10.7860/JCDR/2015/10259.5518.
21. Cho SY. Supernumerary premolars associated with dens evaginatus: report of 2 cases. *J Can Dent Assoc*. 2005;71(6):390–3.
22. Revathy V, Bharath K. Multiple supplemental premolars in a nonsyndromic patient - a case report. *Research*. 2014;1:2–4. doi:10.13070/rs.en.1.832.
23. Garvey MT, Barry HJ, Blake M. Supernumerary teeth -an overview of classification, diagnosis and management. *J Can Dent Assoc*. 1999;65(11):612–8.
24. Khalaf K, Shehadat A, Murray S. A Review of Supernumerary Teeth in the Premolar Region. *Int J Dent*. 2018;p. 6289047. doi:10.1155/2018/6289047.

Author biography

Sumalatha CH, Reader

Srikanth T, Lecturer

Sankeerti Mala B, Assistant Professor

Srikanth E, Reader

Gowtham P, Consultant Pedodontist

Cite this article: Sumalatha CH, Srikanth T, Sankeerti Mala B, Srikanth E, Gowtham P. A case report of multiple supernumerary teeth: Post-permanent dentition or hyperactivity of dental lamina. *IP Int J Maxillofac Imaging* 2022;8(4):145-149.