

Comparative Evaluation of Horizontal Magnification on Digital and Conventional Panoramic Images

Patil Prashant B^{1,*}, S Anusuya G.²

¹Professor and Head, ²Post Graduate Student, Dept. of Oral Medicine and Radiology, Navodaya Dental College and Hospital, Raichur, Karnataka – 584101

*Corresponding Author

E-mail: prashantomdr@gmail.com

Abstract

Aim: The aim of the study was to assess horizontal magnification on digital and panoramic radiographs and compare the magnification factor between the two.

Materials and Methods: 30 digital and 30 conventional panoramic radiographs of 30 healthy adults were taken. Impressions were made of all the patients and casts were poured. With the calipers maximum mesiodistal width of labial/buccal surface of teeth were measured and horizontal magnification was calculated for incisor, premolar and molar teeth.

Statistical analysis: ANOVA test followed by post hoc Tukey Multiple comparison test T were used. Data was analyzed using SPSS software 16.0 V

Results: It was observed that in comparison to the measurement on the casts the digital and conventional panoramic radiographs showed significant difference of mean magnification of horizontal dimensions ($p < 0.001$) except for maxillary anteriors in digital images ($p > 0.05$). Further compared to digital imaging conventional images showed significant difference of mean horizontal magnification ($p < 0.0001$). The panoramic radiographs showed significant higher magnification index than listed by the manufacturer for both panoramic machines.

Conclusion: We conclude that both digital and conventional panoramic images show horizontal magnification, further the horizontal magnification of conventional images is significantly higher than their digital counterparts. Hence horizontal panoramic measurements are unreliable.

Key words: Conventional, Digital, Dimensional accuracy, Horizontal magnification, Panoramic radiographs.

Introduction

Panoramic imaging (pantomography) is a technique for producing single topographic image of the facial structures that includes both maxillary and mandibular dental arches and their supporting structures¹. It is a useful adjunct to various extra oral radiographs². It is based on principle of reciprocal movement of X-ray source and image receptor around a central plane called image layer¹.

Panoramic radiographs are used for dimensional assessments of bone, implant location, determine relative angulations of teeth, mesiodistal tooth angulations, to know relative positions of roots and abutments, third molar locations, temporomandibular joint examination and to assess bony pathologies of jaws.³.

Its advantages include broad coverage of facial bone and teeth, along with surrounding structures, low radiation dose, convenient, easy, takes short time and can be used in patients unable to open mouth. While the limitations are that it cannot display the fine anatomical details seen on intraoral radiographs, overlapping of structures (such as cervical spine in anterior region)¹. One of the greatest problems associated with panoramic images include unequal magnification which may obscure useful information and compromise diagnosis⁴.

The magnification and distortion occurs when the patient's jaws are not positioned within the focal

trough of the machine⁵. In panoramic radiography the vertical dimensions of the image does not significantly change since in vertical projections x-ray source serves as the focus (similar to conventional intraoral projection) whereas; in horizontal dimension rotation centre of the beam is the functional focus⁶ and hence magnification in horizontal projections are seen. Even when properly taken, dental panoramic radiography images are associated with enlargement of the actual object size by about 15–25%, and distortion occurs when horizontal magnification differs from vertical magnification with poor patient positioning⁵.

Razi et al. in their study concluded that vertical and horizontal dimensions in panoramic radiography are unreliable and it should be used for evaluation of angular measurements only⁷. Arora et al in their study concluded that vertical measurements and anterior horizontal and oblique measurements showed minimal magnification and posterior horizontal and oblique measurements showed increased magnification⁸. Various studies have been done to measure horizontal dimensions on panoramic radiographs (either digital or conventional) but none of the studies have compared the magnification factors between both the variants. Hence the aim of the present study was to assess the horizontal magnification rate on digital panoramic images and conventional (analogue) images. The objective of the study was to compare the horizontal magnification on digital panoramic images

with conventional (analogue) images and to assess whether the measurements are reliable.

Material and Methods

The study was conducted in Department of Oral Medicine & Radiology, Navodaya Dental College and hospital, Raichur, Karnataka, during May and June 2014. The sample for the study were patients reporting to department for pre-surgical and preorthodontic evaluation, whose treatment required pantomograph. Sample size was 30. The inclusion criteria were patients with complete permanent dentition (with or without third molars) and patients with Angle's Class I malocclusion. The exclusion criteria were patients with Angle's Class II and III molar relation, patients with crowding of teeth, patients with jaw deformities and bony disease or any other systemic disease.

Procedure:

A standard Performa was used to record the details of the patient. Patient was explained about the study and informed consent was taken from the patient who agreed to take part in the study. Ethical clearance was obtained from the institution ethical committee. The analogue pantomograph (STRATO 2000, VILLA SYSTEMI MEDICALI, Buccinasco, Italia) was used to capture analogue images of patients following manufacturer's instructions for precise patient positioning. The analogue pantomographs were taken using Konica KR II screen and T-Mat film (Eastman Kodak Company, Rochester, NY) and films were developed by manual processing (Image 1). Digital pantomograph (ORTHOPHOS 5 XG-Sirona dental systems, Germany) was used to capture digital images and images were printed using (Image 2). The exposure parameters used for digital imaging were 14-0 sec, 68kV, 8mA and for analogue were 15 sec, 74kV and 10mA. Alginate impressions (Tropicalgin, Zhermack clinical, New Delhi, India) of upper and lower arches were made using metal impression trays and inspected for voids. Impressions were then rinsed for few minutes for removal of residual saliva and poured with dental stone. After 24 hours casts were separated from impressions and trimmed.

Using calipers the maximum mesiodistal width (labial/buccal surface) of all the teeth except canine teeth were measured on casts (Image 3) as well as on radiographs. The values obtained were compared and analyzed by ANOVA test followed by post hoc Tukey-Kramer Multiple Comparisons Test t. A p-value less than 0.05 were considered as significant. Data analysis was done using software SPSS 16.0.

Results

In all cases, the maximum mesiodistal size on the radiographs was greater than the size measured on the cast, which means magnification was observed in all

specimens. Table 1 shows the comparison of magnification factors between digital and analogue images for anteriors using the mean, the standard deviation, and the 95% confidence intervals. Similarly, Tables 2 and 3 are for premolars and molars respectively.

Table 1: Comparison of horizontal measurement on digital panoramic images with conventional (analogue) images for anterior teeth (Mean ± SD)

	Casts (I)	Digital (II)	Conventional (III)	Tukey-Kramer Multiple Comparisons Test	Mean difference	95% CI	p-value
CI*							
Maxillary	9.7 ± 0.8	9.73 ± 1.08	11.7 ± 1.43	I vs II, p>0.05 I vs III, p<0.001 II vs III, p<0.001	0.03 2.0 1.97	-0.73 – 0.67 1.30 – 2.70 1.27 – 2.67	P<0.0001
Mandibular	8.5 ± 0.86	9.77 ± 1.82	10.92 ± 1.02	I vs II, p<0.001 I vs III, p<0.001 II vs III, p<0.01	1.27 2.42 1.15	0.46 – 2.07 1.61 – 3.22 0.34 – 1.95	P<0.0001
LI#							
Maxillary	8.77 ± 1.13	8.59 ± 0.85	10.08 ± 0.99	I vs II, p>0.05 I vs III, p<0.001 II vs III, p<0.001	0.18 1.32 1.49	-0.43 – 0.79 1.70 – 1.93 0.88 – 2.11	P<0.0001
Mandibular	8.58 ± 1.17	10.23 ± 1.79	11.10 ± 1.19	I vs II, p<0.001 I vs III, p<0.001 II vs III, p>0.05	1.65 2.52 0.87	0.77 – 2.52 1.64 – 3.39 -0.006 – 1.74	P<0.0001

Table 2: Comparison of horizontal measurement on digital panoramic images with conventional (analogue) images for Premolars (Mean ± SD)

Pre-Molars	Casts (I)	Digital (II)	Conventional (III)	Tukey-Kramer Multiple Comparisons Test	Mean difference	95% CI	p-value
PM1*							
Maxillary	8.77 ± 0.77	9.63 ± 0.83	11.43 ± 1.61	I vs II, p<0.05 I vs III, p<0.001 II vs III, p<0.001	0.87 2.67 1.80	0.16 – 1.57 1.96 – 3.37 1.09 – 2.50	P<0.0001
Mandibular	8.47 ± 0.86	9.77 ± 1.82	10.87 ± 1.05	I vs II, p<0.001 I vs III, p<0.001 II vs III, p<0.01	1.30 2.40 1.10	0.49 – 2.11 1.59 – 3.21 0.29 – 1.91	P<0.0001
PM2#							
Maxillary	8.47 ± 0.88	9.52 ± 0.9	10.92 ± 1.36	I vs II, p<0.001 I vs III, p<0.001 II vs III, p<0.001	1.06 2.45 1.39	0.39 – 1.72 1.78 – 3.11 0.73 – 2.06	P<0.0001
Mandibular	8.6 ± 1.15	10.23 ± 1.79	11.1 ± 1.19	I vs II, p<0.001 I vs III, p<0.001 II vs III, p>0.05	1.63 2.50 0.87	0.76 – 2.50 1.63 – 3.37 -0.002 – 1.74	P<0.0001

Table 3: Comparison of horizontal measurement on digital panoramic images with conventional (analogue) images for Molars (Mean ± SD)

	Casts (I)	Digital (II)	Conventional (III)	Tukey-Kramer Multiple Comparisons Test	Mean difference	95% CI	p-value
M1*							
Maxillary	11.18 ± 1.29	12.6 ± 1.84	14.28 ± 1.41	I vs II, p<0.01 I vs III, p<0.001 II vs III, p<0.001	1.42 3.10 1.68	0.47 – 2.36 2.15 – 4.05 0.74 – 2.63	P<0.0001
Mandibular	12.02 ± 1.25	13.27 ± 1.65	15.18 ± 1.6	I vs II, p<0.01 I vs III, p<0.001 II vs III, p<0.01	1.25 3.17 1.92	0.32 – 2.18 2.23 – 4.10 0.98 – 2.85	P<0.0001
M2#							
Maxillary	11.12 ± 1.11	12.32 ± 1.34	13.92 ± 1.57	I vs II, p<0.01 I vs III, p<0.001 II vs III, p<0.001	1.2 2.8 1.6	0.36 – 2.03 1.96 – 3.63 0.76 – 2.43	P<0.0001
Mandibular	10.9 ± 1.19	13.8 ± 1.72	14.55 ± 1.74	I vs II, p<0.001 I vs III, p<0.001 II vs III, p>0.05	2.90 3.65 0.76	1.93 – 3.87 2.68 – 4.62 0.22 – 1.72	P<0.0001

Inference: Table 1 and Fig. 1 and 2

Casts and Digital Images (I and II): For maxillary anteriors no statistically significant difference was found between measurements on casts and digital images ($p > 0.05$) whereas for mandibular anteriors the values were statistically significant ($p < 0.001$).

Digital and Conventional Images (II and III): Statistically significant difference of mean horizontal measurements were observed between maxillary and mandibular anteriors ($p < 0.01$) except for mandibular lateral incisor ($p > 0.05$)

Casts and Conventional Images (I and III): Statistically significant difference was seen for both maxillary and mandibular anteriors ($p < 0.001$)

Mean Difference of Magnification	
Casts and digital images	0.03-1.65
Digital and conventional images	0.87-1.97
Casts and conventional images	1.3-2.5

*Central incisor, # Lateral incisor

Inference: Table 2 and Fig. 3 and 4

Casts and Digital Images (I and II): Statistically significant difference of mean horizontal measurements were observed between maxillary and mandibular premolars ($p < 0.001$).

Digital and Conventional Images (II and III): Statistically significant difference of mean horizontal measurements were observed between maxillary and mandibular premolars ($p < 0.01$) except for mandibular second premolar ($p > 0.05$)

Casts and Conventional Images (I and III): Statistically significant difference was seen for both maxillary and mandibular premolars ($p < 0.001$)

Mean Difference of Magnification	
Casts and digital images	0.87-1.63
Digital and conventional images	0.87-1.80
Casts and conventional images	2.40-2.67

*Ist premolar, # IInd premolar

Inference- Table 3 and Fig. 5 and 6

Casts and Digital Images (I and II): Statistically significant difference of mean horizontal measurements were observed between maxillary and mandibular molars ($p < 0.01$).

Digital and Conventional Images (II and III): Statistically significant difference of mean horizontal measurements were observed between maxillary and mandibular molars ($p < 0.01$) except for mandibular second molar ($p > 0.05$)

Casts and Conventional Images (I and III): Statistically significant difference was seen for both maxillary and mandibular molars ($p < 0.001$)

Mean Difference of Magnification	
Casts and digital images	1.2-2.9
Digital and conventional images	0.76-1.9
Casts and conventional images	2.8-3.6

*Ist Molar, # IInd Molar

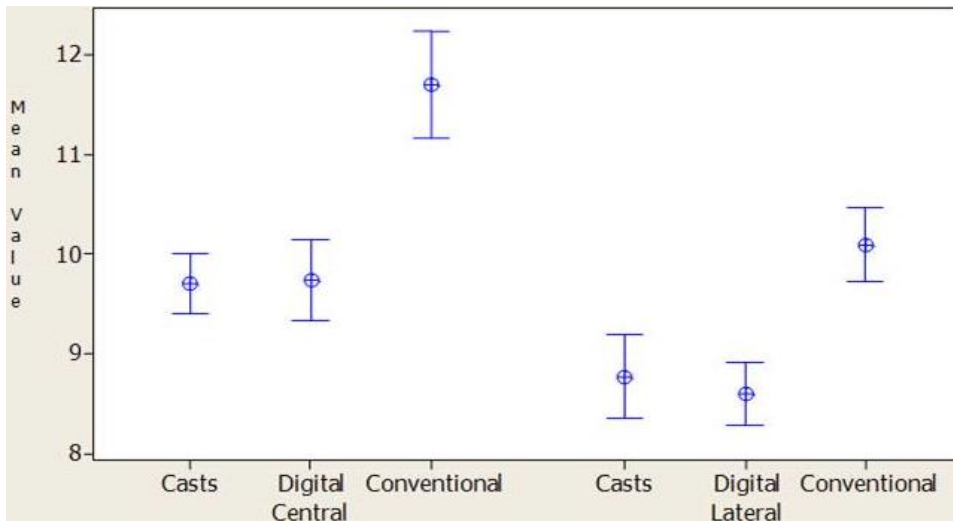


Fig. 1: Comparison of horizontal measurement between casts and radiographs for maxillary anteriors (95% CI for the mean)

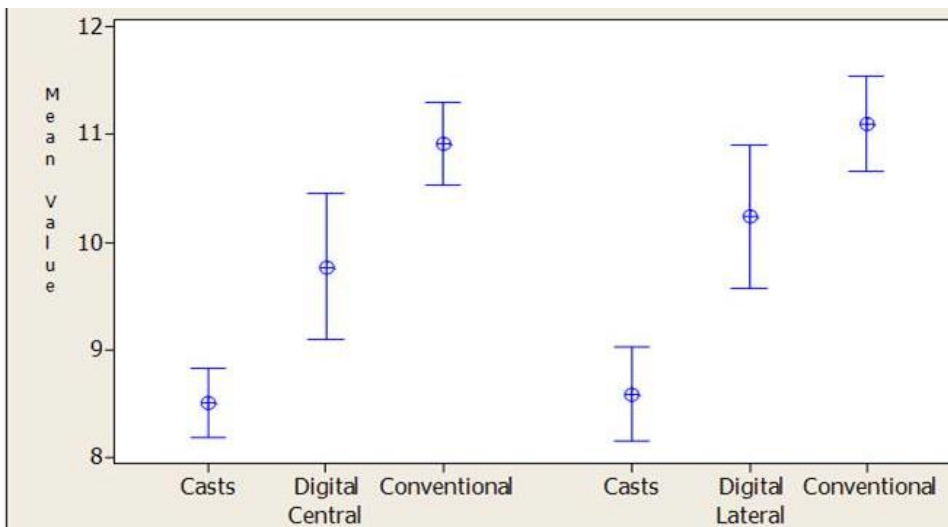


Fig. 2: Comparison of horizontal measurement between casts and radiographs for mandibular anteriors (95% CI for the mean)

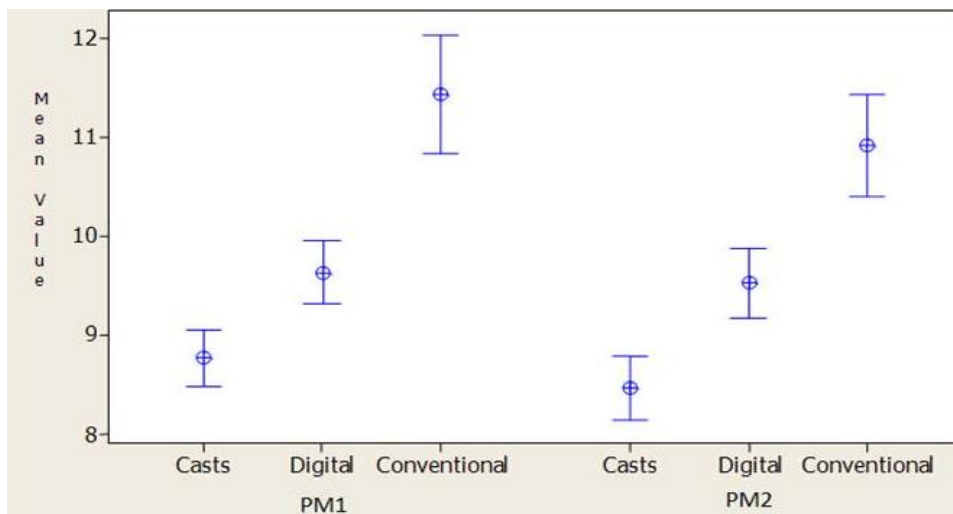


Fig. 3: Comparison of horizontal measurement between casts and radiographs for maxillary premolars (95% CI for the mean)

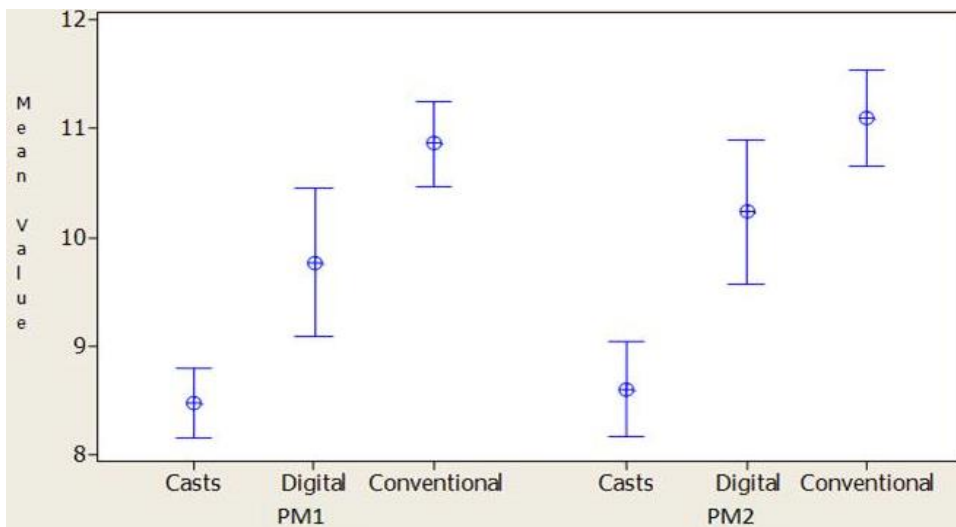


Fig. 4: Comparison of horizontal measurement between casts and radiographs for mandibular premolars (95% CI for the mean)

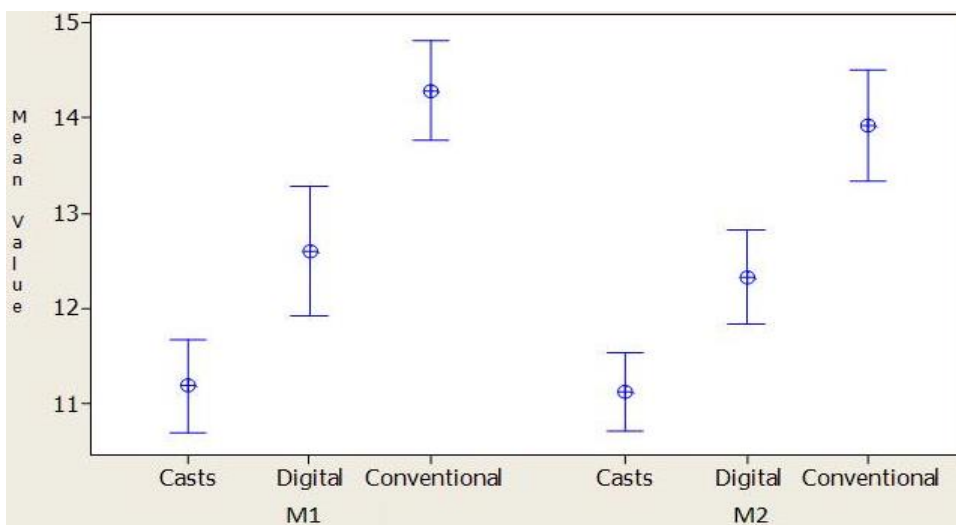


Fig. 5: Comparison of horizontal measurement between casts and radiographs for maxillary molars (95% CI for the mean)

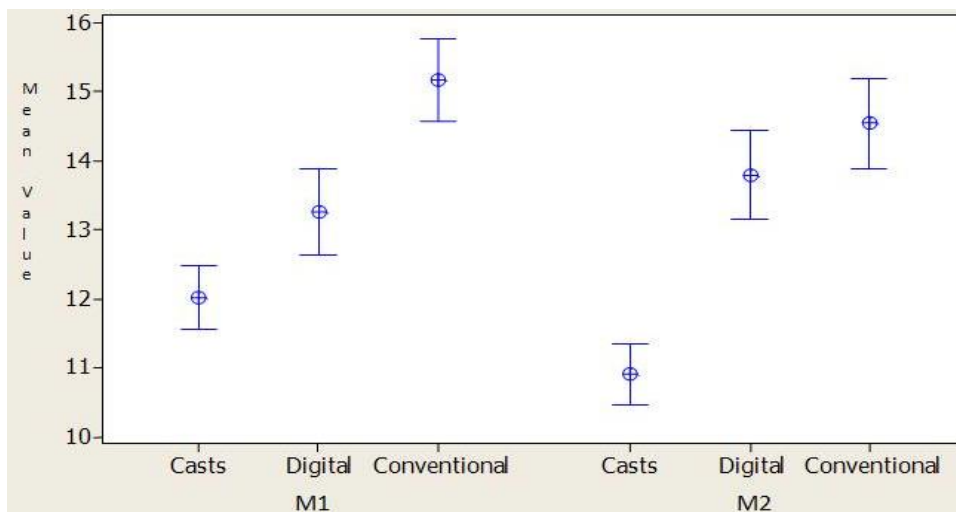


Fig. 6: Comparison of horizontal measurement between casts and radiographs for mandibular molars (95% CI for the mean)

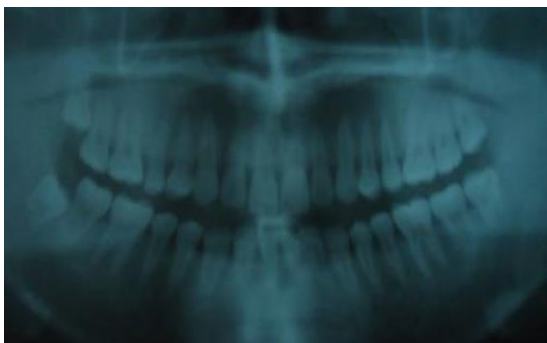

Image 1: Analogue pantomograph

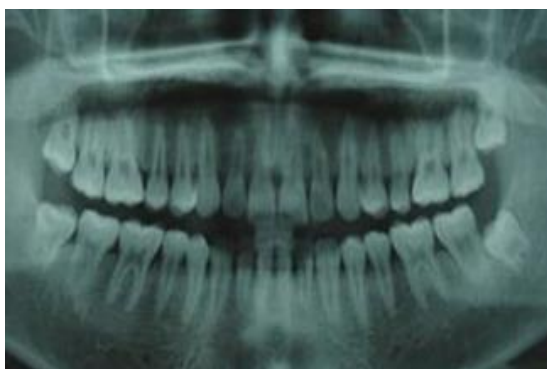


Image 2: Digital pantomograph

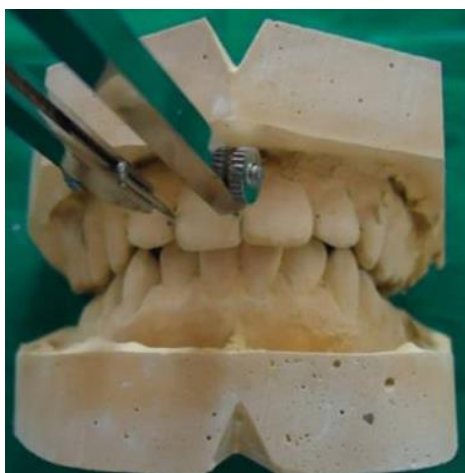

Image 3: Maxillary and mandibular casts

Discussion

Magnification is increase in the size of the image in the radiograph compared with actual size of the object¹ and it is considerable disadvantage of panoramic imaging. It is inherent phenomenon that can lead to erroneous treatment plans⁷. To the best of our knowledge this is the first study to compare the horizontal magnification factor between digital and conventional panoramic radiographs. All measurements were performed by a single observer. This eliminates inter-observer variation and measurement errors were, therefore, presumed to be consistent with the single examiner.

In our study significant magnification has been observed in analogue images as compared to digital images. The magnification factor listed for Orthophos 5 XG Sirona digital machine is 1.25 and for Strato 2000 conventional machine is 1: 1.23.

The present study showed varying amount of horizontal magnification indexes in both the machines. The range for digital imaging was 1.5 to 2.9 and for conventional imaging was 1.3 to 3.6.

Our study is in agreement with Vaishali et al who in their study have shown that the calculated indices for vertical, horizontal and oblique distances that crossed the midline were greatly enlarged than the manufacturer's magnification index². The results of this study are in contrast with that of Raouf et al which concludes that maxillary and mandibular incisor regions didn't show significant difference of the mean magnification of horizontal dimension⁴.

Significant magnification was observed in both anterior and posterior teeth in both digital and panoramic images which is in contrast to the findings by Arora et al. who concluded that vertical measurements and anterior horizontal and oblique measurements showed minimal magnification⁸. The results of this study are in accordance with that of Razie et al, who in their study concluded that vertical and horizontal dimensions in panoramic radiography are unreliable and it should be used for evaluation of angular measurements only⁷.

Canines are positioned in the angle of both jaws, so while tomographic movement the focal spot position varies on the canine region⁴. Hence canines shows significant distortion and were not included in the study. In this study, the average magnification was higher in the posterior part of the maxilla and mandible than in the anteriors.

Several studies have considered positioning errors as a significant factor that could influence radiographic magnification^{5,7,9}. Panoramic image formation depends on the spatial location of anatomical structures in the image layer. Ladeira et al in his study determined size, shape and position of the image layer by evaluation of the radiographic image formation in different anatomic positions. It was observed that in the middle portion of the image layer, differences in the image size were observed only along the horizontal axis, whereas no differences were observed along the vertical axis¹⁰.

It is essential to position the patient's head correctly in the machine^{6,9} which can often be difficult or impossible, because the object of interest must be located in the image layer within the middle portion, which is unchangeable. The lack of calibration to synchronize rotation speeds of the image receptor and x-ray beam of the machine can also promote image distortions due to a change in the position of the effective focus in the image layer¹⁰.

Conclusion

It is not possible to determine a specific magnifying factor for panoramic machines, as there are wide variations in magnification among the different anatomical regions, axes and planes, making it impossible to obtain reliable anatomical measurements, for any purpose, using panoramic radiographs. We conclude that both digital and conventional panoramic images show horizontal magnification, further the horizontal magnification of conventional images is significantly higher than their digital counterparts.

Thus the horizontal measurements on panoramic radiography are unreliable and its indication should not be overestimated.

Conflict of Interest: None

Source of Support: Nil

References

1. White S, Pharaoh MJ. Oral Radiology. Principles and interpretation. 5th ed. Elsevier, Mosby (2004);Pg:91,271.
2. MR Vaishali, KS Ganapathy, K Srinivas. Evaluation of precision of dimensional measurements of the mandible on panoramic radiographs. JIAOMR (2011);23(3):323-27.
3. Mckee IW, Glover KE, Williamson C Petal. The Effect of Vertical and Horizontal Head Positioning in Panoramic Radiography on Mesiodistal Tooth Angulations. Angle Orthod. (2001);71(6):442-51.
4. Raof M, Haghani J, Ebrahimi M. Evaluation of horizontal magnification on panoramic images. Indian J Dent Res 2013;24:294-7.
5. Yuan J, Devlin H. Object position and image magnification in dental panoramic radiography: a theoretical analysis. Dentomaxillofac Radiol 2013; 42:20120045.
6. Langland Olaf E, Langlais Rober P, Doss Mc David W, Delbalso Angelo M. Panoramic radiology (2 ed). Philala-delphia: WB Saunders Company 1989.
7. Razi T, Moslemzade SH, Razi S. Comparison of linear dimensions and angular measurements on panoramic images taken with two machines. J Dent Res Dent Clin Dent Prospect 2009;3:7-10.
8. Arora H, Jain V, Pai KM, Kamboj R. Precision of dimensional measurements of mandible in different positions on orthopantomogram. Indian J Dent Res 2013;24:48-51.
9. Park JB. The evaluation of digital panoramic radiographs taken for implant dentistry in the daily practice. Med Oral Patol Oral Cir Bucal. 2010 Jul 1;15(4):e663-6.
10. DBS Ladeira, AD Cruz, SM Almeida, FN Boscolo. Evaluation of the Panoramic Image Formation in Different Anatomic Positions. Braz Dent J (2010);21(5): 458-462.