

## Hemimandibular Hyperplasia: A Case Report

Asmita Nandre<sup>1</sup>, Prashant Patil<sup>2,\*</sup>

<sup>1</sup>Post Graduate Student, <sup>2</sup>Professor & Head, Dept. of Oral Medicine and Radiology,  
Navodaya Dental College and Hospital, Raichur, Karnataka

**\*Corresponding Author**

E-mail: prashantomdr@gmail.com

### Abstract

An asymmetric variation of facial structures is commonly seen in the general population. Hemimandibular hyperplasia is a gross asymmetry of facial structures characterized by unilateral enlargement of hard and soft tissues. The etiology of Hemimandibular hyperplasia remains unknown, however abnormalities involving the hormones, neural system, vascular, lymphatic & mechanical influences have been proposed. The condition does not warrant any active intervention except for cosmetic reasons.

A case of 22 year old male showing characteristic features of hemimandibular hyperplasia is reported with an insight on differential diagnosis. The case is presented to supplement existing clinical knowledge.

**Keywords:** Hemimandibular hyperplasia, Facial asymmetry

### Introduction

Facial asymmetry, characterized as correspondence in the size, shape, or relationship of two sides of the face, has high correlation with facial harmony, attractiveness, and beauty.<sup>(1,2)</sup> It was first noticed by the early Greek artists & the term normal facial asymmetry was used. The word symmetry is derived from the Greek word symmetria which means 'of like measure'. Later, Leonardo da Vinci and Albrecht Durer described the classic concept of human facial symmetry and found absolute bilateral symmetry a normal morphologic characteristic.<sup>(3)</sup>

The etiologic factors that cause facial asymmetries and their underlying mechanisms are not yet completely understood.<sup>(1,3)</sup> It is appropriate to classify facial asymmetries into the two basic categories of developmental & acquired asymmetries. Developmental asymmetries include agenesis, hypoplasia, hyperplasia, atrophy, hypertrophy, and malposition of the facial bony structures. Acquired asymmetries occur as a result of traumas, infections, functional shifts, and tumors.<sup>(3)</sup> Affected patients usually report late in the course of the disease due to slow progressive nature of the problem.

### Case Report

A 22 year old male reported to the department of Oral Medicine and Radiology, Navodaya Dental College, Raichur with a chief complaint of deviation of chin towards left side since 2-3 years. The patient noticed the deviation of chin starting at the age of 18 years and was progressive in nature. There was no history of trauma, pain, paresthesia on the affected side.

Clinical examination revealed facial asymmetry, deviation of chin to the left side, increase in vertical height of the middle and lower thirds of face on the right side. Mouth opening was normal with deviation towards left side (Fig. 1 & Fig. 2). TMJ movements

were bilaterally synchronous, no clicking on opening or closing was noticed but tenderness was present on right side of TMJ. Excursion and protrusive movements were not restricted. Dental occlusion was class 1 malocclusion with anterior cross bite. Midline shift was noticed towards left side (Fig. 3). Full complements of teeth were present. No asymmetry of arch form was noted. Mandibular occlusal radiograph showed increase in width of bone on right side (Fig. 4).

A panoramic radiograph revealed a discrepancy in size and morphology between the right and left condyles, enlargement of the right condyle and elongation of the right ascending ramus as well as an enlargement of the skeletal base of the right hemi mandible in all its dimensions. The gonial angle was characteristically rounded off and the mandibular canal was displaced towards the lower border of the mandible (Fig. 5).

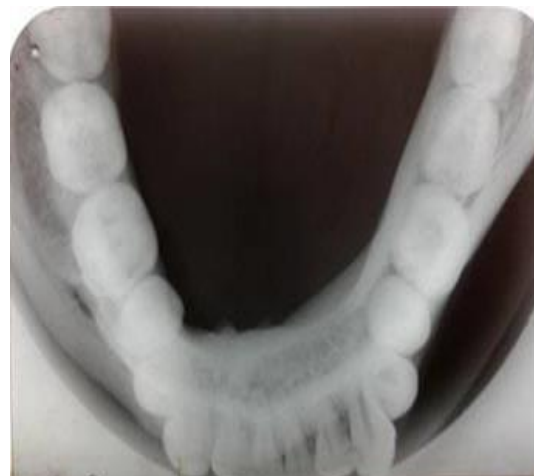A PA skull radiograph revealed deviation of mandible towards left side with facial asymmetry (Fig. 6). TMJ open & close view showed, enlargement of the right condyle.

CT scan revealed hyperplasia of body, condyle, angle and ramus of mandible on the right side and atrophy of the muscles of the masticator space on the right side with fatty proliferation noted in the soft tissue (Fig. 7 & 8).

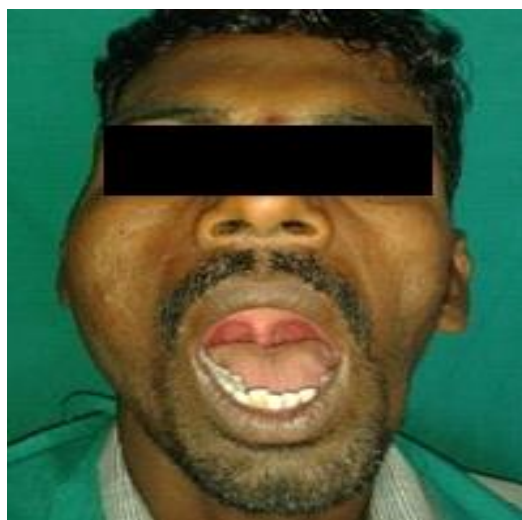On the basis of these clinical and radiological findings, the patient was diagnosed of having hemimandibular hyperplasia.



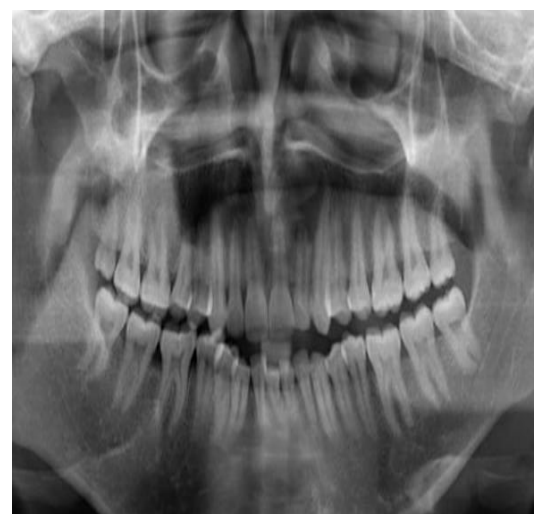**Fig. 1: Gross facial asymmetry**



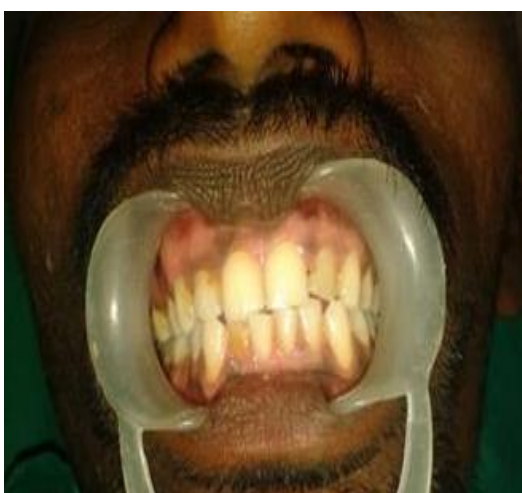**Fig. 4: Occlusal radiograph showing enlargement of right side of body of mandible**



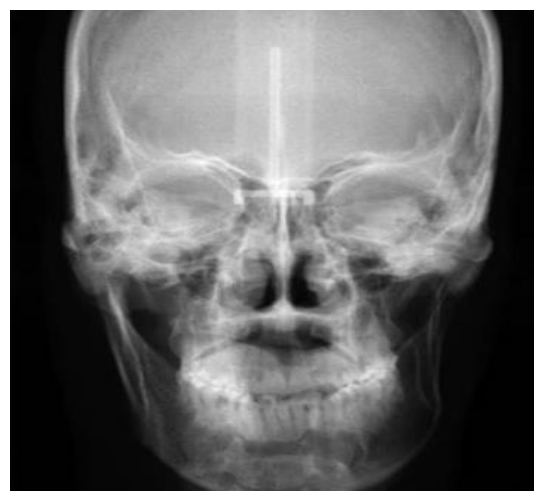**Fig. 2: Deviation of mandible towards left side**



**Fig. 5: OPG enlargement of the right condyle and elongation of the right ascending ramus as well as increase in width of ramus of mandible**



**Fig. 3: Anterior Cross bite with midline shift**



**Fig. 6: PA skull radiograph showing deviation of mandible towards left side with facial asymmetry**

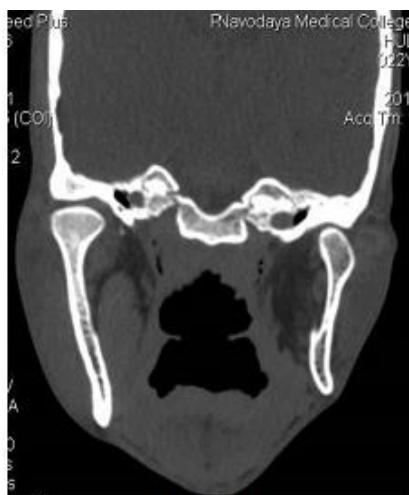


Fig. 7(a)

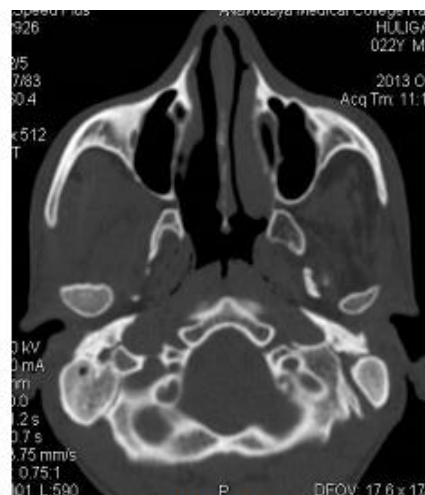

Fig. 7(b)

**Fig. 7: CT scan (Coronal and axial sections) showing hyperplasia of body, condyle, angle and ramus of mandible on the right side and atrophy of the muscles of the masticator space on the right side**

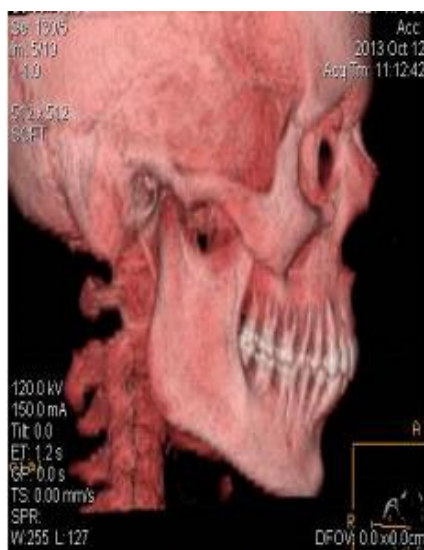

Fig. 8(a)

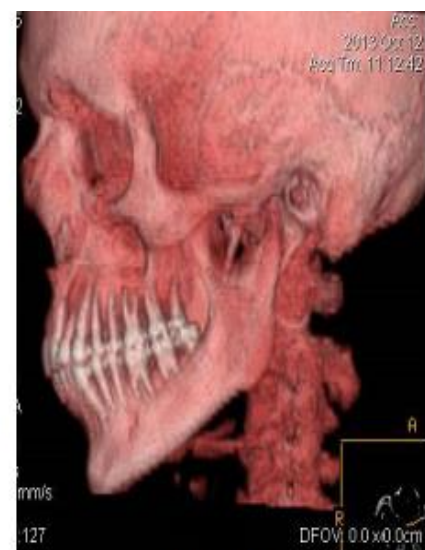

Fig. 8(b)

**Fig. 8: 3D reconstructed images - revealed hyperplasia of body, condyle, angle and ramus of mandible, zygomatic bone on the right side compared to left side of mandible and increase in vertical height of right side of body & ramus of mandible**

## Discussion

Hemimandibular hyperplasia was clearly described by Obwegeser and Makein 1986.<sup>(4)</sup> Hemimandibular hyperplasia is a rare malformation of non-neoplastic origin characterized by a three dimensional enlargement of one side of mandible i.e. the enlargement of one side of the condyle, the condylar neck and the ascending & horizontal rami. The anomaly terminates exactly at the symphysis of the affected side & for this reason it is called hemimandibular hyperplasia<sup>(4)</sup>. Clinically this malformation is characterized by facial asymmetry & shifting of the midline of the chin to the unaffected side.<sup>(5)</sup> The unilateral asymmetric increase in facial height gives right to a sloping rim oris, but the mouth

can be opened without restriction. In the present case all these features were present including enlargement of right side of zygomatic bone which was an additional observation.

The etiology of HH is still debatable. Genetic factors, circulatory problems, hormonal disturbances, traumatic lesions, and arthrosis have been proposed to be etiologic factors of the disease.<sup>(6)</sup> The epidemiological data have suggested that there are similar incidences in both sexes and in all ethnic groups.<sup>(7,8)</sup>

Hemimandibular hyperplasia was clearly described by Obwegeser & Makek and must be distinguished from solitary & exclusive hyperplasia of condyle. In condylar hyperplasia, radiographically the

condyle is homogeneously enlarged, but the horizontal ramus is not increased in height & mandibular canal is not displaced and clinically the facial appearance is distorted with an increase in the height of the affected side. An open bite and cross bite might be present on the affected side. Normally the dental midline is deviated toward the unaffected side but may also be centered, depending on the vector and speed of growth.

Hemimandibular elongation was first described by Obwegeser and Makek and is a developmental deformity of unknown etiology affecting the mandible unilaterally. It commonly presents with a progressively increasing transverse displacement of the chin point in young adulthood.

Obwegeser and Makek<sup>(4)</sup> stated that abnormal condylar growth regulates the abnormal growth of the mandibular body in both hemimandibular hyperplasia and unilateral condylar hyperplasia. However, in the patient described above, the situation differs significantly from patients with both classical hemimandibular hyperplasia and condylar hyperplasia. The patient presented with no elongation of either the condyle or the condylar neck, however the condyle showed enlargement. The alveolar bone around the mandibular right first and second molars were enlarged and enlargement of right side body, condyle, angle and ramus of mandible with the involvement of zygomatic bone was noticed.

Rowe<sup>(9)</sup> described the criteria for true hemihypertrophy. According to him hemifacial hypertrophy is an unusual condition which produces facial asymmetry by a marked unilateral localized

overgrowth of all the tissues in the affected area. i.e. facial soft tissues, bone and teeth. Hemihypertrophy can be localized enlargement of the mandible with accelerated dental development but in the present case teeth were not affected.

In 2001 Golnaz et al reported a case of hemimandibular hyperplasia in female patient with marked facial asymmetry due to increased right ramus and mandibular width & height without deviation of mandible & bilaterally symmetrical condyles.<sup>(11)</sup> However in the present case condyles were asymmetrical with the involvement of zygomatic bone.

In 2007 Burcak et al treated case of hemimandibular hyperplasia in 27 year old female patient & observed transverse deviation of occlusal plane which canted down on the affected side (skeletal class III occlusion) which was not observed in our case.<sup>(12)</sup> The Differential diagnosis for facial asymmetry can be varied including condylar hyperplasia, Facial hemiatrophy, Facial hemihypertrophy, Fibrous dysplasia as discussed in (Table 1).

**Table 1: Differential Diagnosis**

Condition	Features
Condylar hyperplasia	Horizontal ramus is not increased in height & mandibular canal is not displaced. Clinically the facial appearance is distorted with an increase in the height of the affected side. An open bite and cross bite might be present on the affected side.
Facial hemiatrophy	Most common early sign- coup de sabre, accompanied by pigmentation disorder, neurological disorder such as contralateral jacksonian epilepsy, trigeminal neuralgia & ocular complications. Female predominance
Facial hemihypertrophy	Enlargement confined to one side of the body, unilateral macroglossia, premature development & eruption as well as increased size of dentition.
Hemimandibular hyperplasia	Unilateral horizontal enlargement of Mandible. Normal alveolar bone height above inferior alveolar canal of affected side
Fibrous dysplasia	Initial symptoms are most often present during childhood or adolescence, as bone pain and repeated fractures. The other usual clinical findings are bone deformity and neurological compression, especially when the facial bones or the skull are involved. Radiograph shows ground glass appearance

The correction of facial asymmetry in hemimandibular hyperplasia is purely cosmetic.

The treatment protocol for hemimandibular hyperplasia was advocated by Wolford<sup>(13)</sup> which includes

1. Perform low condylectomy;
2. Reshape the condylar neck;
3. Perform orthognathic surgery;
4. Perform an inferior border ostectomy

### Conclusion

Facial asymmetry due to hemimandibular hyperplasia can pose diagnostic dilemma, however with detailed history and clinical examination accompanied by through radiographic evaluation the true nature of the condition can be unearthed. Since the condition is benign & slowly progressive reassurance is all that may be required in most cases unless a gross symmetry causing cosmetic problem warranting a surgical correction.

**Conflict of Interest: None**

**Source of Support: Nil**

### References

1. Waite PD, Urban SD. Management of facial asymmetry. In: Miloro M, Ghali GE, Larsen PE, Waite PD, eds. Peterson's Principles of Oral and Maxillofacial Surgery. 2nd ed. London, UK, and Hamilton, Ontario, Canada: BC Decker Inc; 2004:1205–1219.
2. Bishara SE, Burkey PS, Kharouf JG. Dental and facial asymmetry: a review. Angle Orthod. 1994; 64:89–98.
3. Melnik AK. A cephalometric study of mandibular asymmetry in a longitudinally followed sample of growing children. AmJ Orthod Dentofacial Orthop. 1992; 101:355–366.
4. Obwegeser HL, Makek MS. Hemimandibular hyperplasia: hemimandibular elongation. J Maxillofac Surg. 1986; 14:183–208.
5. De Bont LGM, Blankestijn J, panders AK, Vermey A. unilateral condylar hyperplasia combined with synovial chondromatosis of the temporomandibular joint report of a case. J maxillofac surg 1985;13:32-36.
6. Norman JE, Painter DM .Hyperplasia of the mandibular condyle. A historical review of important early cases with a presentation & analysis of twelve patients. J Mxillofac surg 1980;8:161-175.
7. Gray RJ, Sloan P, Quayle AA, Carter DH. Histopathological and scintigraphic features of condylar hyperplasia. Int J Oral Maxillofac Surg 1990; 19:65–71.
8. Matteson SR, Proffit WR, Terry BC, Staab EV, Burkes Jr ET. Bone scanning with 99m technetium phosphate to assess condylar hyperplasia. Report of two cases. Oral Surg Oral Med Oral Pathol 1985; 60:356–67.
9. Rowe NH. Hemifacial hypertrophy: review of literature and addition of four cases. Oral surg oral med oral path 1962; 15:572-87.
10. Gorlin RJ, Meskin LH. Congenital hemihypertrophy Journal of paediatrics 1962; 61:870-879.
11. Golnaz K, Henry J. Idiopathic non-condylar hemimandibular hyperplasia international journal of paediatric dentistry 2001; 11:298-303.
12. Burcak K, Ayc a Arman, Sina Uc kan, Orthodontic and Surgical Treatment of Hemimandibular Hyperplasia. Angle Orthodontist,2007;77(3).
13. Wolford LM. Facial Asymmetry; diagnosis and treatment consideration. 2 ed. 2009.