

Content available at: <https://www.ipinnovative.com/open-access-journals>

IP International Journal of Maxillofacial Imaging

Journal homepage: <https://www.ijmi.in/>

## Case Report

# Inflammatory fibrous hyperplasia – A case report

Jaspreet Kaur<sup>1,\*</sup>, Deepak Bala<sup>1</sup>, Akshita Singh Thakur<sup>2</sup>, Sarvani Chandel<sup>1</sup>,  
Viniti Goel<sup>1</sup>

<sup>1</sup>Dept. of Periodontology and Oral Implantology, Bhojia Dental College and Hospital, Baddi, Himachal Pradesh, India

<sup>2</sup>Dept. of Oral Pathology, Bhojia Dental College and Hospital, Baddi, Himachal Pradesh, India



### ARTICLE INFO

#### Article history:

Received 15-02-2023

Accepted 22-03-2023

Available online 18-04-2023

#### Keywords:

Hyperplasia

Pyogenic granuloma

Inflammatory cells

Edema

Histopathology

### ABSTRACT

Gingival enlargement, the currently accepted terminology for an increase in the size of the gingiva, is a common feature of gingival disease. Local and systemic factors influence the gingival conditions of the patient. These factors result in a spectrum of diseases that can be developmental, reactive and inflammatory to neoplastic. In this case report, the history, etiology, clinical features, treatment strategies and preventive protocol of inflammatory hyperplasia are discussed.

This is an Open Access (OA) journal, and articles are distributed under the terms of the [Creative Commons Attribution-NonCommercial-ShareAlike 4.0 License](https://creativecommons.org/licenses/by-nc-sa/4.0/), which allows others to remix, tweak, and build upon the work non-commercially, as long as appropriate credit is given and the new creations are licensed under the identical terms.

For reprints contact: [reprint@ipinnovative.com](mailto:reprint@ipinnovative.com)

## 1. Introduction

The oral mucosa is constantly subjected to external and internal stimuli and therefore manifests a spectrum of diseases that range from developmental, reactive and inflammatory to neoplastic.<sup>1</sup> An increase in size of gingiva is a common feature of gingival disease. Pathologic connotations used in the past for increase in size of gingiva were gingival hyperplasia and hypertrophic gingivitis. Hyperplasia is an increase in the number of cells in tissues, resulting in increased tissue volume and hypertrophy is an increase in tissue size and volume resulting from increased cell size.<sup>2</sup> Hyperplastic lesions represent most frequently encountered oral lesions excluding caries, periodontal and periapical inflammatory disease. These lesions represent a reaction to some kind of irritation or low-grade injury like chewing, trapped food, calculus, fractured teeth and iatrogenic factors, including overextended flanges of dentures and overhanging dental restorations<sup>3</sup> In this group, fibrous hyperplasia,

associated or not to removable prosthetic appliances, represent the great majority of cases, and the second most common subgroup is represented by hyperplastic reactive gingival/alveolar lesions, including inflammatory gingival hyperplasia (IGH), pyogenic granuloma (PG), peripheral giant cell lesion (PGCL) and peripheral cemento-ossifying fibroma (PCOF).<sup>4</sup> Even with common etiologic factors, tissue response follows different courses in each individual lesion, reflected by their microscopical characteristics. Diagnosis of each lesion is aided by their clinical and radiographic features, but histopathology is the key for final diagnosis.

Gingival enlargement may be caused by a multitude of causes among which, most common is chronic inflammatory gingival enlargement, where the gingiva appears clinically soft and discoloured. This is caused by tissue edema and infective cellular infiltration, which is caused by prolonged exposure to bacterial plaque, and is treated with conventional periodontal treatment, such as scaling and root planing. Conditions in which the chronic inflammatory gingival enlargements include significant fibrotic components, which do not respond and

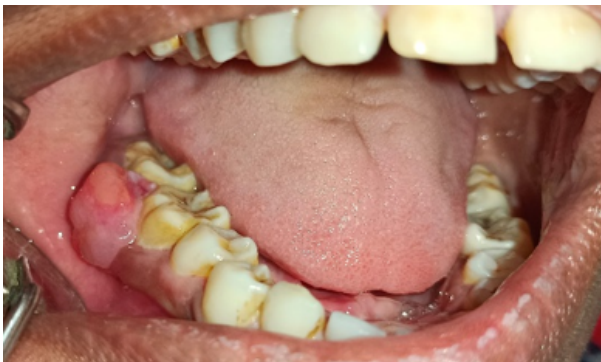\* Corresponding author.

E-mail address: [kaur94jazz@gmail.com](mailto:kaur94jazz@gmail.com) (J. Kaur).

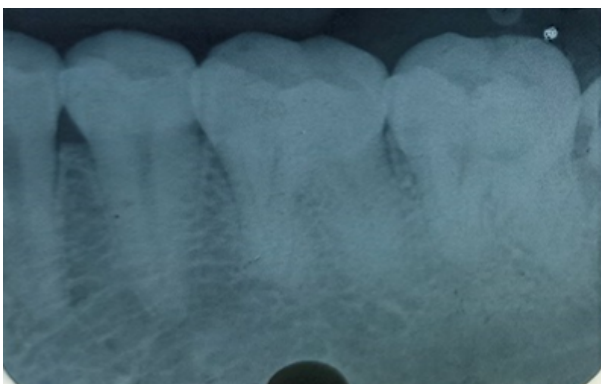
undergo shrinkage are treated by surgical removal of the excess tissue.<sup>5</sup> The main causes for the inflammatory gingival enlargement are accumulation and retention of plaque. Risk factors include poor oral hygiene as well as physical irritation of the gingiva by improper restorative and orthodontic appliances.<sup>6</sup>

## 2. Case Report

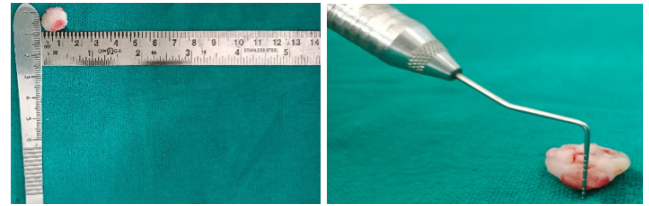
A 24-year-old female patient reported to the out patient Department of Periodontology and Oral Implantology Bhojia Dental College Baddi with a chief complaint of bleeding and swelling in lower left back region from last 2 weeks on 28/11/22. Intra-oral examination revealed a nodular, circumscribed polypoid lesion of soft tissue growth measuring about 1.8 x 1.4 x 0.8. The lesion was painless, reddish in color and bled easily while brushing and probing. The growth involved the marginal, interdental and attached gingiva on the facial surface of 46 and 47, extending up to the buccal vestibule from below of the involved teeth. Plaque and calculus were abundantly present. To check whether there was any bony involvement, radiograph was taken, which revealed no involvement of the underlying bone. The growth was adhered somewhere in the attached gingiva/interdental papilla.



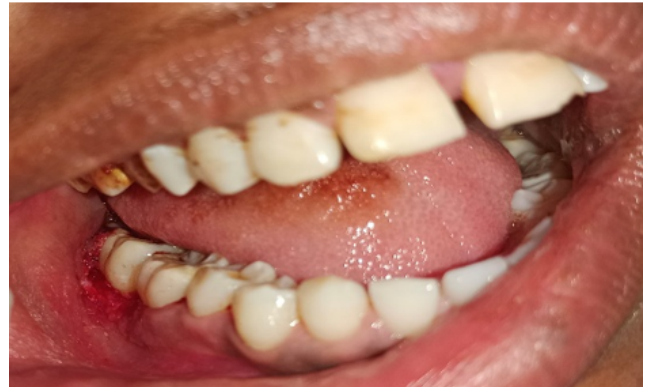**Fig. 1:** Pre-operative photograph



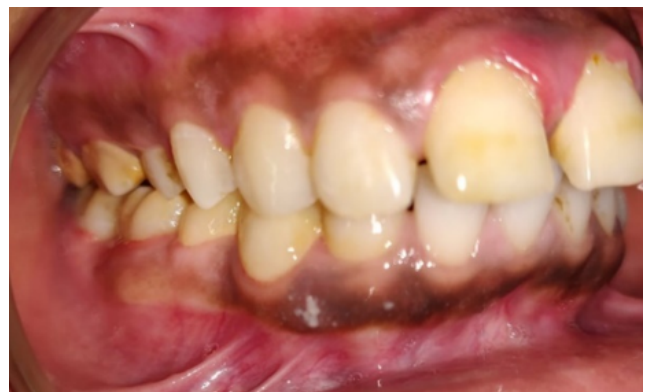**Fig. 2:** Pre-operative radiograph



**Fig. 3:** Excised lesion and its dimensions



**Fig. 4:** Post-operative photograph



**Fig. 5:** Healing after 10 days

The provisional diagnosis of pyogenic granuloma, peripheral ossifying fibroma and peripheral giant cell granuloma for the growth were made. Surgical excision of the tissue was planned and the excised tissue was sent for histopathological examination to confirm the final diagnosis.

## 3. Treatment

Initial examination phase 1 therapy was started consisting of oral hygiene instructions, scaling and root planning to remove all the inflammatory component. Phase 1 therapy lead to slight improvement in clinical condition of the gingival tissue, but for the complete resolution of lesion., surgical excision was planned. Blood investigations were

advised to the patient before performing the surgery. The patient was recalled after three days for surgical excision of the lesion. The patient was motivated to maintain oral hygiene.

#### 4. Surgical Procedure

1. The surgical site was anesthetized by giving inferior alveolar nerve block with 2% lignocaine containing 1:200000 adrenaline.
2. The attachment of the tissue to be excised was checked with the William's Probe.
3. With no. 15 blade, complete excision of the tissue was done in coronal to apical direction. The surgical site was again explored not to leave any remnants of the tissue to avoid recurrence.
4. Any remaining calculus deposits were removed and thorough root planning was done.
5. Gingivoplasty was done to achieve physiologic contours.
6. Periodontal pack was placed for 1 week.

Post-operative instructions – The patient was dismissed and instructed to avoid intake of spicy food. In case if any swelling develops, patient was instructed to apply cold packs extra-orally. After 24 hours, warm saline rinses for 3-4 times daily were advised and was asked to rinse with 0.2% chlorhexidine mouthwash twice daily for 1 week starting the next day of the surgical excision of the lesion. Patient was recalled after 1 week for the follow-up appointment. Tablet NovaMox CV-625 antibiotic and combiflame analgesic was prescribed for three times daily for 3 days. After 1 week healing was satisfactory. The patient was kept under observation through recall check-ups.

The excised tissue was 1.8 x 1.4 x 0.8 cm in size, reddish pink in color and firm in consistency. The tissue was sent for histopathological examination

#### 5. Histopathology

The H & E stained section shows epithelium and connective tissue stroma. The epithelium is hyper keratinized stratified squamous epithelium with underlying connective tissue showing dense collagen fibres. The stellate and spindle shaped fibroblasts are plump. The connective tissue also shows endothelial lined blood vessels along with dense perivascular and focal chronic inflammatory infiltration predominantly consisting of lymphocytes and plasma cells.

Based on this, final diagnosis inflammatory fibrous hyperplasia with respect to 46, 47 was made.

#### 6. Discussion

Gingival hyperplasia is common feature of gingival diseases which can be inflammatory, non-inflammatory or combined.

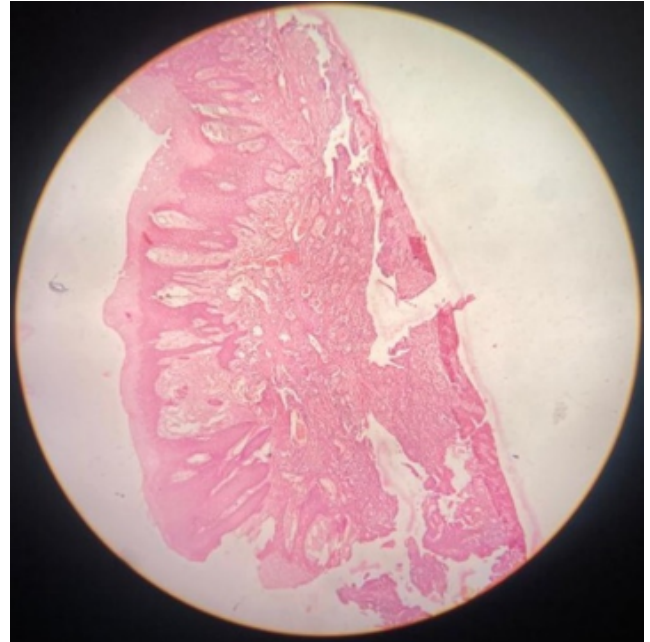


Fig. 6: Under 4X view

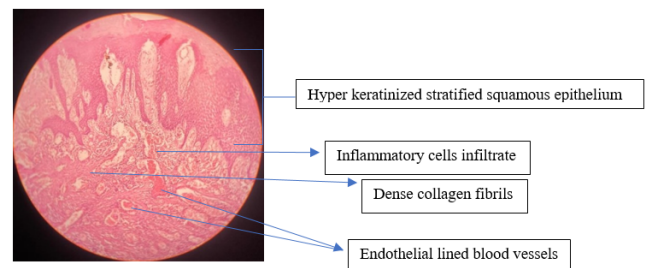


Fig. 7: Under 10X view

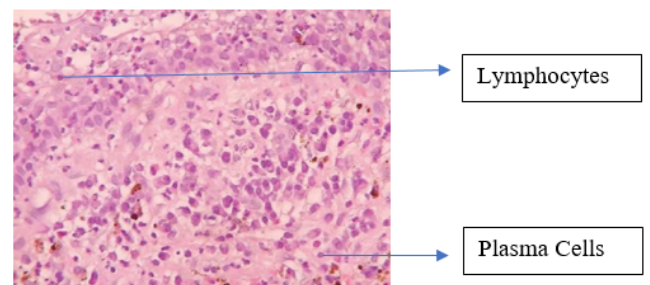


Fig. 8: Under 40x magnification, the connective tissue shows dense chronic inflammation of predominantly lymphocytes and plasma cells.

Treatment of these enlargement is normally based on the cause or underlying reason. Inflammatory enlargement normally responds well to local therapy i.e. SRP and oral hygiene maintenance, whereas others need surgical therapy. Clinical features of these lesions reflect various stages of their development. In early stages they appear as red and bled easily whereas in later stages they appear as firm, mature and avascular growth that can be sessile or pedunculated. In pathogenesis of these reactive lesions a necessary characteristic is chronic inflammation and repair happen concurrently with creation of granulation tissue. These tumor-like lesions are not neoplastic but indicate a chronic process in which an exaggerated repair occurs (granulation tissue and formation of scar) following injury.<sup>7</sup> A study by Nabhi K et al. in 2017, showed complete excision of the lesion with scalpel after controlling the inflammatory component and stated that recurrence is unlikely unless the inciting trauma continues or is repeated.<sup>8</sup> Histologically, inflammatory fibrous hyperplasia is made up of a mass of hyper plastic connective tissue with dilated blood vessels, usually with chronic inflammatory cells such as lymphocytes and plasma cells.<sup>3</sup> Surgical excision is the preferred treatment of choice, with removal of local irritants to prevent recurrence. Follow-up of the patient is needed as it exhibits a tendency to recur.

## 7. Conclusion

Inflammatory fibrous hyperplasia or fibrous hyperplasia is a benign soft tissue response to a local irritant which can be due to calculus, a sharp tooth, a broken filling, excessive plaque and other irritating factors. It is clinically difficult to diagnose, so histopathologic confirmation is mandatory to differentiate it from other gingival overgrowths reported in the literature. Complete surgical excision down to the periosteum is the preferred treatment to avoid the recurrence. Close post-operative follow-up is required. Patient should be advised for maintaining the oral hygiene properly.

## 8. Source of Funding

None.

## 9. Conflict of Interest

None.

## References

1. Effiom OA, Adeyemo WL, Soyele OO. Focal Reactive lesions of the Gingiva: An Analysis of 314 cases at a tertiary Health Institution in Nigeria. *Niger Med J*. 2011;52(1):35–40.
2. Newman MG, Takei H, Klokkevold PR, Carranza FA. Clinical Periodontology. 3rd ed. and others, editor; 2019. Available from: [https://www.amazon.in/Newman-Carranzas-Clinical-Periodontology-Third/dp/8131255034#detailBullets\\_feature\\_div](https://www.amazon.in/Newman-Carranzas-Clinical-Periodontology-Third/dp/8131255034#detailBullets_feature_div).
3. Shukla P, Dahiya V, Kataria P, Sabharwal S. Inflammatory hyperplasia: From diagnosis to treatment. *J Indian Soc Periodontol*. 2014;18(1):92–6.
4. Peralles PG, Viana AB, Azevedo R, Pires AL. Gingival and alveolar hyperplastic reactive lesions: Clinico-pathological study of 90 cases. *Braz J Oral Sci*. 2006;5(18):1085–94.
5. Newman MG, Takei H, Klokkevold PR, Carranza FA. Philadelphia: Saunders. *Clin Periodontol*. 1996;p. 754. Available from: <https://www.npg.org.uk/collections/search/person/mp54431/philadelphia-saunders>.
6. Hirschfield I. Hypertrophic gingivitis; its clinical aspect. *J Am Dent Assoc*. 1932;19(5):799–815.
7. Shadman N, Ebrahimi SF, Jafari S, Eslami M. Peripheral giant cell granuloma: a review of 123 cases. *Dent Res J (Isfahan)*. 2009;6(1):47–50.
8. Nabhi K, Mehra P, Sharma B, Sheikh SH, Sharma R. Inflammatory Hyperplasia Management: A Case Repor. *J Dent Med Sci*. 2017;16(5):64–71.

## Author biography

**Jaspreet Kaur**, Post Graduate Student

**Deepak Bala**, Reader

**Akshita Singh Thakur**, Post Graduate Student

**Sarvani Chandel**, Post Graduate Student

**Viniti Goel**, Professor and Head

**Cite this article:** Kaur J, Bala D, Thakur AS, Chandel S, Goel V. Inflammatory fibrous hyperplasia – A case report. *IP Int J Maxillofac Imaging* 2023;9(1):35-38.