

Content available at: <https://www.ipinnovative.com/open-access-journals>

IP International Journal of Maxillofacial Imaging

Journal homepage: <https://www.ijmi.in/>

## Original Research Article

## Changing patterns of mid face fractures in 21<sup>st</sup> century-A need to redefine René Le Fort's lines

Shivangini Nayak<sup>1</sup>, Ajay Kumar Pillai<sup>1,\*</sup>, Neha Jain<sup>1</sup>, Shaji Thomas<sup>2</sup>, Neha Gour<sup>1</sup>

<sup>1</sup>Dept. of Oral and Maxillofacial Surgery, People's Dental Academy, People's University, Bhopal, Madhya Pradesh, India

<sup>2</sup>Dept. of Oral and Maxillofacial Surgery, People's College of Dental Sciences and Research Centre, People's University, Bhopal, Madhya Pradesh, India



## ARTICLE INFO

## Article history:

Received 11-07-2023

Accepted 12-09-2023

Available online 18-09-2023

## Keywords:

Midface fractures

Le Fort lines

Maxillofacial Trauma

Le Fort classification

CT scan

## ABSTRACT

**Aim:** To study the changing patterns of mid face fractures using computed tomography scan.

**Materials and Methods:** 100 patients with midface fracture requiring open reduction and internal fixation were selected for this study. They underwent 2D and 3D computed tomography scan. The fracture lines were studied radiographically and intraoperatively and compared with the standard Le Fort lines.

**Results:** The study showed that men ranging from age 21-30 years were more likely to suffer midface fracture compared to women M:F =19:5. Road traffic accidents (RTA) happens to be the most common aetiology (78%) followed by assaults and accidental fall. The midface fractures that were encountered were divided into 3 categories after assessing the CT scans as follows- 1. Similar to Le Fort lines-24%; 2. Combination of Le fort lines-12%; 3. Deviation from Le Fort lines-64%.

The 64% of patients with deviations were divided into 5 categories- 1. V1: Additional line from the pyriform aperture to the infraorbital rim of the same side. (37.17%); 2. V2: Additional line connecting the Le Fort fracture line to the infraorbital rim. (38.46%); 3. V3: Additional line connecting the pyriform aperture to the orbit's lateral wall without crossing the infraorbital rim on the same side. (12.82%); 4. V4: Additional line involving the fractured segment, running from the infraorbital rim across the canine fossa and finishing on the dentoalveolar segment on the same side. (5.12%); 5. V5: Pterygoid plates not fractured. (6.41%).

**Conclusion:** Every patient with a facial fracture should undergo a complete clinical and radiographic assessment. In order to accurately determine the fracture patterns, it is necessary to review the sectional pictures of the scans coupled with 3D-reconstructed images. Newer classification needs to be discussed to describe the deviation caused by high velocity objects. To treat the patient promptly and to establish better communication between the surgeon and radiologist.

This is an Open Access (OA) journal, and articles are distributed under the terms of the [Creative Commons Attribution-NonCommercial-ShareAlike 4.0 License](https://creativecommons.org/licenses/by-nc-sa/4.0/), which allows others to remix, tweak, and build upon the work non-commercially, as long as appropriate credit is given and the new creations are licensed under the identical terms.

For reprints contact: [reprint@ipinnovative.com](mailto:reprint@ipinnovative.com)

### 1. Introduction

In the year 1901 French surgeon Rene Le Fort carried out a series of experiments on cadaver heads to understand the fracture patterns seen in the middle third of face. He believed that fractures were dependent on the point of application of a force, the direction of a wounding agent,

and the position of the head during trauma. He utilised tools like a metal shaft or wooden club to inflict blunt trauma.<sup>1,2</sup> The fractures that resulted from the experiments were meticulously recorded. Thus, Rene Le Fort postulated the famous Le Fort lines that remains the most frequent way to classify and treat mid face fractures.

Although the aetiology for midface trauma might have remained the same but the mass and velocity of the wounding object has changed. There is an upsurge of

\* Corresponding author.

E-mail address: [drajaypillai@yahoo.co.in](mailto:drajaypillai@yahoo.co.in) (A. K. Pillai).

road traffic accidents cases reporting the emergency rooms in tertiary health care establishments. Other aetiology of trauma includes injuries resulting from interpersonal arguments, industrial accidents, sports injuries, accidental falls etc.<sup>3</sup> Several radiologists and OMF surgeons have observed that a lot of fractures they encounter do not confer to the traditional Le Fort lines.<sup>4</sup>

Knowing Le Fort completed this famous work almost 110 years ago, it is not surprising that it could be considered inadequate for modern-day facial trauma. Marsh et al, (1986) began identifying some of the limitations with the original Le Fort descriptions when they wrote: “Our pilot study of a small series of Le Fort III fractures (diagnosed on clinical and conventional skull roentgenographical grounds) has already shown that the traditional nomenclature, produced for low velocity trauma, is anatomically inadequate for the magnitude of injuries seen today. Severe comminution, asymmetrical irregular fracture lines, and involvement of the cranial base and vault characterize the modern traumatic craniofacial disjunction.”<sup>2</sup>

Due to its ease of use and levels of anatomic difference, the Le Fort lines still enjoys the centre stage as one of the commonly used classifications. Several authors have also tried to categorise things based on anatomical sites and occlusion involvement.<sup>5,6</sup> This paper attempts to understand these changing fracture patterns in more depth.

## 2. Materials and Methods

The study consisted of patients who reported to the outpatient department of Oral and Maxillofacial of People’s Dental Academy and the Emergency Department of People’s Hospital between the year 2020 and 2022. A sample of 100 Patients diagnosed with midface fracture were selected. Patients were informed about the procedure and the risks involved. It was followed by thorough clinical examination. Fractures were evaluated using 3D reconstructed images and multiplanar computed tomography scan, studied intraoperatively and finally compared with the standard Le fort lines.

The data collected was segregated in terms of age, sex and aetiology of the trauma. The fracture patterns were analysed and grouped into the following categories-

1. Fracture pattern that resembles Le Fort’s classification.
2. Fracture pattern that partially resembles Le Fort classification which includes unilateral, bilateral, oblique Le fort lines and incomplete fracture lines.
3. Fractures that did not conform to Le fort classification or grossly comminuted fractures.

### 2.1. Inclusion criteria

1. Patients with mid face fracture.
2. Patients with age above 15 years.

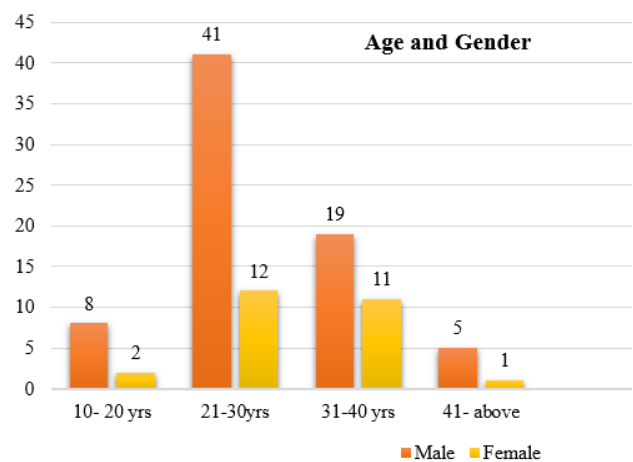
3. Patients who consent to be a part of the study.

### 2.2. Exclusion criteria

1. Any fracture not including mid face.
2. Paediatric fractures.
3. Patient with pathological fracture.

## 3. Results

Collected data was segregated based on Age, gender, etiology, vehicle type, whether patient was wearing helmet or not, history of alcohol use. The trend of midface fracture showed male predominance with an overwhelming 73 % (n=73) compare females who included only 26 % (n=26) cases. The male to female ratio was 19:5 (Graph 1).



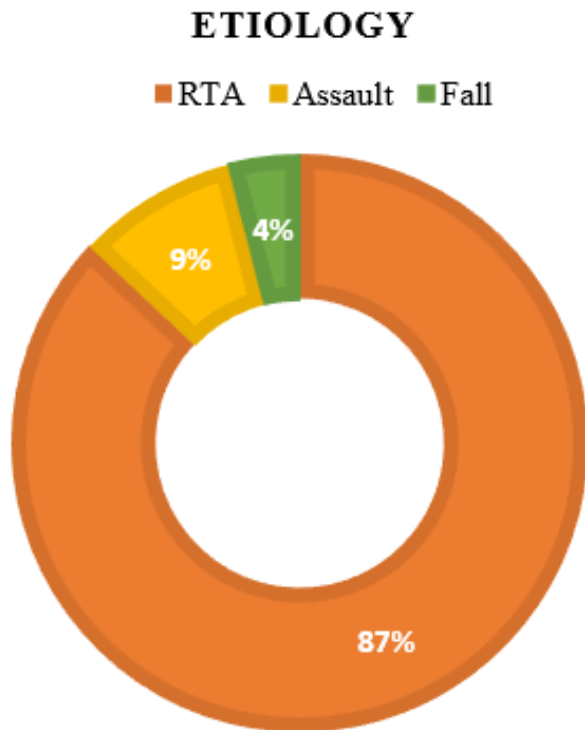
Graph 1: Age and gender

Road traffic accidents were the most frequent cause (87%), followed by assault (9%) and falls (4%) (Graph 2). Two-wheelers (94%) and drunk drivers without helmets (55%) were most frequently involved in road traffic accidents.

A total of 100 patients with mid face fractures underwent CT scanning, resulting in 2D sections and 3D-reconstructed images, which were then scrutinized. There were 173 facial bone fractures among the 100 patients. The isolated and combination of facial bone fractures and distribution of facial fractures according to classification has been mentioned in the following tables.

The CT scans were scrutinized and 173 facial fractures were identified. The midface fractures that were encountered were divided into 3 categories (Graph 3) after assessing the 2D and 3D CT scans as follows-

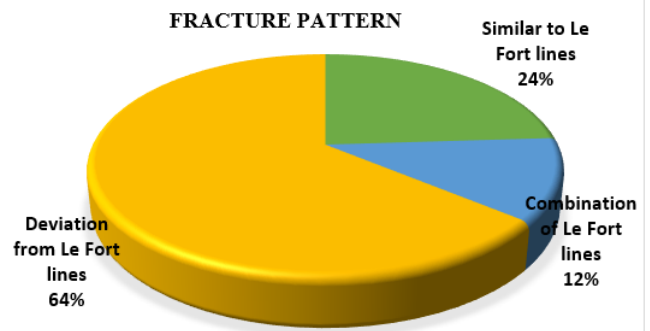
1. Similar to Le Fort lines-24%
2. Combination of Le fort lines-12%
3. Deviation from Le Fort lines-64%



Graph 2: Etiology

Table 3: Classification of patient based on fracture pattern

Pattern	Frequency of patients
Similar to Le Fort lines	24
Combination of Le fort lines	12
Deviation from Le Fort lines	64



Graph 3: Fracture pattern

Table 1: Distribution of Patients according to the category of fracture

Classification	No. of patients
Isolated Le fort fractures	21
Le fort fracture with ZMC	30
Combination of various Le fort fractures	17
Combination of various Le fort fractures ZMC	5
Le fort fracture with involvement of cranial bones	27
Total	100

Table 2: Distribution according to the bone involved in the facial fracture

Facial fracture	Right	Left	Total
Le Fort I	15 (8.67%)	24 (13.87%)	39 (22.54%)
Le Fort II	18 (10.40%)	15 (8.67%)	33 (19.07%)
Le fort III	1(0.57%)	1 (0.57%)	2 (1.15%)
ZMC	27 (15.6%)	21 (12.13%)	48 (27.74%)
Cranial Bone	21 (12.13%)	9 (5.20%)	30 (17.34%)
Mandible	18 (10.40%)	3 (1.73%)	21 (12.13%)
Total	101 (58.38%)	72 (41.61%)	173 (100%)

The isolated and combination of facial bone fractures and distribution of facial fractures according to classification has been mentioned in the following tables.

It is found that most the cases of Le fort fractures don't coincide with the tradition Le fort lines. 5 patterns were identified.

**V1:** An Additional line from the pyriform aperture to the infraorbital rim of the same side.

**V2:** An additional line connecting the Le Fort fracture line to the infraorbital rim.

**V3:** Additional line connecting the pyriform aperture to the orbit's lateral wall without crossing the infraorbital rim on the same side.

**V4:** Additional line involving the fractured segment, running from the infraorbital rim across the canine fossa and finishing on the dentoalveolar segment on the same side.

**V5:** Pterygoid plates were not fractured.

In the 64 cases that were deviated from the standard Le Fort lines, a total of 78 variations were found. On the same side or both sides (Table 4).

### 3.1. Statistical analysis

Data was entered in Microsoft Excel spreadsheet and statistical analysis was carried out using descriptive statistics in the Statistical Package for the Social Sciences (SPSS) software, version 25.0, (IBM SPSS, Inc. Chicago, Illinois). For statistical analysis Pearson's Chi-squared test was used. A cut off of  $p \leq 0.05$  was considered to be statistically significant with a 95% confidence interval. Tables 5, 6 and 7.

**Table 4:** Distribution of deviation according to site

Deviation	Right	Left	Total
V1	11 (14.10%)	18 (23.07%)	29 (37.17%)
V2	14 (17.94%)	16 (20.51%)	30 (38.46%)
V3	4 (5.12%)	6 (7.69%)	10 (12.82%)
V4	3 (3.84%)	1 (1.28%)	4 (5.12%)
V5	2 (2.56%)	3 (3.84%)	5 (6.41%)
Total	34 (43.58%)	44 (56.41%)	78 (100%)

**Table 5:** Frequency distribution of type of fracture according to age, gender and aetiology

Type of fracture	Gender		Age groups				Etiology		
	Male	Female	10-20	21-30	31-40	>41	RTA	Assault	Fall
Similar to LF Lines	17%	7%	3%	12%	7%	2%	22%	2%	0%
Combination of LF Fracture	9%	3%	0	10%	2%	0%	10%	1%	1%
Deviation from LF # lines	47%	17%	8%	31%	21%	4%	55%	6%	3%
Total	73%	27%	11%	53%	30%	6%	87%	9%	4%
p- value	0.957		0.457				0.788		

**Table 6:** Frequency distribution according to aetiology of fracture and age and gender

Etiology	Gender		Age groups			
	Male	Female	10-20	21-30	31-40	>41
RTA	63%	24%	10%	46%	26%	5%
Assault	7%	2%	1%	4%	3%	1%
Fall	3%	1%	0%	3%	1%	0%
Total	73%	27%	11%	53%	30%	6%
p- value	0.938		0.948			

**Table 7:** Frequency distribution of type of deviation according to age, gender and aetiology

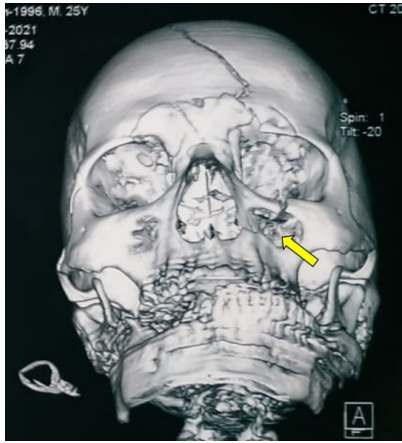
Type of deviation	Gender		Age groups				Etiology		
	Male	Female	10-20	21-30	31-40	>41	RTA	Assault	Fall
No deviation	26%	10%	5%	20%	10%	1%	27%	7%	2%
V1	15%	6%	4%	11%	4%	2%	21%	0%	0%
V2	12%	9%	1%	10%	9%	1%	18%	2%	1%
V3	4%	0%	0%	4%	0%	0%	4%	0%	0%
V4	2%	0%	0%	0%	1%	1%	2%	0%	0%
V5	2%	0%	0%	1%	1%	0%	2%	0%	0%
Combination	12%	2%	1%	7%	5%	1%	13%	0%	1%
Total	73%	27%	11%	53%	30%	6%	87%	9%	4%
p- value	0.337		0.447				0.511		

#### 4. Discussion

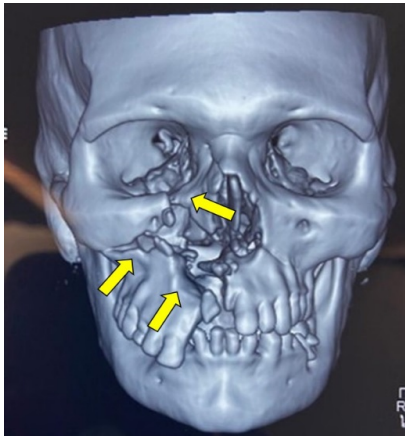
The midface is the region of the facial skeleton that extends from the maxillary occlusal plane to the base of the skull. This anatomical unit supports the globes, sinuses, muscles of mastication and facial expressions, and maxillary teeth, making it significant from a functional and aesthetic standpoint. It supports the physiologic operation of the respiratory, digestive, olfactory, and ocular systems. The bones that make up the middle portion of the face rarely fracture on their own. Because of the complexity of the midface, it can withstand the forces of mastication from below and shield some crucial structures from harm. The upper teeth and the skull's bones are connected by a sequence of bony pillars called buttresses that support up

the middle part of the facial skeleton.<sup>5</sup>

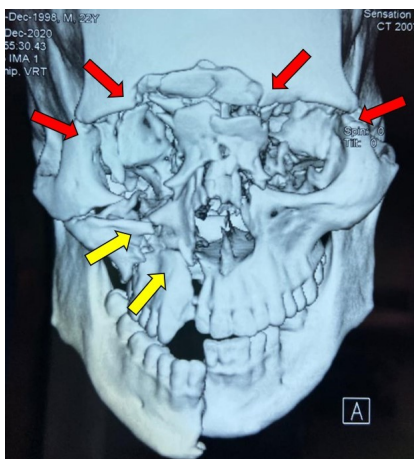
There are certain broad trends that can be observed in the pattern of the midface fractures when age distribution, gender predilection and aetiology are taken into consideration, even though several such epidemiological studies of facial fractures in several institution and communities have been analysed in the literature for many years. This trend can also be observed in our study where the frequency of mid face fractures was predominant amongst the male population (73%, n=73), out of which most of the men fell to the age group of 21-30 range, whereas the females consisted of about 27% (n=27) of the sample size. The cause of trauma for 87% of cases happen to be Road traffic accidents (RTA), followed by assault (9%)



**Fig. 1:** Depicts V1 deviation on left side along with Le fort II fracture (yellow arrow).



**Fig. 2:** Depicts Le fort II fracture on the right side, the fracture lines showed V1 and V2 type of deviation along with mid palatal split (yellow arrows).



**Fig. 3:** Depicts pan facial trauma with Le fort III fracture (red arrows), comminution of the right half of midface along with V1 and V4 deviation (yellow arrows).

and accidental fall (4%). The results were similar with the study conducted by Inas Elfiky (2017).<sup>7</sup> The demographic data collected by Punit S Dikhit et al (2019) also showed the majority of cases (68.5%) were between the age range of 19 to 39 years. Midface fractures frequently occur in conjunction with other facial fractures or as part of panfacial injuries due to their central placement within the facial skeleton,<sup>8</sup> which also reflects in our study wherein out of 173 fractured bones that were identified in 100 patients there were 48 ZMC fractures, 30 cranial bone fractures and 21 mandibular fractures as well.

The interruption of the middle face skeletal unit's continuity is caused by the action-reaction of opposing forces, whose sources can include vehicular collisions, interpersonal aggression, falls, sports, workplace accidents, and projectiles from firearms. The location, direction, and strength of the force, as well as the surface and consistency of the item, all affect the pattern of fractures. Facial bones have varying degrees of fracture tolerance, which are primarily influenced by their thickness, density, and proximity to sinuses. Nasal fractures are the most common fractures in the facial region because to its resistance and anatomical placement, followed by orbital and zygomatic fractures. Fractures occur when a force exceeds the stress limit; the more energy, the more bone damage, hence greater the degree of fracture.<sup>9</sup>

Rene Le Fort classified midface fractures in 1901 according to one of three major lines of weakness that correspond to the most typical fracture locations. Although Le Fort classified these fractures as bilateral in nature, individuals with trauma most frequently have combination fractures and sometimes its unilateral in nature which was also noted in our study. The observation was that impact to the face are rarely exactly centred, allowing for the range of midface fracture patterns which was not present in Le Fort's experiments where the impact simulated were centred and were of low velocity in nature. However, Le Fort's classification system does give surgeons a way to identify the general level of significant fracture sites and offer areas of stability as a reference to plan fixation accordingly.<sup>10</sup>

The Le Fort method does not allow for the description of vertical or segmental alveolar fractures, comminuted fractures, or bone loss, despite the classification's utility as previously indicated.

The gold standard for fracture identification has long been the computed tomography (CT) scan. When diagnosing complicated and comminuted fractures, 3D scans are quite helpful. They also make treatment planning much simpler, more precise, and quicker.<sup>11</sup> In our study, it was possible to accurately correlate the intraoperative findings with the fractures detected in the 3D images, similar observation was made in the study conducted by Le A Fox et al<sup>12</sup> and R Tanrikulu.<sup>13</sup> The degree of fracture displacement could be precisely determined by the surgeons



and trainees.

However, as the 3D images were unable to provide information on soft tissue damage and there was some degree of artifact during 3D reconstruction. These shortcomings were overcome by examining the 2D CT scans. Fracture lines that could have been missed out on 3D CT could be detected using 2D view in detail. Soft tissue injuries included hematomas, fat or muscle entrapment, etc can also be seen.<sup>10</sup>

In our study we observed that there about only 24 % cases (n=24) that resembled standard Le Fort lines, about 56% cases (n=56) resembled the standard lines only partially or they were a combination of different Le fort lines and an overwhelming 64% of cases (n=64) were the cases that showed deviation from the standard Le fort lines. The results are comparable to a similar study conducted by Rashmi S Patil et al (2014) where 24% cases resembled standard Le fort lines, 54% cases resembled Le fort lines partially and 20% cases were communitated fractures which couldn't be classified under Le Fort classification.<sup>10</sup>

Out of 100 patients that were shortlisted for the study 64% (n=64) of them showed deviations from the classical fracture lines described by Le fort. These deviations were then further grouped into 5 categories based on the patterns that were observed more frequently as V1, V2, V3, V4 and V5 respectively. These deviations were also described in the study done by Satish P et al in (2017).

We observed that there were about 37.17% (n= 29) of fracture sites that were showing V1 variation, the left side (23.07%) appeared to be more common than the right side (14.10%). These findings were similar to the study published by Satish et al who found that 34.5% of fracture sites showed this variation. About 38.46% (n=30) showed V2 variation in our study whereas In Satish P et al's study only 25.4% (n=14) showed this type of deviation. 12.82% (n=10) fracture sites showed V3 variation in our study whereas in Satish P et al's study 5.4% of fracture sites showed this deviation .5.12% (n=4) showed V4 type deviation meanwhile Satish et al's study showed about double the amount of this deviation (10.9%).6.41%(n=5) fracture site showed V5 type of deviation whereas Satish et al's study showed about 23.6% of this deviation which is about 4 times of the deviation observed in our study.<sup>14–16</sup>

A few cases in our study we encountered that more than one type of variation was present on the same side Figure 1 is a case where V1 and V5 deviations were present on left side along with Le fort II fracture. Figure 2 depicts a case of Le fort II fracture on the right side, the fracture lines showed V1 and V2 type of deviation along with mid palatal split causing the right maxilla to sag in a downward and forward direction. Figure 3 depicts case of pan facial trauma with Le fort III fracture there was severe communitation of the right half of midface along with V1 and V4 deviation.

## 5. Conclusion

With the advent of rapid urbanisation, industrialisation, and ever-increasing immigration of people from rural to urban areas, fast paced life and faster moving vehicles; we are experiencing a rapid increase in the prevalence of motor vehicle collisions. As Oral and Maxillofacial surgeons it's important we diagnose and treat these fractures early and promptly, for this identifying the type of injury becomes important. It was about a century ago when Rene Le Fort proposed the famous 'Lines of resistance' which we still use to classify fractures even today. Although, the convenience and use of this classification remains undisputed. There are a few shortcomings to this classification. The experiments that were carried out by Le Fort were based on low velocity trauma which was more or less confined to inflicting the trauma centrally.<sup>17–20</sup>

In our study we have tried to study the common deviations which we encountered. The drawback of the study is that the limited sample size. Every patient with a facial fracture should undergo a complete clinical and radiographic assessment. In order to accurately determine the fracture patterns, it is necessary to review the sectional pictures of the scans coupled with 3D-reconstructed images. CT is a useful tool in the diagnosis of midface fractures. There is a need for new studies and research in this area because variations from traditional Le Fort patterns are occurring rather regularly and necessitating extra places of fixation. Le Fort fractures' categorization may change if similar deviations are discovered repeatedly. Therefore, more research should be done to track and identify the shifting Le Fort line patterns using a bigger sample size and a longer time frame.

## 6. Source of Funding

None.

## 7. Conflicts of Interest

There are no conflicts of interest.

## References

- Gartshore L. A brief account of the life of René Le Fort. *Br J Oral Maxillofac Surg*. 2010;48(3):173–5. doi:10.1016/j.bjoms.2009.09.003.
- Noffze MJ, Tubbs RS. René Le Fort 1869-1951. *Clin Anat*. 2011;24(3):278–81. doi:10.1002/ca.2109.
- Gassner R, Tuli T, Hächl O, Rudisch A, Ulmer H. Craniomaxillofacial trauma: a 10 year review of 9,543 cases with 21,067 injuries. *J Craniomaxillofac Surg*. 2003;31(1):51–61. doi:10.1016/s1010-5182(02)00168-3.
- Satish P, Prasad K, Lalitha RM, Ranganath K, Sagar P. Analysis of the Changing Patterns of Midface Fractures Using 3D Computed Tomography: An Observational Study. *Craniomaxillofac Trauma Reconstr*. 2018;11(4):265–72. doi:10.1055/s-0037-1606250.
- Bonanthaya K, Panneerselvam E, Manuel S, Kumar VV, Rai A. *Oral and Maxillofacial Surgery for the Clinician*. Singapore: Springer; 2021. Available from: <https://link.springer.com/book/10.1007/978-981-15-1346-6>.

6. Marciani RD. Management of midface fractures: fifty years later. *J Oral Maxillofac Surg.* 1993;51(9):960–8. doi:10.1016/s0278-2391(10)80035-7.
7. Elfiky I, Sammak DE, Sammak AE, Abdelhady M. Diagnostic performance of multi-slice computed tomography using 2D and 3D images in the assessment of Le Fort fractures. *Egypt J Radiol Nucl Med.* 2017;48(2):415–24.
8. Dikhit PS, Mohapatra M, Jena AK, Srivastava A. Emerging Trends of Zygomaticomaxillary Complex Fractures and Their Etiological Analysis in a Tertiary Health Centre from Eastern India: A Retrospective Study. *J Maxillofac Oral Surg.* 2021;20(1):70–5. doi:10.1007/s12663-019-01295-w.
9. Reinoso PC, Robalino JJ, De Santiago M. Biomechanics of midface trauma: A review of concepts. *J Oral Maxillofac Surg Med Pathol.* 2021;33(4):389–93.
10. Mcrae M, Frodel J. Midface fractures. *Facial Plast Surg.* 2000;16(2):107–13. doi:10.1055/s-2000-12572.
11. Patil RS, Kale TP, Kotrashetti SM, Baliga SD, Prabhu N, Issrani R, et al. Assessment of changing patterns of Le fort fracture lines using computed tomography scan: an observational study. *Acta Odontol Scand.* 2014;72(8):984–8. doi:10.3109/00016357.2014.933252.
12. Fox LA, Vannier MW, West OC, Wilson AJ, Baran GA, Pilgram TK, et al. Diagnostic performance of CT, MPR and 3DCT imaging in maxillofacial trauma. *Comput Med Imaging Graph.* 1995;19(5):385–95. doi:10.1016/0895-6111(95)00022-4.
13. Tanrikulu R, Erol B. Comparison of computed tomography with conventional radiography for midfacial fractures. *Dentomaxillofac Radiol.* 2001;30(3):141–6. doi:10.1038/sj/dmfr/4600593.
14. Saigal K, Winokur RS, Finden S, Taub D, Pribitkin E. Use of three-dimensional computerized tomography reconstruction in complex facial trauma. *Facial Plast Surg.* 2005;21(3):241–20. doi:10.1055/s-2005-922862.
15. Hopper RA, Salemy S, Sze RW. Diagnosis of midface fractures with CT: what the surgeon needs to know. *Radiographics.* 2006;26(3):783–93. doi:10.1148/rg.263045710.
16. Erdmann D, Follmar KE, Debruijn M, Bruno AD, Jung SH, Edelman D, et al. A retrospective analysis of facial fracture etiologies. *Ann Plast Surg.* 2008;60(4):398–403. doi:10.1097/SAP.0b013e318133a87b.
17. Follmar KE, Baccarani A, Das RR, Erdmann D, Marcus JR, Mukundan S, et al. A clinically applicable reporting system for the diagnosis of facial fractures. *Int J Oral Maxillofac Surg.* 2007;36(7):593–600.
18. Fraioli RE, Branstetter BF, Deleyiannis FWB. Facial fractures: beyond Le Fort. *Otolaryngol Clin North Am.* 2008;41(1):51–76. doi:10.1016/j.otc.2007.10.003.
19. Gandhi S, Ranganathan LK, Solanki M, Mathew GC, Singh I, Bithar S, et al. Pattern of maxillofacial fractures at a tertiary hospital in northern India: a 4-year retrospective study of 718 patients. *Dent Traumatol.* 2011;27(4):257–62. doi:10.1111/j.1600-9657.2011.00996.x.
20. Magagula SC, Hardcastle T. Defining current facial fracture patterns in a quaternary institution following high-velocity blunt trauma. *SA J Radiol.* 2016;20(1):1–6.

### Author biography

**Shivangini Nayak**, Post Graduate Resident

**Ajay Kumar Pillai**, Vice Dean, Professor and HOD

**Neha Jain**, Professor

**Shaji Thomas**, Professor and HOD

**Neha Gour**, Post Graduate Resident

**Cite this article:** Nayak S, Pillai AK, Jain N, Thomas S, Gour N. Changing patterns of mid face fractures in 21<sup>st</sup> century-A need to redefine René Le Fort's lines. *IP Int J Maxillofac Imaging* 2023;9(3):149-155.