

Content available at: <https://www.ipinnovative.com/open-access-journals>

IP International Journal of Maxillofacial Imaging

Journal homepage: <https://www.ijmi.in/>

Case Report

Compound odontome

A. Backiyalakshmi¹, VC Divya^{1*}

¹Dept. of Oral Medicine and Radiology, SRM Kattankulathur Dental College and Hospital, Kattankulathur, Tamil Nadu, India



ARTICLE INFO

Article history:

Received 10-11-2023

Accepted 18-12-2023

Available online 01-01-2024

Keywords:

Compound

Ameloblastic

Fibro-odontomes

ABSTRACT

Odontomas are developmental anomalies resulting from the growth of completely differentiated epithelial and mesenchymal cells that give rise to functional ameloblast and odontoblast. During odontoma development, enamel and dentin can be deposited in such a way that the resulting structures show anatomically similar to normal teeth structures. odontomes were classified according to their developmental origin as epithelial, composite (epithelial and mesodermal), and connective tissues. According to the WHO classification, odontomes can be divided into three groups such as complex, compound, and ameloblastic fibro-odontomes. Compound odontomas commonly occur in the incisor-canine region of the maxilla and complex odontomas are frequently located in the premolar and molar region of both jaws.

This is an Open Access (OA) journal, and articles are distributed under the terms of the [Creative Commons Attribution-NonCommercial-ShareAlike 4.0 License](https://creativecommons.org/licenses/by-nc-sa/4.0/), which allows others to remix, tweak, and build upon the work non-commercially, as long as appropriate credit is given and the new creations are licensed under the identical terms.

For reprints contact: reprint@ipinnovative.com

1. Introduction

In medicine and dentistry, the term "odontome" initially referred to any tumour or tumor-like lesion, such as a neoplastic cyst that developed from the tissues that make teeth.¹ The most common benign odontogenic tumour which arises from the epithelium as well as mesenchyme is odontome.² They constitute to around 22% of the benign odontogenic tumors. When enamel and dentin are deposited during the growth of the tumour in such a way that the resulting structures resemble normal teeth anatomically, the disease is referred to as a compound odontoma.³ However, a complex odontoma is referred to when the dental tissues form a simple irregular mass that occurs in an atypical pattern. Compound composite odontomas make up the majority of those in the anterior section of the jaws (61%), whereas complex composite odontomas make up the majority in the posterior segment (34%).⁴ The right side of the jaw had both types of odontomas more frequently than the left (compound 62%,

complex 68%).⁵ Odontomes' aetiology is yet unknown. It has been linked to a variety of pathological conditions, including local trauma, inflammatory and/or infectious processes, mature ameloblasts, cell remnants from the dental lamina, hereditary anomalies (Gardner's syndrome, Hermanns syndrome), odontoblastic hyperactivity, and changes in the genetic element in charge of regulating dental development. Complex odontomas are usually found in the premolar and molar region of both jaws, while compound odontomas frequently occur in the incisor-canine region of the maxilla.⁶ Odontomas can occur at any age, however the majority are discovered in the first two decades of life. There is no gender preference, and routine radiography can find the majority of lesions.⁷ The prevalence was found to be slightly higher in men (59%) than in women (41%), according to Budnick. 67% of all odontomas occurred in the maxilla, and 33% in the mandible.⁸ The complex odontoma displayed a preference towards the back of the jaw, whereas the anterior region was preferred by the compound odontoma.⁹ Interestingly, the right side of the jaw experienced both forms of odontomas more frequently

* Corresponding author.

E-mail address: divyav@srmist.edu.in (V. C. Divya).

than the left. Contrary to complex odontomas, which appear as a radiopaque solid mass occasionally containing nodular elements and surrounded by a fine radiotransparent zone, compound odontomas are radiographically characterised by multiple irregular radio-opaque lesions that vary in size and shape.¹⁰ The unilocular lesions are clearly distinguished from the healthy bone by a corticalization line. Odontomas arise as a result of an inherited genetic mutation or any genetic interference with the control of tooth development.¹¹ He added that another potential contributing reason to tooth decay may be the preservation of lamina fragments between the tooth germs. Excision surgery is the conservative method of treating odontomas.

2. Case Presentation

A 30 year old female patient named Mrs Selvi, came to the Department of Oral Medicine and Radiology, Sri Ramachandra University, with the complaint of pain in relation to the lower front region of jaw past 2 days. History of presenting illness revealed that RCT was done in relation to the same tooth 1 year back following which she has pain past 2 days. Pain is of continuous type and aggravates on eating and relieves after sometime.

On intraoral examination, restoration evident in relation to 41 with tenderness on percussion and grade I mobility present.

IOPA in relation to 41 reveals discontinuous radiopaque filling material in relation to pulp canal of 41 suggestive of incomplete obturation. IOPA also reveals a well-defined radiopacity approximately measuring 1.3x1cm present in relation to 42 region consisting of multiple small tooth like structures, surrounded by a radiolucent rim. Mandibular occlusal radiograph reveals two round radiopaque structures approximately 4x5mm between 42 and 43 region.

This case provisionally diagnosed as compound odontome in relation to 42 region. Histopathological report reveals Decalcified section shows dentin matrix with regularly arranged dentinal tubules, cementum, pulp tissue and loosely arranged fibrous matrix. Suggestive of a compound odontome.

On the basis of history, clinical examination, radiographic interpretation and with a help of biopsy report final diagnosis was given as Compound odontoma. The Patient was advised surgical removal and Re-RCT irt 41.

3. Discussion

Odontomas are asymptomatic odontogenic hamartomatous abnormalities that are relatively prevalent.¹² The combination with impacted or retained primary teeth is the most typical clinical manifestation for an odontoma. Compound odontomas are described as "malformations in which all dental tissues are represented in a more orderly

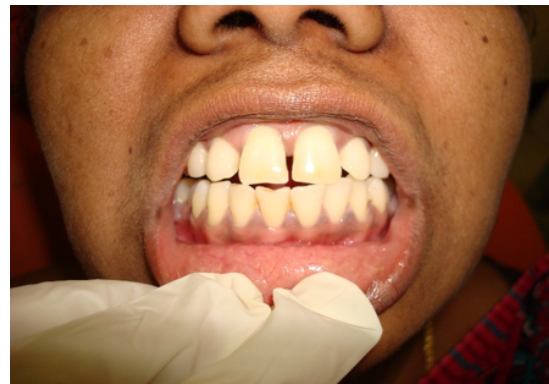

Figure 1: Restored tooth 41

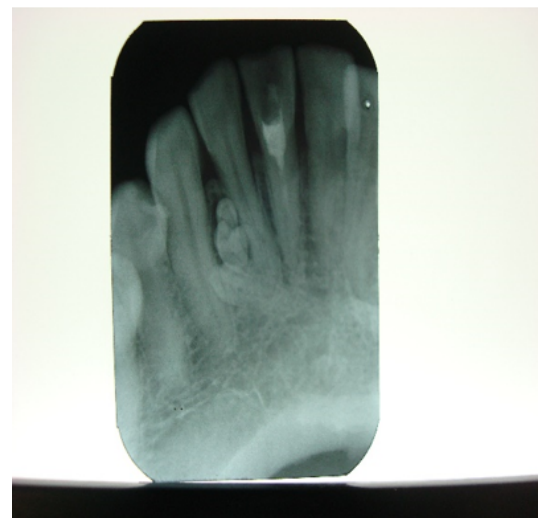


Figure 2: IOPA of 41

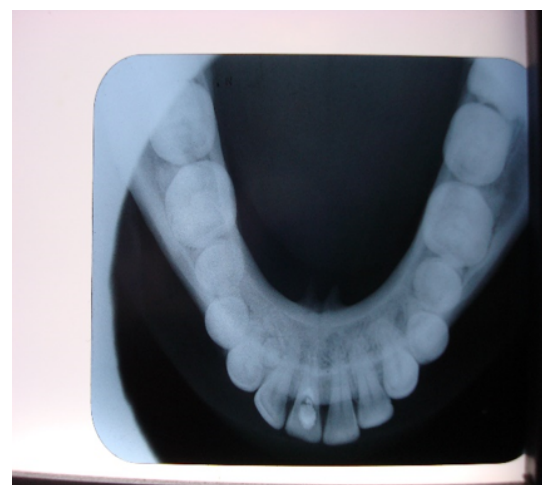

Figure 3: Occlusal radiograph

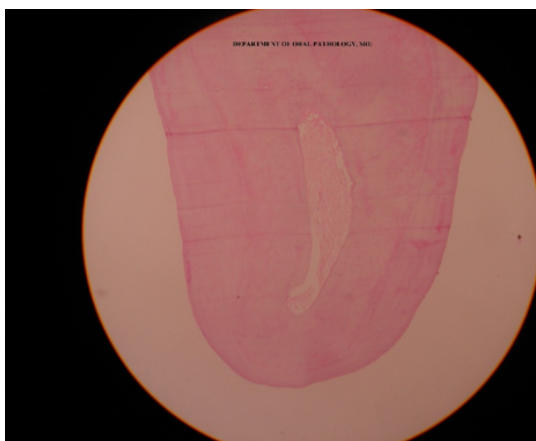


Figure 4: Microscopic image

pattern than in the complex odontoma, so that the lesion contains many tooth-like structures," by the World Health Organisation (WHO).^{13,14} The enamel, dentin, cementum, and pulp are arranged similarly to how they are in a normal tooth, even though the majority of these structures do not morphologically match the teeth in the normal dentition.

At the clinical level, compound odontoma is frequently linked to problems of tooth emergence and impaction, as well as probable delayed tooth eruption.¹⁵ Compound odontomas can also be characterised by pain (13.3%) and edema (8.9%), even though 25% of patients are asymptomatic. The anterior maxilla (81.8%) is where compound odontomas are most commonly found.¹⁶ Complex odontomas are abnormalities in which all dental tissues are present but are distributed in a disorganised manner. Other odontoma varieties, known as mixed odontomas, occasionally appear and combine the traits of compound and complicated odontomas. Odontomes are infrequently documented in conjunction with primary teeth and are more common in the permanent dentition.¹⁷ Odontome associations with deciduous dentition are uncommon. Both subtypes' clinical growth is often gradual and painless, and it is frequently accompanied by changes to either the permanent or deciduous dentition. The formation of fully differentiated epithelial and mesenchymal cells, which produce ameloblasts and odontoblasts, causes odontomas, which are developmental anomalies.¹⁸ They are typically asymptomatic, but regular radiography or an evaluation of the cause of a delayed tooth eruption reveal them.¹⁹ Males are slightly more likely to present with odontomas (59%) than females (41%).^{4,20,21} There is evidence that the complex odontome is more common in the maxilla (67%) than the mandible (33%), with the anterior maxillary region showing a clear preference (61%). Typically, these lesions are found during routine radiological exams (panoramic and/or intraoral X-rays) to determine the reason for delayed tooth eruption. Odontomas typically have one eye and several radiopaque, tiny tooth-

like features called denticles. However, they can also have the appearance of a dense radiopaque mass encircled by a narrow radiotransparent rim. Between the roots of erupted teeth or between the deciduous and permanent dentition is where the lesions typically develop.¹⁷ Odontomas are made up of several dental tissue formations such as enamel, dentin, cement, and occasionally pulpal structures. Histological analysis is used to confirm the diagnosis. A case of odontoma-dysphagia syndrome was reported by Thomas Ziebart in 2013, and the results and several observations suggest a role for FGF-3 and FGF-4 in tooth formation.²² The partial duplication of chromosome 11 in this family is assumed to be the source of the extremely rare odontoma-dysphagia syndrome, which resulted in increased function with higher dosages of FGF-3 and/or FGF-4. Odontome predominantly seen in syndromes for e.g SATB2-associated syndrome exhibiting multiple odontomas, Otodontal syndrome, Ekman-Westborg and Julin trait, Parry-romberg syndrome, Gardner's syndrome, Multiple odontogenic tumors.²³ The diagnosis is established on a clinical examination and radiographic pictures, and after surgical excision, a histological examination is required to confirm it. All other ossified bone lesions, such as ossifying fibroma, odontoameloblastoma, ameloblastic fibroma or fibro odontoma, osteoma and fibrous dysplasia; or florid osseous dysplasia, require differential diagnosis. For odontomas, Conventional surgery is seen to be the best option.²⁴ However, cutaneous and mucosal lesions have also been successfully treated with lasers.

4. Source of Funding

None.

5. Conflict of Interest

None.


References

1. Kharbanda OP, Saimbi CS, Kharbanda R. Odontome: A case report. *J Indian Dent Assoc.* 1986;58(6):269–71.
2. Bhaskar SN. Odontogenic tumors of jaws. In: and others, editor. *Synopsis of oral pathology.* US: Elsevier Mosby Year Book; 1986. p. 292–303.
3. Cawson RA, Binnie WH, Eveson JW. *Color Atlas of Oral Disease.* In: *Clinical and Pathological Correlations.* Hong Kong: Mosby-Wolfe; 1993. p. 6–19.
4. Shafer GW, Hine MK, Levy BM. *A textbook of oral pathology.* 4th ed. US, Philadelphia: WB Saunders; 1983. p. 308–11.
5. Shekar S, Roopa SR, Gunasheela B, Supriya N. Erupted Compound Odontome. *J Oral Maxillofac Pathol.* 2009;13(1):47–50.
6. Stajcic ZZ. Odontoma associated with a primary tooth. *J Pedod.* 1988;12(4):415–20.
7. Nelson BL, Thompson LDR. Compound odontoma. *Head Neck Pathol.* 2010;4(4):290–1.
8. Sreedharan S, Krishnan IS. Compound odontoma associated with impacted maxillary incisors. *J Indian Soc Pedod Prev Dent.* 2012;30(3):275–8.

9. Kannan KS, Prabhakar R. Composite compound odontoma-A case report. *J Clin Diagn Res.* 2013;7(10):2406–7.
10. Gloria L, Singer SR. Concomitant occurrence of cemental dysplasia and compound odontoma in anterior mandible: report of case. *J Orofac Sci.* 2010;2(2):37–40.
11. Kaban LB, Troulis MJ. Dentoalveolar surgery. Paediatric Oral and Maxillofacial Surgery. Philadelphia: Saunders. 2004;56(1):140.
12. Kannan KS, Prabhakar R. Composite compound odontoma- A case report. *J Clin Diagn Res.* 2013;7(10):2406–7.
13. Maltagliati A, Ugolini A, Crippa R, Farronato M, Paglia M, Blasi S, et al. Complex odontoma at the upper right maxilla: Surgical management and histomorphological profile. *Eur J Paediatr Dent.* 2020;21(3):199–202.
14. Philipsen HP, Reichart PA. Revision of the 1992-edition of the WHO histological typing of odontogenic tumours. A suggestion. *J Oral Pathol Med.* 2002;31(5):253–8.
15. Isola G, Ciccù M, Fiorillo L, Matarese G. Association between odontoma and impacted teeth. *J Craniofac Surg.* 2017;28(3):755–8.
16. Preoteasa CT, Preoteasa E. Compound odontoma-morphology, clinical findings and treatment. Case Report. *Rom J Morphol Embryol.* 2018;59(3):997–1000.
17. Satish V, Prabhadevi MC, Sharma R. Odontome: A Brief Overview. *Int J Clin Pediatr Dent.* 2011;4(3):177–85.
18. Altay MA, Ozgur B, Cehreli ZC. Management of a Compound Odontoma in the Primary Dentition. *J Dent Child (Chic).* 2016;83(2):98–101.
19. Maltagliati A, Ugolini A, Crippa R, Farronato M, Paglia M, Blasi S, et al. Complex odontoma at the upper right maxilla: Surgical management and histomorphological profile. *Eur J Paediatr Dent.* 2020;21(3):199–202.
20. Yassin OM. Delayed eruption of maxillary primary cuspid associated with compound odontoma. *J Clin Pediatr Dent.* 1999;23(2):147–9.
21. Owens BM, Sachuman NJ. Dental odontomas: a retrospective study of 104 cases. *Clin Pediatr Dent.* 1997;21(3):261–4.
22. Ziebart T, Draenert FG, Galetzka D, Babaryka G, Schmidseider R, Wagner W, et al. The original family revisited after 37 years: odontoma-dysphagia syndrome is most likely caused by a microduplication of chromosome 11q13.3, including the FGF3 and FGF4 genes. *Clin Oral Investig.* 2013;17(1):123–30.
23. Bueno NP, Bergamini ML, Elias FM, Braz-Silva PH. Unusual giant complex odontoma: A case report. *Oral Maxillofac Surg.* 2020;121(2):604–7.
24. Maltagliati A, Ugolini A, Crippa R, Farronato M, Paglia M, Blasi S, et al. Complex odontoma at the upper right maxilla: Surgical management and histomorphological profile. *Eur J Paediatr Dent.* 2020;21(3):199–202.

Author biography

A. Backiyalakshmi, Tutor

VC Divya, Associate Professor  <https://orcid.org/0000-0001-7042-6435>

Cite this article: Backiyalakshmi A, Divya VC. Compound odontome. *IP Int J Maxillofac Imaging* 2023;9(4):194-197.