

Content available at: <https://www.ipinnovative.com/open-access-journals>

IP International Journal of Maxillofacial Imaging

Journal homepage: <https://www.ijmi.in/>

Review Article

Retrograde peri implantitis – A case report with literature review

Sowmya Gujjar Vishnurao^{1*}, Madhusudan Astekar²¹Dept. of Oral Medicine & Radiology, Institute of Dental Sciences, Bareilly, Uttar Pradesh, India²Dept. of Oral & Maxillofacial Pathology, Institute of Dental Sciences, Bareilly, Uttar Pradesh, India

ARTICLE INFO

Article history:

Received 22-06-2024

Accepted 10-07-2024

Available online 27-07-2024

Keywords:

Periapical implant lesion

Apical periimplantitis

Retrograde periimplantitis

inflammatory periimplantitis lesion

ABSTRACT

Retrograde implant-related peri-implantitis (RPI), the apical part of an osseointegrated implant, which maintains good bone-to-implant contact in its coronal portion, is the sole part of the implant that is affected by peri apical lesion (IPL), a primary microbial inflammatory disease. Apical radiolucency and clinical symptoms are the main factors used to diagnose RPI. In the initial weeks following implant implantation, this disease may be upshot in implant failure if it is not identified and treated promptly. RPI has been linked to numerous etiologies, such as surgical trauma and preexisting microbial disease. Furthermore, a variety of techniques have been employed to categorize RPI according to various criteria. Up until now, it has been thought that the removal of defective implants and non-surgical and surgical treatment may effectively address RPI. In addition to providing important literature, this article explains the genesis, diagnosis, prevention, and treatment approaches of implant apical lesions and provides a case of implant periapical diseases. Additionally, we describe a rare instance of RPI in a 47-year-old female patient who experienced pain at the implant site in the posterior maxillary region.

This is an Open Access (OA) journal, and articles are distributed under the terms of the [Creative Commons Attribution-NonCommercial-ShareAlike 4.0 License](https://creativecommons.org/licenses/by-nc-sa/4.0/), which allows others to remix, tweak, and build upon the work non-commercially, as long as appropriate credit is given and the new creations are licensed under the identical terms.

For reprints contact: reprint@ipinnovative.com

1. Introduction

The infectious-inflammatory alternation around the implant apex known as retrograde peri-implantitis (RPI) eventually results in implant failure. For implantologists, it presents a diagnostic and therapeutic conundrum.¹ Although the exact causes of this illness are unknown, pathogens are undoubtedly involved in its etiology.² When McAllister et al. originally reported this in 1992, they displayed two submerged implants with periapical radiolucency.³ A year later, the lesion was described by Sussman and Moss as an inflammatory and infectious evolution of the tissue surrounding the implant apex.⁴ In the literature, IPL has been referred to by a variety of names, such as inflammatory implant periapical lesion, periapical implant pathology, early peri-implantitis, apical implantitis,

apical peri-implantitis, endodontic-implant pathology, and retrograde peri-implantitis.¹

RPI is reported to be prevalent in the literature between 0.26% to 9.9% of the time.⁵ Furthermore, new research indicates that the frequency of RPI is between 0.34 and 3.8%. The reported incidences for the maxilla and mandible were 0.28–5.8% and 0.42–2.7%, respectively. However, other research showed a high frequency in the maxillary premolar.⁶

Smoking, low bone amount and quality, and implant placement in posterior locations were statistically significant risks linked to early implant failure, according to the papers they reviewed; few of these studies, however, identified the associated risk factors.⁷ Antimicrobials, open-flap implant debridement & apical resection—which may involve apicoectomy of neighboring teeth afflicted by endodontia—are among the therapeutic options. Bone

* Corresponding author.

E-mail address: tamannamyangel@gmail.com (S. G. Vishnurao).

grafting or implant removal may also be considered.⁸

This case report's objective was to assess a singular instance of RPI that was observed in the maxillary right posterior arch area.

2. Case Report

A dental implant was placed in the maxillary right molar region of a 47-year-old female patient. There was no history of mandibular bone pathology. The patient began experiencing dull, ongoing pain five months after implant installation. The pain would not go away and would not go away with medications. A clinical intraoral examination revealed no fistula. A CBCT scan verified the radiolucent image's existence, which was first revealed by reconstructed panoramic, 3-dimensional (buccal view), and cross-sectional images irt 15 regions (Figures 1, 2 and 3). CBCT images showed well-defined radio-opaque bone implant irt 15 regions with peri apical well-defined, round to oval shaped radiolucency measuring approx. 3.3x4.3 mm in its greatest dimension suggestive of peri apical pathology. Adjacent teeth 15 & 16 were found to be obturated root canals with peri apical abscess. The patient was put on an antibiotic regimen and under regular observation. Additionally, the implant was removed because the pain persisted following the removal of the implant, and the pain subsided.

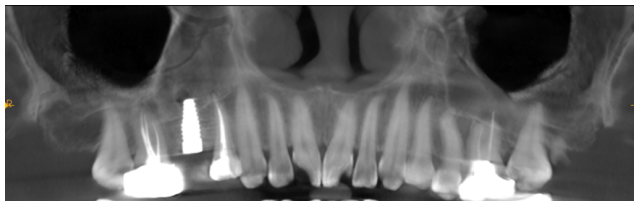


Figure 1: Reconstructed panoramic Image of maxillary arch

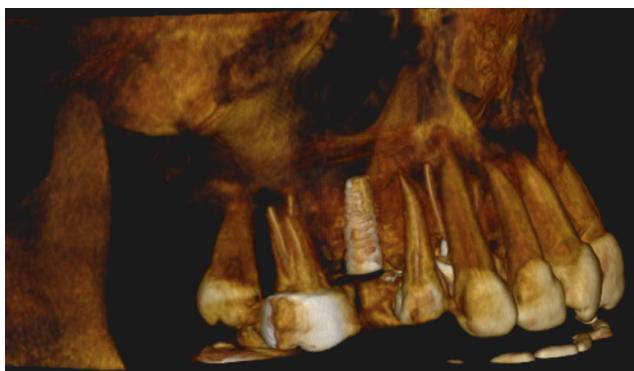

Figure 2: 3 dimensional image of right maxillary arch (buccal view)

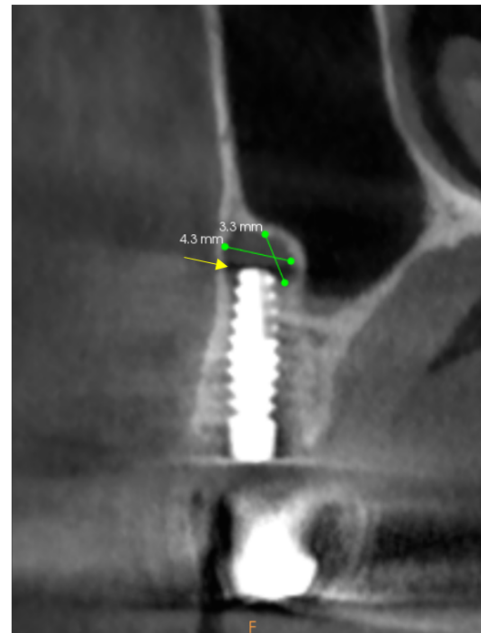


Figure 3: Cross-sectional image irt 15 region

3. Discussion

An accepted treatment option for replacing lost teeth is implant therapy.⁹ Several research has strongly supported the favorable long-term existence & success rate of implant therapy in general populations. Dental implants partake a high success percentage, however, there is a chance that they could cause infectious problems.¹⁰

The inflammation that develops in the apical peri-implant area is known as apical RPI, and it can lead to osseointegration loss or dental implant failure. Implant loss may result from untreated peri-implantitis.¹¹

Before abutment attachment, retrograde peri-implantitis was 2.7% more common in lower teeth and 1.6% more common in upper teeth, but it is not a common consequence of dental implant failure.^{11,12} When there has previously been root canal therapy performed on the teeth next to the implant site, the incidence of retrograde peri-implantitis is said to rise to 7.8%.¹³ In our case, the most likely reason was believed to be the nearby endodontically restored teeth.

3.1. Aetiology

RPI is well recognized to be a complex illness.¹⁴ Three cases of implant periapical lesions in patients whose apical surgery had failed before Ayangco and Sheridan documented implant implantation.¹⁵ Four implant failures were ascribed by Brisman et al. to the presence of neighboring endodontically treated teeth, which were asymptomatic and did not exhibit any radiographic indications of disease.¹⁶ Lastly, Balshi SF et al. proposed that this process has a multifactorial etiology, and they were

unable to support or refute any of the previously proposed theories.¹⁷

Table 1: Various etiological factors of RPI are listed below:^{2,4,18}

Patient-associated factors	Material-associated factors	Method-associated factors
1. Foreign body; 2. Endodontic lesion of the neighboring tooth 3. Residual root pieces; 4. Pre-existing bone pathology (e.g., residual cyst); 5. Poor bone quality; 6. Infected maxillary sinus; 7. Thin-bone loss owing to flap operation; 8. Bisphosphonate medication; 9. Smoking	1. Design of the plant surface and biocompatibility. 2. Different implant system techniques 3. Contaminated implant surface	1. Longer drilling length than the implant 2. Overheating of the bone 3. Over-compression of the bone 4. Vascular impairment/ischemia 5. Apical bone fenestration; increased closeness to neighbouring teeth; contamination of the implant site; socket shield technology; immediate implant; premature loading

3.2. Diagnosis

Radiography and clinic diagnosis are used to identify implant periapical lesions. Pain, swelling, suppuration, and fistula are possible symptoms and clinical indicators; in certain instances, an implant apical radiolucency might be seen on the radiograph.¹⁹

Implant periapical lesions were divided into two categories by Reiser and Nevins: dormant (or not infected) and active (or infected). The radiolucency surrounding the implant’s apex is what is used to diagnose the asymptomatic inactive variant. This radiolucency is an apical wound resulting from either bone necrosis from overheating during implant placement or straight-up overpreparation of the implant site.¹⁹ Treatment is not necessary for inactive lesions unless the radiolucency increases in size; in this case, radiographic management is necessary. After a lesion is in its active state, it is symptomatic and needs to be treated to stop the degeneration of the bone. Other symptoms such as gingival reddening, uncomfortable soft swollen mucosa, and, in certain situations, the existence of a fistulous tract, may also manifest in conjunction with periapical radiolucency.¹⁸ CBCT (cone beam computed tomography) or occlusal view radiographs are utilized to confirm mandibular RPI because the lesion may not always

be visible on periapical radiographs of the mandible.⁵

According to certain theories, retrograde periimplantitis and marginal periimplantitis are similar site-specific infectious diseases. However, the primary distinctions are found in the type of microorganisms present, how quickly they proliferate, and how the illness spreads.⁴ While microorganisms observed in retrograde periimplantitis have characteristics similar to endodontic pathogens, those initiated in periimplantitis stay strongly linked to periodontal pathogens. IPL contained actinomycotic colonies, *Corynebacterium*, *Technologies Klebsiella pneumoniae*, *Porphyromonas gingivalis*, *Enterococcus faecalis*, *Porphyromonas gingivalis*, and a variety of facultative and anaerobic bacteria. *Porphyromonas gingivalis* was the most common species, while *Candida albicans* was sporadically found.²⁰

Moreover, retrograde periimplantitis starts apically, whereas coronal periimplantitis occurs. Retrograde periimplantitis must be diagnosed by radiographic evaluation and patient complaint, but marginal periimplantitis can be identified clinically by routine probing.⁶

3.3. Treatment

The investigated articles on treating implant periapical lesions have employed amoxicillin, amoxicillin/clavulanate, metronidazole, and clindamycin as antibiotics.²⁸ Surgical access was necessary in certain case series that were published because the symptomatic or active lesions could not be controlled with antibiotics alone.²⁹ In their review, Romanos et al. concluded that using antibiotics by itself is ineffective. Infiltrative anesthesia, incision, full-thickness flap, osteotomy, apical curettage of granulation tissue, and copious irrigation are the surgical procedures involved.⁵

Following the removal of granulation tissue, some writers irrigate with chlorhexidine or sterile saline solution. There is no proof to support the effectiveness of any of the other substances that have been recommended for topical cleansing of the implant site, including tetracycline paste, calcium hydroxide paste, or chlorhexidine paste.¹⁴ According to certain research, bone regeneration materials may be used in conjunction with or instead of tissue regeneration barriers to accomplish total bone regeneration of the defect.¹⁹

Tozum TF³⁰ proclaimed the first report showing the concurrently efficacious action of the neighboring natural tooth and the periapical implant disease without the necessity to eradicate the implant. Balshi SF et al in 2007¹⁷ owing to the findings of this retrospective investigation, an intraoral apicoectomy method can be used to successfully treat lesions in the apical region of implants.

Four RPI cases are described by Rosendahl K et al.,³¹ the damaged area of a stable implant was sectioned and removed, and the surrounding granulomatous tissue was

Table 2: Classification: Different systems have been used to classify RPI as listed below²¹

Classified by/ Year	Based on	Types
1995 Reiser ²²	Activity of infection	<ol style="list-style-type: none"> 1. Active 2. Inactive
1998 Susman ²³	Endodontic Implant Pathology	<ol style="list-style-type: none"> 1. Type I – Implant to tooth - Occurs during osteotomy preparations, due to the placement of the implant at a shorter distance from the adjacent tooth, overheating of bone during the osteotomy, or direct trauma to a tooth root, cutting off the blood supply to the pulp; all of which result in tooth devitalization. 2. Type II – Tooth to Implant - Occurs after implant placement, when the adjacent tooth develops a periapical pathology, either by operative damage toward the pulp or by reactivation of a prior periapical lesion.
2006, 2012 Panarrocha Diago ²¹	Evolutionary stage	<ol style="list-style-type: none"> 1. Acute (2006) 2. Chronic (2006) 3. Sub-acute (2012)
2013 Khadkhodazadeh ²⁴	Peri implant, Periodontal and peri apical lesion	<ol style="list-style-type: none"> 1. Primarily periodontitis 2. Primarily peri-implantitis 3. Separately 4. Traumatic lesions
2016 Rucha Shah ²⁵ (Radiographic classification)	Involvement severity	<ol style="list-style-type: none"> 1. Bone loss/implant dimension 2. Class I - Extends <25% of the implant dimension from the implant apex (Mild) 3. Class II - 25–50% of the implant dimension from the implant apex (Moderate) 4. Class III - >50% of the implant dimension from the implant apex (Severe)
2017 Sarmast ²⁶	Classification of RPI	<ol style="list-style-type: none"> 1. Class 1 – implant placement induces devitalization of adjacent tooth 2. Class 2 – RPI by peri apical lesion of adjacent tooth/implant 3. Class 3 – implant apex outside envelope of bone 4. Class 4 – RPI due to residual infection at placement site.
2017 American Academy of Periodontology and the European Federation of Periodontology ²⁷		<ol style="list-style-type: none"> 1. Peri-implant health 2. Peri-implant mucositis 3. Peri-implantitis 4. Soft- and hard-tissue deficiencies

thoroughly debrided. All four cases showed success with this treatment up to four years after it began. This data also suggests that RPI is a very uncommon ailment that can develop at any point during implant therapy, in these cases as late as 4 months or up to 11 years after implant implantation.

Waasdorp J (2010)³² described a 53-year-old man who, upon implant implantation and instant previsualization (nonfunctional loading), acquired a radiolucency round the implant's apex in the mandibular incisor region. Four months after placement, during the last impression phase, the radiolucency was found. The apical portion of the implant was extensively involved, as shown by a cone-beam computed tomography scan. Over the following 12 months, the patient was put on an antibiotic regimen and under regular observation. Without receiving any additional care, the radiographic lesion progressively disappeared over the next nine months. Throughout the latter phase of restorative therapy, the patient did not experience any symptoms. This instance was comparable to the current one in that the symptoms were controlled and eliminated without the need for surgery using antibiotics.

In 2020, Murro BD et al.³³ sought to assess Italian implantologists' attitudes and knowledge about RPI by a cross-sectional survey. A survey in anonymity was emailed to randomly chosen implantologists. The study employed binomial logistic regression to scrutinize the correlation between the number of dental implants implanted annually, age, and years of experience, as independent factors, and the correct responses. Most participants could identify the symptoms and likely causes of RPI, but about 30% had very little understanding of the various management techniques that could be used.

3.4. Prognosis

The literature reports that 73.2% to 97.4% of the implants treated with a maximum follow-up of 4.5 years survive these lesions, indicating a good prognosis.

4. Conclusion

RPI is a frequent implication of dental implant placement. Given the uncertain results of the treatment, the clinician ought to be alert to both the prevention, correct diagnosis, and treatment of the disease. Re-evaluation exams are also important to prevent possible recurrences of the disease. To avoid any complications, it is necessary to thoroughly identify any potential sources of infection in the edentulous area of interest during the implantation planning stage.

5. Sources of Funding

None.

6. Conflict of Interest


None.

References

- Burdurlu M, Dagasan V, Tunç O, Güler N. Retrograde peri-implantitis: evaluation and treatment protocols of a rare lesion. *Quintessence Int*. 2021;52(2):112–21.
- Ramanauskaitė A, Juodzbalytė G, Tözüm TF. Apical/retrograde periimplantitis/implant periapical lesion: etiology, risk factors, and treatment options: a systematic review. *Implant Dent*. 2016;25(5):684–97.
- Lefever D, Assche NV, Temmerman A, Teughels W, Quirynen M. Aetiology, microbiology and therapy of periapical lesions around oral implants: a retrospective analysis. *J Clin Periodontol*. 2013;40(3):296–302.
- Chang LC. Implant periapical lesion: a narrative review. *Technologies*. 2021;9(3):65–77.
- Romanos GE, Froum S, Costa-Martins S, Meitner S, Tarnow DP. Implant periapical lesions: etiology and treatment options. *J Oral Implantol*. 2011;37(1):53–63.
- Dahlin C, Nikfarid H, Alsén B, Kashani H. Apical peri-implantitis: possible predisposing factors, case reports, and surgical treatment suggestions. *Clin Implant Dent Relat Res*. 2009;11(3):222–7.
- Sarmast ND, Wang HH, Soldatos NK, Angelov N, Dorn S, Yukna R, et al. A novel treatment decision tree and literature review of retrograde peri-implantitis. *J Periodontol*. 2016;87(12):1458–67.
- Bretz WA, Matuck AN, DeOliveira G, Moretti AJ, Bretz WA. Treatment of retrograde peri-implantitis: clinical report. *Implant Dent*. 1997;6(4):287–90.
- Henry PJ. Tooth loss and implant replacement. *Aust Dent J*. 2000;45(3):150–72.
- Howe MS, Keys W, Richards D. Long-term (10-year) dental implant survival: A systematic review and sensitivity meta-analysis. *J Dent*. 2019;84(1):9–21.
- Zarenti S, Tsompani G, Anastasopoulos M, Gousoulis T, Doufexi AE. Apical Peri-Implantitis: Etiology, Prevention, Diagnosis, Treatment: Literature Review and Case Report. *J Res Med Dent Sci*. 2021;9(6):1–6.
- Alssum LR, Alghofaily MM, Aleyiydi AS, Alomar SA, Alsalleeh FM. The Incidence of Retrograde Peri-Implantitis in a Single University Dental Hospital Training Center: A Retrospective Analysis. *Medicina (Kaunas)*. 2023;59(3):560–71.
- Murro BD, Canullo L, Pompa G, Murro CD, Papi P. Prevalence and treatment of retrograde peri-implantitis: a retrospective cohort study covering a 20-year period. *Clin Oral Investig*. 2021;25(7):4553–61.
- Temmerman A, Lefever D, Teughels W. Etiology and treatment of periapical lesions around dental implants. *Periodontol 2000*. 2014;66(1):247–54.
- Steiner DR. The resolution of a periradicular lesion involving an implant. *J Endod*. 2008;34(3):330–5.
- Luongo R, Faustini F, Vantaggiato A. Implant Periapical Lesion: Clinical and Histological Analysis of Two Case Reports Carried Out with Two Different Approaches. *Bioengineering (Basel)*. 2022;9(4):145–57.
- Balshi SF, Wolfinger GJ, Balshi TJ. A retrospective evaluation of a treatment protocol for dental implant periapical lesions: long-term results of 39 implant apicoectomies. *Int J Oral Maxillofac Implants*. 2007;22(2):267–72.
- Mohamed JB, Shivakumar B, Sudarsan S, Arun KV, Kumar TSS. Retrograde peri-implantitis. *J Indian Soc Periodontol*. 2010;14(1):57–65.
- Peñarrocha-Diago M, Maestre-Ferrín L, Cervera-Ballester J, Peñarrocha-Oltra D. Implant periapical lesion: diagnosis and treatment. *Medicina oral, patología oral y cirugía bucal*. *Med Oral Patol Oral Cir Bucal*. 2012;17(6):1023–7.
- Saleh MH, Khurshid H, Travan S, Sinjab K, Bushahri A, Wang HL. Incidence of retrograde peri-implantitis in sites with previous apical surgeries: A retrospective study. *J Periodontol*. 2021;92(1):54–61.

21. Shrestha R, Bhochhibhoya A. Peri-implantitis: A Classification Update. *Nepal J Health Sci.* 2021;1(2):52–62.
22. Reiser GM, Nevins M. The implant periapical lesion: etiology, prevention, and treatment. *Compend Contin Educ Dent.* 1995;16(8):768.
23. Sussman HI. Periapical implant pathology. *J Oral Implantol.* 1998;24(3):133–8.
24. Kadkhodazadeh M, Amid R. A new classification for the relationship between periodontal, periapical, and peri-implant complications. *Iran Endod J.* 2013;8(3):103–8.
25. Shah R, Thomas R, Kumar T, Mehta DS. Assessment of Intraobserver and Interobserver Agreement of a New Classification System for Retrograde Periimplantitis. *Implant Dent.* 2016;25(6):817–24.
26. Sarmast ND, Wang HH, Sajadi AS, Angelov N, Dorn SO. Classification and clinical management of retrograde peri-implantitis associated with apical periodontitis: a proposed classification system and case report. *J Endod.* 2017;43(11):1921–4.
27. Atieh MA, Alsabeeha NH. Peri-implantitis Through the Looking Glass. *Int Dent J.* 2024;74(1):42–5.
28. Ahmadi H, Ebrahimi A, Ahmadi F. Antibiotic therapy in dentistry. *Int J Dent.* 2021;2021(1):6667624.
29. Porenczuk A, Górski B. Peri-implantitis: A Serious Problem of Dental Implantology. In: *Advances in Dental Implantology using Nanomaterials and Allied Technology Applications.* Springer International Publishing; 2021. p. 181–223. doi:10.1007/978-3-030-52207-0_9.
30. Tözüm TF, Şençimen M, Ortakoğlu K, Ozdemir A, Aydın OC, Keleş M. Diagnosis and treatment of a large periapical implant lesion associated with adjacent natural tooth: a case report. *Oral Surg, Oral Med, Oral Pathol. Oral Surg Oral Med Oral Pathol Oral Radiol Endod.* 2006;101(6):132–8.
31. Rosendahl K, Dahlberg G, Kisch J, Nilner K. Implant periapical lesion. *Swed Dent J.* 2009;33(2):49–58.
32. Waasdorp J, Reynolds M. Nonsurgical treatment of retrograde peri-implantitis: a case report. *Int J Oral Maxillofac Implants.* 2010;25(4):831–3.
33. Murro BD, Pranno N, Raco A, Pistilli R, Pompa G, Papi P. Knowledge and attitude towards retrograde peri-implantitis among Italian implantologists: A cross-sectional survey. *Int J Environ Res Public Health.* 2020;17(22):8356–65.

Author biography

Sowmya Gujjar Vishnurao, Professor  <https://orcid.org/0000-0002-6441-0426>

Madhusudan Astekar, Professor & Head

Cite this article: Vishnurao SG, Astekar M. Retrograde peri implantitis – A case report with literature review. *IP Int J Maxillofac Imaging* 2024;10(2):42–47.