

Content available at: <https://www.ipinnovative.com/open-access-journals>

IP International Journal of Maxillofacial Imaging

Journal homepage: <https://www.ijmi.in/>

Case Report

Removal of osteoma from the forehead area via standard bicoronal approach, and restoration of the cavity with radiopaque bone cement polymethyl methacrylate, which is usually used to fix pathological fractures of the vertebral body

Mohamad Ayham Manafikhi^{1,2*}, Andrey Alekseevich Orlov^{1,2}

¹Dept. of Maxillofacial Surgery and Surgical Dentistry, Peoples' Friendship University of Russia, Moscow, Russia

²AO GK MEDSI Clinics Network, Clinical and Diagnostic Center, Moscow, Russia



ARTICLE INFO

Article history:

Received 20-05-2024

Accepted 04-06-2024

Available online 27-07-2024

Keywords:

Radiopaque bone cement

Peripheral osteomas

Craniomaxillofacial

Polymethyl methacrylate

ABSTRACT

Osteomas are benign, slow-growing tumors that arise most frequently in the craniomaxillofacial region. Osteomas may be asymptomatic for a long time until they cause deformation of the bone or compress adjacent structures. Peripheral osteomas arise from the periosteum. Patient, a 44-year-old woman, had a bone tumor in the frontal bone on the left side, noticed 23 years ago. After conducting all examinations and pre-operative preparation, the operation was performed under general anesthesia, the bone tumor was removed and the cavity resulting from the removal of the bone tumor was restored, using radiopaque bone cement polymethyl methacrylate, which is usually used to fix pathological fractures of the vertebral body. After the first operation, a second procedure was performed, a facelift in the middle area of the face. The patient's condition in the days after the operation was good. She did not experience any immune reaction or infection. The cosmetic result and symmetry are at its best. The results of repairing shallow open bone defects, especially in the frontal bone, with bone cement have not been reported or studied yet.

This is an Open Access (OA) journal, and articles are distributed under the terms of the [Creative Commons Attribution-NonCommercial-ShareAlike 4.0 License](https://creativecommons.org/licenses/by-nc-sa/4.0/), which allows others to remix, tweak, and build upon the work non-commercially, as long as appropriate credit is given and the new creations are licensed under the identical terms.

For reprints contact: reprint@ipinnovative.com

1. Introduction

Osteomas are benign, slow-growing tumors that arise most frequently in the craniomaxillofacial region.¹ One study reported that the frontal bone was the most common site of presentation of peripheral osteomas, followed by the mandible and maxilla.² Histopathologically, osteomas are characterized by 3 subtypes, as compact or ivory (composed of normal dense bone and scattered bone marrow spaces), cancellous (predominated by trabeculated bone and abundant fibroadipose marrow) and a mixed pattern (showing both histological features).³ Osteomas may be asymptomatic for a long time until they cause deformation of the bone or compress adjacent structures.¹ The clinical

signs depend on the size and location of the tumor, as well as the direction of its growth. Morphologically, they are similar to common osseous tissue. They are classified as central, peripheral, or extra skeletal. Central osteomas develop from the endosteum. Peripheral osteomas arise from the periosteum, and extra skeletal soft tissue osteomas grow within a muscle.⁴ The incidence of osteoma of the frontal bone and frontal sinus ranges from 37-80% in the reported cases. But isolated cases of osteoma of the forehead, without involvement of the sinus, are rare.⁵ There are numerous options available for surgical removal of a forehead osteoma. The endoscopic approach for treating forehead osteomas is less invasive and facilitates complete removal of tumors, which results in good cosmetic outcomes.⁶ The anterior hairline approach with subcutaneous dissection is an effective method for removal of forehead osteoma since it

* Corresponding author.

E-mail address: manafikhiayham@gmail.com (M. A. Manafikhi).

offers broad visualization and hides the scar in the hairline. In addition, the dissection in the subcutaneous plane avoids inadvertent injury to the deep nerve branches and helps to maintain scalp sensation.⁷ In our article, we present the case of forehead osteoma removed by bicoronal (bitemporal) incision in the scalp. It was used because it is hidden, has the most aesthetic outcomes, and it offers broad visualization. The goal was to completely remove the tumor to prevent recurrence and to restore the resulting cavity.

2. Case Report

A 44-year-old woman had a bone tumor in the forehead bone on the left side, noticed 23 years ago. It is round and raised on the bone, not painful, but aesthetically annoying. The surgical goal was to restore the normal appearance of the patient's face and to exclude any possibility of recurrence in the future. After conducting a clinical examination, palpation, and taking a medical history, the patient was sent to make a computed tomography (CT) scan of the head (Figure 1 A-D). In radiological study, the tumor was seen and measured, a base diameter of 23.1 mm and a height of 6.44 mm (Figure 1 D), it arises from the outer side of the cortical layers of the frontal bone on the left side, no swelling, no compression on the brain. Compared with a patient's CT scan of 2014, we observe the same dimensions, without negative dynamics. The patient was informed about the risks of the surgical procedure, the possibility of entering the cerebral system, and the potential complications of meningitis and cerebrospinal fluid leakage. All pre-operative procedures, including tests and examinations, were carried out. The surgery was performed under general anesthesia with nitrous oxide gas and oral intubation. A complete coronal incision was made, and the layers of skin were dissected from the incision to the front, reaching the area of the bone tumor. The area of the bone tumor was completely exposed (Figure 2 A). The bone tumor was removed using piezosurgery (Figure 1 B), a hammer, and a chisel (Figure 2 C). The bone tumor was completely removed up to the inner bony cortex of the frontal bone, and the dura mater in the center of the cavity was exposed approximately 4 mm (Figure 2 D). The cavity resulting from the removal of the bone tumor was restored using radiopaque bone cement polymethyl methacrylate (PMMA) which is usually used to fix pathological fractures of the vertebral body (Figure 3 A). PMMA is generally considered to be a safe and non-toxic material. On October 14, 1999, FDA issued an order reclassifying the polymethylmethacrylate (PMMA) bone cement from class III (premarket approval) into class II (special controls). The used bone cement consists of a sterile liquid and a powder. The liquid component which is a colorless liquid monomer (Methyl methacrylate, N, N-dimethylparatoluidine, Hydroquinone) and the powder component (Polymethylmethacrylate " including Benzoyl

Peroxide", Barium Sulfate) was mixed forming a polymer form that resembles a thick, viscous mass. The bone was restored with this mass and was shaped to give a symmetrical and nearly correct anatomical shape. Working time was approximately 10 minutes, set time of 10.2 minutes at 37°C. The bone cement waited to harden, and then the formed surface was modified and smoothed by physio dispenser to obtain symmetry on both sides of the forehead and correct anatomical shape (Figure 3 B, C). After this procedure, and at the patient's request, a cosmetic midface lift was performed by extending the incision on both sides to the area just in front of the ears. Then sutures and surgical staples were placed in the scalp area. The incisions in front of the ear were sutured with subcuticular stitches. During the surgical procedure, the surgical flap was flipped back to its place every ten minutes and moistened with saline solution to ensure blood supply and prevent the flap necrosis. During the surgery, corticosteroid and antibiotics were infused intravenously.

The first day after the operation, the patient is in good condition, no fever, no immune reaction at the place of the bone cement and around it, there is no inflammation, the face is symmetrical and the forehead is symmetrical, generalized edema in the face. The patient is wearing a postoperative headband. On the fifth day of surgery, the patient is in good and stable condition, absence of facial edema by 85%. The patient gave an interview on YouTube to tell her story about the bone tumor. Histology report: Fragments of dense compact lamellar bone tissue, cortical type with small rounded Haversian canals, without signs of atypia, a few small osteocytes - a picture of osteoma. In computed tomography there is no immune reaction, there is no intracranial or extracranial bleeding or leakage (Figure 4). On the fourteenth day, the patient is in stable condition, absence of edema, the surgical staples were removed under intravenous sedation. The patient was informed of the necessary follow-up examinations in a month, three months, six months, and a year.

3. Discussion

In this case, we had several surgical options, each of them has pros and cons. The option of removing the tumor by endoscopy does not give the ability to completely remove it, which may lead to recurrence in the future. To prevent recurrence, it is essential to conduct additional meticulous burring and a thorough inspection of the surface after copious irrigation.⁸ Removing the tumor without restoring the area would lead to an unaesthetic appearance of a hollow in the forehead. Reconstruction with bone graft products will be lost, these products have poor stability in open places, especially in an area with strong muscle tension and movement. Reconstruction with autograft or allograft requires stabilization with screws, then a second operation to remove them. However, it is difficult to shape it into the

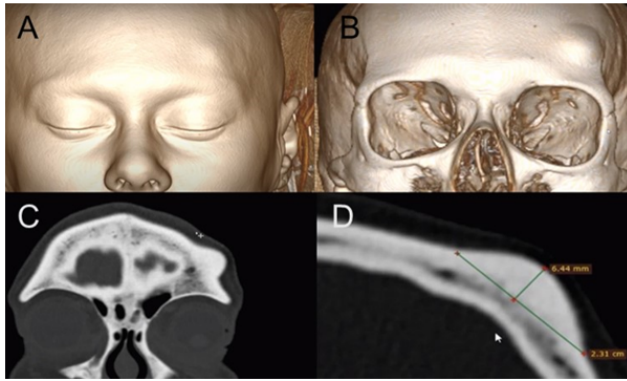


Figure 1: Radiological evaluation of the tumor. (A): 3D CT soft tissue surface. (B): 3D CT skull surface. (C): CT Coronal section showing the tumor. (D): CT horizontal section showing tumor measurements

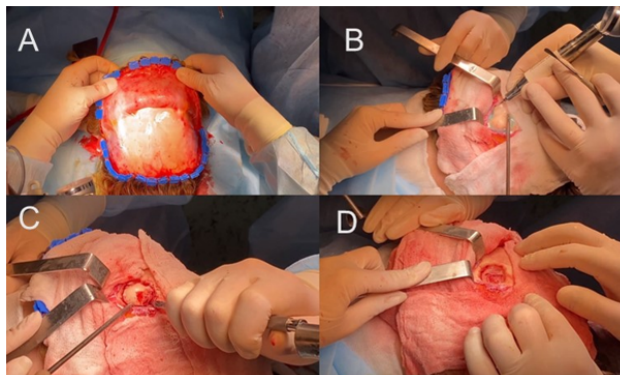


Figure 2: Pictures from the surgical procedure. (A): Elevation of the coronal flap and exposure of the tumor. (B): Drilling the tumor boundaries using piezosurgery. (C): Using surgical hammer and chisel. (D): Cavity resulting

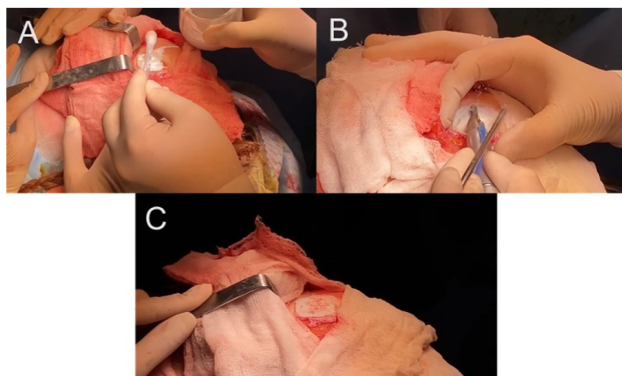


Figure 3: Bone restoration. (A): Filling the cavity with the (PMMA) cement. (B): Surface reduction and modeling. (C): The result after modeling

Table 1: Glossary

Asymptomatic	Presenting no symptoms or evidence of illness or abnormality
Morphologically, [N]morphology	The branch of biology dealing with the form and structure of organisms
Peripheral	Connected with the outer edge of a particular area
Periosteum	The normal investment of bone, consisting of a dense, fibrous outer layer, to which muscles attach, and a more delicate, inner layer capable of forming bone
Nitrous oxide gas	A colorless, sweet-smelling, sweet-tasting, nonflammable, slightly water-soluble gas, N ₂ O, that sometimes produces a feeling of exhilaration when inhaled, used chiefly as an anesthetic in dentistry and surgery, in the manufacture of chemicals, and as an aerosol
Subcuticular sutures	Intradermal stitches (placed immediately below the epidermal layer)
https://www.dictionary.com https://www.oxfordlearnersdictionaries.com	

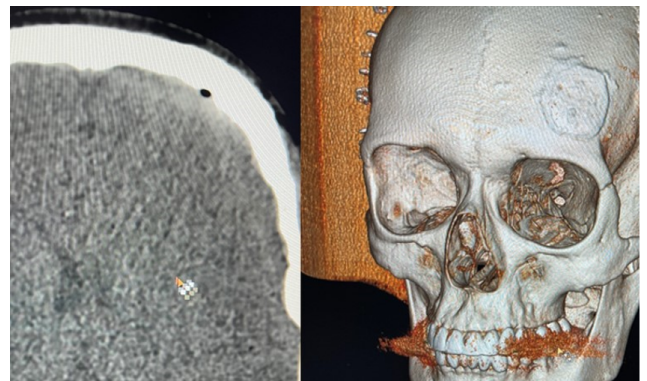


Figure 4: CT scan on the second day after surgery

resulting cavity. In reconstruction using metal plates with or without bone graft, the patient will undergo a second surgery to remove the plate, in addition to the uncomfortable feeling that the patient may experience due to the thin skin over the plate. Therefore, restoration using bone cement was chosen, noting that the recent results are not clear. But according to studies it can turn into cartilage tissue and then bone tissue. During 58 months of follow-up, the average VAS was 1.8, and no postoperative complications occurred during the follow-up period.⁹

4. Conclusion

There have not been sufficient studies to prove the effectiveness of the PMMA cement in bone especially in areas which are not subject to mechanical stress, that's why

further investigations are necessary. However, our results are optimistic. In the future, if it is fully studied, it will be a solution to many problems within certain parameters.

5. Ethics Approval and Consent to Participate

Informed consent was obtained from the patient for publication of this case report and the accompanying images.

6. Sources of Funding

This article received no external funding.

7. Conflict of Interest

The authors have no conflicts of interest to declare.

Acknowledgments

I would like to extend my sincere thanks to Platonova Natalya Vladimirovna (Assistant Professor of the Department of Latin and Foreign Languages of Krasnoyarsk State Medical University named after Prof. V.F. Voino-Yasenetsky, Krasnoyarsk, Russian Federation) for her help in reviewing and revising the manuscript for grammar and syntax.

References


1. Boffano P, Zavattoni E, Rocca F, Ramieri G. Open surgical management of an asymptomatic giant frontal sinus osteoma. *Craniofacial Trauma Reconstr.* 2014;7(1):51–4.
2. Sayan NB, Uçok C, Karasu HA, Günhan O. Peripheral osteoma of the oral and maxillofacial region: A study of 35 new cases. *J Oral*

Maxillofac Surg. 2002;60(11):1299–1301.

3. Toner M, Allen CM, Castle J. Benign maxillofacial bone and cartilage tumours. In: WHO Classification of Head and Neck Tumours. Lyon: IARC; 2017. p. 246.
4. Bodner L, Gatot A, Sion-Vardy N, Fliss DM. Peripheral osteoma of the mandibular ascending ramus. *J Oral Maxillofac Surg.* 1998;56(12):1446–9.
5. Shanavas M, Chatra L, Shenai P, Veena KM, Rao PK, Prabhu RV. Multiple Peripheral Osteomas of Forehead: Report of a Rare Case. *Ann Med Health Sci Res.* 2013;3(1):105–7.
6. DaCosta DS, Suzuki FS, Biló JP, Cavalheiro S. Endoscopic Approach for Resection of Frontal Forehead Osteoma: Technical Case Report Instruction. *World Neurosurg.* 2023;175:11.
7. Kim JS, Lee JH, Kim N, Lee KS. Forehead Osteoma Excision by Anterior Hairline Incision with Subcutaneous Dissection. *Arch Craniofac Surg.* 2016;17(1):39–42.
8. Lee DY, Lim S, Yoon JS, Eo S. Recurred forehead osteoma disseminated after previous osteoma excision: A case report. *World J Clin Cases.* 2023;11(31):7684–9.
9. Wang Q, Dong JF, Fang X, Chen Y. Application and modification of bone cement in vertebroplasty: A literature review. *Jt Dis Relat Surg.* 2022;33(2):467–78.

Author biography

Mohamad Ayham Manafikhi, Resident Surgeon
 <https://orcid.org/0009-0003-2379-1992>

Andrey Alekseevich Orlov, Professor (Maxillofacial Surgeon)
 <https://orcid.org/0009-0008-6200-4839>

Cite this article: Manafikhi MA, Orlov AA. Removal of osteoma from the forehead area via standard bicoronal approach, and restoration of the cavity with radiopaque bone cement polymethyl methacrylate, which is usually used to fix pathological fractures of the vertebral body. *IP Int J Maxillofac Imaging* 2024;10(2):64–67.