

## Typical Radiographic Presentation of Multiple Myeloma: report of 2-cases with review of literature

Kotya Naik Maloth<sup>1,\*</sup>, Kundoor Vinay Kumar Reddy<sup>2</sup>, Sri Sai Lakshmi Preethi Vishnumolakala<sup>3</sup>, Venkata Satya Ramesh Thummala<sup>4</sup>, Kesidi Sunitha<sup>5</sup>, Moni Thakur<sup>6</sup>

<sup>1,5</sup>Senior Lecturer, <sup>2</sup>Professor & Head, <sup>3</sup>PG Student, <sup>4</sup>Reader, Dept. of Oral Medicine & Radiology, <sup>6</sup>Senior Lecturer, Dept. of Oral & Maxillofacial Pathology, Mamata Dental College & Hospital, Khammam

**\*Corresponding Author:**

Email: dr.kotyanaik.maloth@gmail.com

### Abstract

Multiple Myeloma [MM] is a rare monoclonal malignant proliferation of plasma cells in the bone marrow that results in osteolytic lesions in the vertebrae, ribs, skull and jaw with typical presentation of “punched out” in appearance. It occurs more frequently in males with an average age of 60 years. Here we report such peculiar 2 cases with typical radiographical presentation of the lesion involving multiple bones with variable serological presentations.

**Keywords:** Clonal proliferation, Plasma cells, Plasmacytoma.

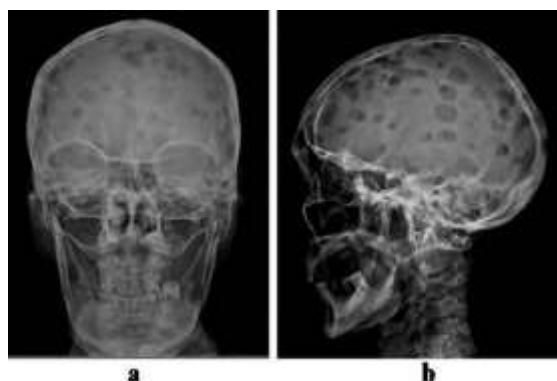
### Introduction

Multiple Myeloma [MM] is a rare malignant hematological disease, characterized by multicentric proliferation of plasma cells in the bone marrow resulting in osteolytic lesions.<sup>1</sup> MM represents approximately 1% of all cancers and 10% of all hematological neoplasms.<sup>2,3</sup> Its rate of occurrence is higher in African Americans and lower in Asian population, with a male predominance at a mean age of about 60 years.<sup>2</sup> The common clinical findings are persistent pain in the bone at the affected region, a history of fever, recurrent infection, fatigue and hematological alterations can be noted.<sup>1</sup> Here we report 2-cases of MM with typical radiographic features and variable serological findings.

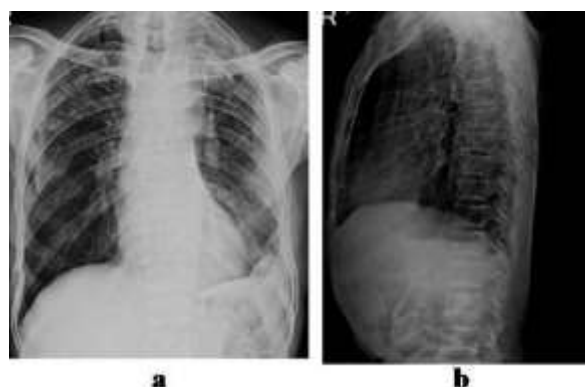
### Case 1

A 70 year old male patient reported to the department with a chief complaint of loose teeth in the lower left back tooth region, since 15-days. Patient also complains of pain in the bones since 6-months and weight loss. On general physical examination, he was thin built and undernourished. The investigatory work-up included Complete blood count, which revealed decreased RBC count, decreased WBC count and decreased platelet-count with normocytic normochromic anemia. Further biochemical investigations were advised which revealed increased ESR, hypocalcaemia, increased blood urea nitrogen (BUN), Creatinine levels, and increased protein levels in urine which were confirmed as Bence Jones's protein. [Table 1] Serum electrophoresis was performed which revealed increased myeloma protein (M-protein) with increased Immunoglobulin G [IgG]. Radiographic examinations such as PA-Skull and lateral skull revealed extensive well-defined “punched out” osteolytic lesions (Fig. 1). Similar punched out osteolytic lesions were seen on ribs and vertebrae (Fig.

2). Based on the laboratory and radiographic findings, it was diagnosed as multiple myeloma.



**Fig. 1a and 1b: PA-skull and Lateral skull showing multiple “punched out” radiolucencies**



**Fig. 2a and 2b: chest radiograph and lateral spine radiograph showing multiple osteolytic lesions**

### Case 2

A 50 year old male patient with similar features reported to the department with a chief complaint of burning mouth while taking spice foods, since 5-years.

All laboratory findings (Table 1) were positive for multiple myeloma and radiographic examination of lateral skull and vertebrae revealed well defined punched out osteolytic lesions. (Fig. 3, 4)

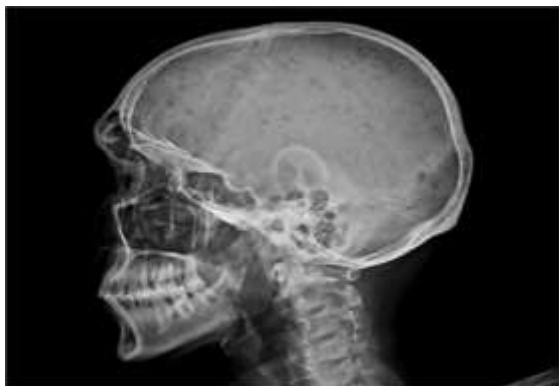


Fig. 3: Lateral skull showing multiple “punched out” radiolucencies

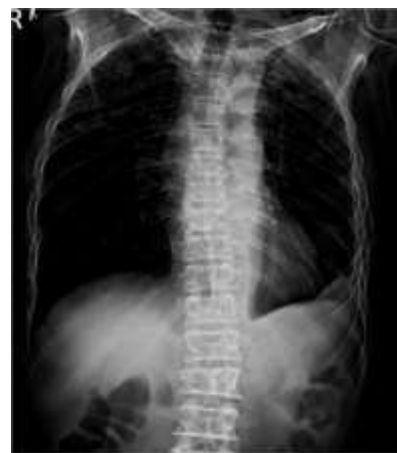

Fig. 4: PA spine radiograph showing multiple osteolytic lesions

Table 1: Values of Complete Blood Count (CBC), chemistry measures and serum protein electrophoresis

Count	Results		Normal Range
	Case 1	Case 2	
Red Blood Cells	1.12 mil/mm <sup>3</sup>	3.29 mil/mm <sup>3</sup>	4.5-5.0 mil/mm <sup>3</sup>
Hemoglobin	4.1 gm%	7.6 gm%	13-15gm%
Platelets	90,000/mm <sup>3</sup>	1,30,000/mm <sup>3</sup>	1.5- 4.5 lak/mm <sup>3</sup>
Creatinine	2.8 mg/dl	2.3 mg/dl	0.5-1.5 mg/dl
Calcium	7.5 mg/dl	13 mg/dl	8.7-11.0 mg/dl
Lactate Dehydrogenase	150 U/L	166 U/L	30-200 U/L
Gamma globulins	4.30 g/dl	3.26 g/dl	0.7-1.8 g/dl
Blood Urea Nitrogen	72 mg/dl	65 mg/dl	15-40 mg/dl

Table 2: Diagnostic Criteria for Multiple Myeloma

Criteria for diagnosis of Multiple Myeloma. The diagnosis requires a minimum of one major and one minor criterion, or 3 minor criteria which must include 1 and 2 criteria. <sup>7</sup>	
Major criteria:	1- Marrow plasmocytosis $\geq$ 30%. 2- Plasmacytoma on biopsy. 3- M component: – Serum IgG $\geq$ 3.5g/dl; IgA $\geq$ 2g/dl. – Urine Ig/24hours of Bence Jones protein.
Minor criteria:	1- Marrow plasmocytosis of 10-30%. 2- M component present but less than in major criteria. 3- Lytic bone lesions 4- Reduced normal serum immunoglobulins ( $\leq$ 50% of normal)

## Discussion

Multiple myeloma is a neoplastic disorder of plasma B-cells characterized by bone marrow infiltration and proliferation of monoclonal immunoglobulins. The first case of MM was documented by Samuel Solly in 1844<sup>4</sup> and the term "Multiple Myeloma" was introduced by J von Rustizky in 1873.<sup>2</sup> MM is more frequent in elderly individuals with a mean age of 60 years with male predominance, occurs in disseminated form affecting multiple bones<sup>2,5</sup> as in the cases reported here.

The exact etiology remains unknown, but few suggested etiological factors are exposure to certain chemicals, radiation overdose, certain occupations, viruses and genetic factors. The common systemic symptoms include bone pain, renal failure, hypercalcemia, weight loss, fatigue, weakness, shortening of the spine, fever, thrombocytopenia, neutropenia, orthostatic hypotension and infections.<sup>3</sup> Kyle RA<sup>6</sup> reported in his review of 869 patients, initial findings were bone pain 58%, anemia 62%, renal disorder 55%, hypercalcemia 30%, palpable liver 21%, and palpable spleen 5%. The case 1 diagnosed here was associated with bone pain, renal disorder, hypocalcaemia, weight loss, fatigue, weakness, shortening of the spine, fever, anemia, thrombocytopenia, neutropenia and infections, whereas in case 2 bone pain, hypercalcemia, weight loss, fatigue, anemia, thrombocytopenia, neutropenia and infections were noted.

The diagnosis of MM may be established by laboratorial tests including hematologic, biochemical findings, urine analysis and skeletal radiographic survey. Laboratorial tests for MM usually reveal anemia (73%), thrombocytopenia (5%), normal creatinine value (52%) and high serum levels of  $\beta$ -2 microglobulin (75%) indicates, one of the most powerful prognostic factors.<sup>3</sup> These laboratorial results were positive in both the cases. Hypercalcemia is also a regular feature, although was not detected in case 1 and increased creatinine levels were observed in both the cases. 93% of the MM cases show myeloma protein (M-protein) on serum electrophoresis and 70% of cases secrete immunoglobulin G with kappa light chains.<sup>3</sup> In both the cases, serum protein electrophoresis showed an IgG monoclonal spike.<sup>2</sup>

Radiographically osteolytic lesions with "punched out" in appearance (60%) are frequently seen in 79% of the MM cases, and it may occur due to osteoclastic activation by cytokines, increase in osteoclast numbers in areas invaded by malignant plasma cells and inhibiting bone formation. The most common involved sites are the vertebrae, skull, pelvic bones, ribs, humerus, and femur.<sup>2</sup> Radiographic examination of the present cases revealed well-defined "punched out" osteolytic lesions of the vertebrae, skull and ribs, in agreement with previous studies.

Both the cases fulfill the diagnostic criteria of MM, which includes one major criteria-3 and two minor criteria-3 & 4. (Table 2)

Based on the clinical stage of MM, Durie and Salmon<sup>8</sup> proposed a staging system and divided into three types (stage I, II and III) by assessing four measurements: 1) hemoglobin value 2) M-protein value 3) number of osteolytic lesions 4) serum calcium level. Stages are further sub-divided into two types (A, B) based on renal function (creatinine value). Both the cases were diagnosed as stage III B since renal involvement was present.

All the treatment modalities for MM are not curative, it only prolongs overall survival, which consists of chemotherapy followed by autologous stem-cell transplantation for younger patients and in addition, radiation therapy used only as a palliative care for painful bony lesions.<sup>9</sup> The factors which determine the prognosis are clinical stage of the lesion, age of the patient, renal involvement, thrombocytopenia, plasma cell leukemia and Bence Jones proteinuria.<sup>1</sup> In the present cases the above factors were confirmed, suggestive of poor prognosis.

## Conclusion

Every oral physician should be aware of the clinical manifestations, typical radiographical presentation and importance of laboratory investigation for early diagnosis of MM for better prognosis.

## References

1. Vieira-Leite-Segundo A, Lima-Falcao MF, Correia-Lins-Filho R, Marques-Soares MS, Lopez-Lopez J, Chimenos-Kustner E. Multiple Myeloma with primary manifestation in the mandible: A case report. *Med Oral Patol Oral Cir Bucal*. 2008;13(4):E232-4.
2. Kyle RA, Gertz MA, Witzig TE, Lust JA, Lacy MQ, Dispenzieri A et al. Review of 1027 patients with newly diagnosed multiple myeloma. *Mayo Clin Proc* 2003;78:21-33.
3. Pinto LSS, Campagnoli EB, Leon JE, Lopes MA, Jorge J. Maxillary lesion presenting as a first sign of multiple myeloma: Case report. *Med Oral Patol Oral Cir Bucal* 2007;12:E344-7.
4. Sachindanandan MK, Manoharan S, Rajaram K, Palanisamy MK, Soundarapandi P, Elumalai C. Multiple Myeloma: Report of a very rare case and review. *J Indian Aca Oral Med Radiol* 2012;24(1):91-94.
5. Chindia ML, Riyat MS, Nyongo A. Multiple myeloma presenting as a painful mandibular swelling: a case report. *Dent Update* 2001;28(5):258-60.
6. Kyle RA. Multiple myeloma: review of 869 cases. *Mayo Clin Proc* 1975;50:29-40.
7. Bayer-Garner IB, Prieto VG, Smoller BR. Detection of clonality with kappa and lambda immunohistochemical analysis in cutaneous plasmacytomas. *Arch Pathol Lab Med* 2004;128:645-8.
8. Durie BGM, Stock-Novack D, Salmon SE, Finley P, Beckord J, Crowley J et al. Prognostic Value of Pretreatment Serum-2 Microglobulin in Myeloma: A Southwest Oncology Group Study. *Blood* 1990;75:823-30.

9. Ozdemir R, Kayiran O, Oruc M, Karaaslan O, Kocer U, Ogun D. Plasmacytoma of the hard palate. *J Craniofac Surg* 2005;16:164-9.