

Content available at: <https://www.ipinnovative.com/open-access-journals>

IP International Journal of Maxillofacial Imaging

Journal homepage: <https://www.ijmi.in/>

## Case Report

# Non-incised papillae surgical approach (NIPSA): A new technique for the treatment of deep intrabony defect: A case report

Sharashchandra M Patil<sup>1\*</sup>, Swasthik Kalluraya B<sup>1</sup>, Anjali Chambole<sup>1</sup>, Uzma Tarannum<sup>1</sup>, Farah Naaz<sup>1</sup>, Indirapriyadarshini<sup>1</sup>

<sup>1</sup>Dept. of Periodontology and Oral Implantology, S B Patil Institute for Dental Sciences and Research, Bidar, Karnataka, India



### ARTICLE INFO

#### Article history:

Received 28-07-2024

Accepted 22-08-2024

Available online 03-10-2024

#### Keywords:

Deep intrabony defect. Minimally invasive

Non- incised papillae

Periodontitis

Periodontal regenerative therapy

### ABSTRACT

**Background:** Periodontal regenerative therapy aims at the recovery of lost periodontal tissue due to disease. The management of intrabony defects in periodontal disease remains a significant clinical challenge, often requiring intricate surgical interventions. This study presents the Non-Incised Papilla Surgical Approach (NIPSA) as an innovative technique for effectively treating intrabony defects while preserving soft tissue architecture.

**Case Report:** The aim of this case report on the Non-Incised Papillae Surgical Approach (NIPSA) technique is to effectively treat intrabony defects in periodontal therapy while minimizing surgical trauma and preserving soft and hard tissue architecture. NIPSA aims to achieve periodontal regeneration and clinical attachment gain through a minimally invasive approach, reducing patient discomfort and promoting predictable long-term outcomes. This case highlights the efficacy and patient satisfaction associated with the NIPSA technique in managing deep intrabony defects using bovine bone grafts.

**Results:** The outcome of this case resulted in post-operative healing was uneventful, with minimal discomfort reported by the patient. At the six-month follow-up, clinical examination revealed a significant clinical attachment gain, reduction in probing depth, and mobility, with no bleeding on probing. Radiographic evaluation demonstrated evidence of bone fill within the defect, indicating successful periodontal regeneration.

**Conclusion:** This case report offers a viable alternative for managing intrabony defects, providing effective treatment outcomes with minimal surgical trauma and enhanced patient satisfaction. Further research and long-term follow-up studies are needed to validate the efficacy and durability of this approach in periodontal therapy.

This is an Open Access (OA) journal, and articles are distributed under the terms of the [Creative Commons Attribution-NonCommercial-ShareAlike 4.0 License](https://creativecommons.org/licenses/by-nc-sa/4.0/), which allows others to remix, tweak, and build upon the work non-commercially, as long as appropriate credit is given and the new creations are licensed under the identical terms.

For reprints contact: [reprint@ipinnovative.com](mailto:reprint@ipinnovative.com)

## 1. Introduction

Intraosseous defects are sequelae of periodontitis and, if left untreated, may significantly affect the long-term success of the defect in teeth.<sup>1</sup> The most conventional surgical approach to treating intrabony defects uses a marginal detachment.<sup>2</sup> Periodontal surgery results in pocket probing depth reduction and elimination of osseous defects and

may also be associated with considerable loss of papilla, postoperative pain, hypersensitivity, and delayed healing.<sup>3–5</sup>

Cortellini et al. proposed a technique to minimize surgical trauma and postsurgical complications.<sup>6</sup> A minimally invasive procedure, termed the Non-Incised Papillae Surgical Approach (NIPSA), was designed to maintain the integrity of the interdental soft tissues covering intrabony defects and improves treatment outcomes.<sup>7</sup>

The basic principle of the technique is the placement of only one buccal horizontal incision in the mucosa, as

\* Corresponding author.

E-mail address: [drsharad\\_004p@yahoo.co.in](mailto:drsharad_004p@yahoo.co.in) (S. M. Patil).

apically as possible from the periodontal defect and the marginal tissues, and the raising of a mucoperiosteal flap coronally, which allows apical access to the defect but leaves the marginal tissues intact. This technique prevents biomaterial exposure.<sup>8</sup>

Bone grafting is a procedure to increase bone formation. An organic bovine bone is a xenograft that has a chemical composition similar to human bone and is considered an osteocompatible grafting material that acts as a bone-promoting substance.<sup>9</sup>

Hence, this case report presents the effectiveness of an intrabony defect treated with the NIPSA technique using a bone graft.

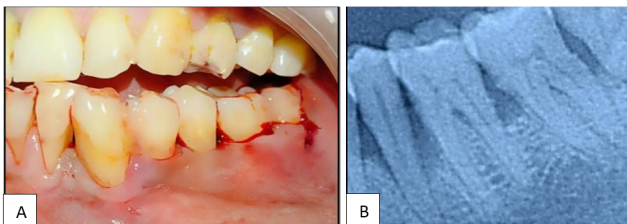
## 2. Case Report

A 47-year-old male patient reported a chief complaint of pain and food lodgment in his lower left back region of the jaw with a diagnosis of stage III grade B periodontitis. On clinical examination : PPD: 8mm on the distal aspect of 35 with Grade I mobility. Radiographic assessment confirmed vertical bone loss extending to the apical 1/3rd of the root.

It was decided to use a non-incised papillae surgical approach to treat intrabony defects. Written informed consent was obtained from the patient. All procedures were performed in accordance with the Declaration of Helsinki.

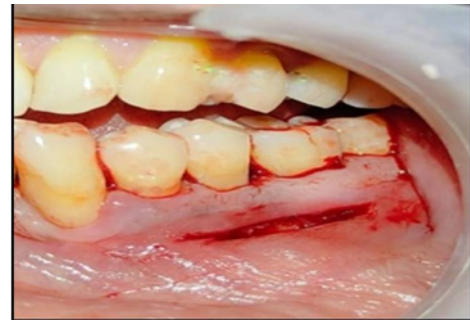
### 2.1. Surgical procedure

A pre-surgical prophylaxis was performed 1-2 weeks prior to the surgical procedure with an ultrasonic scaler (Figure 1 A,B). The surgical procedure was performed under local anesthesia (1:80,000) by using a 15-no. blade. On the buccal aspect, only one apical horizontal or oblique incision is made in the alveolar mucosa, as far as possible from the interdental papillae and marginal keratinized tissues (Figure 2).



**Figure 1:** A): Preoperative clinical image; B): Preoperative radiograph

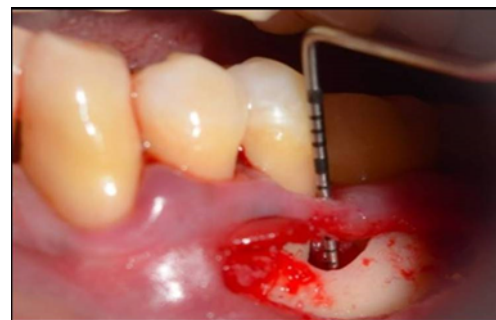
Horizontal incisions are always present on the cortical bone, preserving the supra-bony soft tissue to protect periodontal defects. Mesio-distally, the incision was extended enough to allow correct access to the defect and for proper debridement through a minimal incision. The soft tissue was reflected apico-coronally by a full-thickness



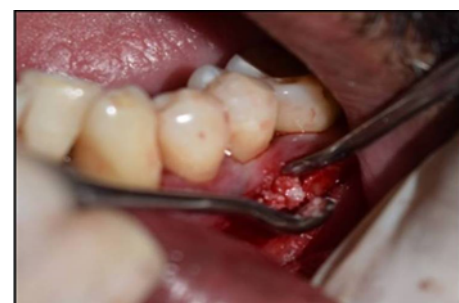**Figure 2:** Horizontal incision given

flap to expose the bone crest, delimiting the intrabony component of the defect (vertical component).

The granulation tissue attached to the base of the papillae is removed by curettes, and care was taken to preserve the marginal tissue (Figure 3) after thorough debridement. The intrabony defect is filled with bonegraft (Osseograft® Advanced Biotech products) (Figure 4).

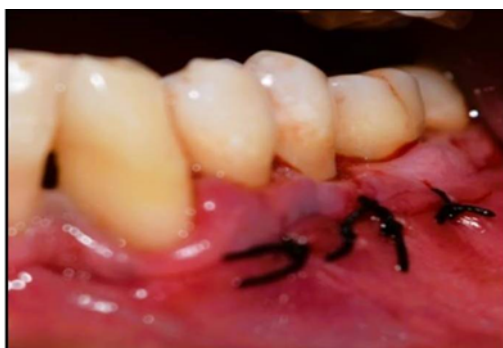

**Figure 3:** Full thickness flap reflected

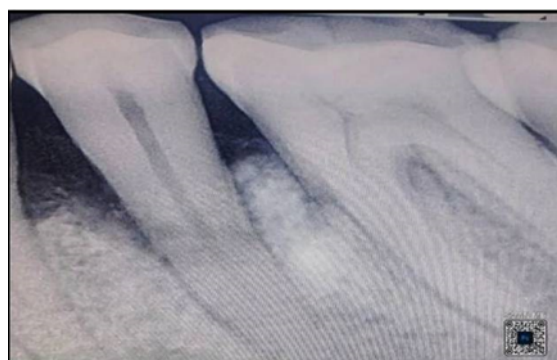

**Figure 4:** Bone graft material placed

Flap is repositioned by a 4-0 silk suture, and horizontal mattress sutures, placed 3 mm away from the borders, were used as the first line of closure, promoting connective tissue contact between both edges of the incision, and single interrupted sutures were then placed as a second line of closure (Figure 5). A surgical dressing was placed using a Coe pack.



**Figure 5:** Suture placed



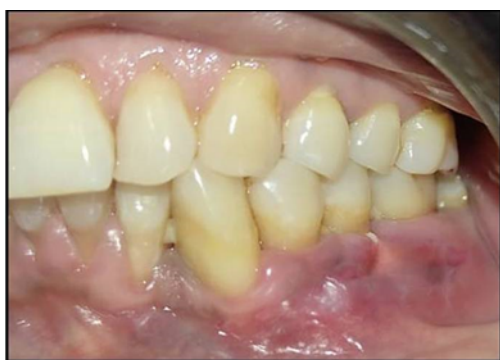**Figure 7:** Postoperative radiographic image

Post-operative antibiotics and analgesics are given. Patients were instructed to use chlorhexidine. (0.2%) rinses twice a day.

The sutures were removed after 7 days. Afterwards, patients were instructed to brush with a soft tooth brush and a roll technique. Patients were recalled for controls (prophylaxis as needed and oral hygiene reinforcement) at 1-week intervals during the first postoperative month.

## 2.2. Outcome

Primary wound healing of the incision and excellent state of the interdental papillae and marginal tissue were observed 1 week after surgery (Figure 6). The patient reported no pain or discomfort. The patient continued to be enrolled in periodontal maintenance. Radiographic examination after 6 months of surgery showed new bone formation and a gain in clinical attachment (Figure 7).



**Figure 6:** Postoperative 6 months clinical image

## 3. Discussion

The aim of periodontal regeneration is the complete resolution of intrabony defects with maximum CAL gain and no alteration of the marginal soft tissues.<sup>10,11</sup> Conventional flap surgery causes soft tissue shrinkage. To overcome some of the limitations, several papilla

preservation techniques have evolved.

The concept of minimally invasive techniques in association with biomaterials (Cortellini; Tonetti, 2007; Mormann; Ciancio, 1977) reported a mean CAL gain of 4.8 mm and a mean PD reduction of 5.2 mm.<sup>12</sup> Moreno Rodriguez et al. (2017) proposed a minimally invasive technique (NIPSA) that represents a new surgical approach for the management of soft tissues in periodontal surgery that maintains the papillae and marginal tissues intact.<sup>13</sup>

The flap design is an important parameter in any surgical procedure for the stabilization of clots and the revascularization of wound healing.<sup>14</sup> A distinctive horizontal incision is positioned apically close to the mucogingival junction, followed by the elevation of a mucoperiosteal flap on the buccal side, preserving the integrity of the lingual soft tissue.

This access to the intrabony defect offers clinical and technical advantages. The flap can be easily stabilized to the attached marginal tissues, thus optimizing wound closure by primary intention.<sup>15</sup> During the elevation of a mucoperiosteal flap and placing a sulcular incision, the connection of the gingivo-periosteal plexus with the periodontal vascularity is hampered<sup>16</sup>. In this study, non-incised gingival tissue shows continuity with gingival vessels and the periodontal ligament.<sup>17</sup>

In the present case, an intrabony defect is treated with xenograft Osseograft® (DMDB-XENOGRAFT, Advanced Biotech products). It contains Type-1 collagen, which is regarded as an osteocompatible grafting material that may serve the purpose of space provision or possibly as a bone-promoting substance.<sup>18</sup>

## 4. Conclusion

This case report offers a viable alternative for managing intrabony defects, providing effective treatment outcomes with minimal surgical trauma and enhanced patient satisfaction. Further research and long-term follow-up studies are needed to validate the efficacy and durability of this approach in periodontal therapy.

## 5. Source of Funding

None.

## 6. Conflict of Interest

None.


## References

- Papapanou PN, Tonetti MS. Diagnosis and epidemiology of periodontal osseous lesions. *Periodontol 2000*. 2000;22:8–21.
- Jenkins WM, Wragg PF, Gilmour WH. Formation of interdental soft tissue defects after surgical treatment of periodontitis. *J Periodontol*. 1990;61(9):564–70.
- Bosshardt DD, Sculean A. Does periodontal tissue regeneration really work? *Periodontol 2000*. 2000;51:208–19.
- Stoecklinwasmer C, Rutjes AW, Dacosta BR, Salvi GE, Jüni P, Sculean A. Absorbable collagen membranes for periodontal regeneration: a systematic review. *J Dent Res*. 2013;92(9):773–81.
- Saydzai S, Buontempo Z, Patel P, Hasan F, Sun C, Akcah A, et al. Comparison of the efficacy of periodontal prognostic systems in predicting tooth loss. *J Clin Periodontol*. 2022;49(8):740–8.
- Cortellini P. Minimally invasive surgical techniques in periodontal regeneration. *J Evid Based Dent Pract*. 2012;12(3):89–100.
- Takei HH, Han TJ, Carranza FA, Kenney EB, Lekovic V. Flap technique for periodontal bone implants. Papilla preservation technique. *J Periodontol*. 1985;56(4):204–10.
- Rodríguez JM, Caffesse RG. Nonincised Papillae Surgical Approach (NIPSA) in Periodontal Regeneration: Preliminary Results of a Case Series. *Int J Periodontics Restorative Dent*. 2018;38:105–11.
- Uzbek UH, Rahman SA, Alam MK, Gillani SW. Bone Forming Potential of An-Organic Bovine Bone Graft: A Cone Beam CT study. *J Clin Diagn Res*. 2014;8(12):73–6.
- Jalaluddin M, Mahesh J, Mahesh R, Jayanti I, Faizuddin M, Kripal K, et al. Effectiveness of Platelet Rich Plasma and Bone Graft in the Treatment of Intra-bony Defects: A Clinico-radiographic Study. *Open Dent J*. 2018;12(1):133.
- Rodríguez J, Ruiz AJO, Caffesse RG. Periodontal reconstructive surgery of deep intraosseous defects using an apical approach. Non-incised papillae surgical approach (NIPSA): a retrospective cohort study. *J Periodontol*. 2018;90(5):454–64.
- Cortellini P, Tonetti MS. A minimally invasive surgical technique with an enamel matrix derivative in the regenerative treatment of intra-bony defects: a novel approach to limit morbidity. *J Clin Periodontol*.

2007;34(1):87–93.

- Moreno-Rodríguez JA, Caffesse RG. A New Papilla Preservation Technique for Periodontal Regeneration of Severely Compromised Teeth". *Clin Adv Period*. 2017;8(1):1–16.
- Wikesjö U, Nilveus R. Periodontal repair in dogs: effect of wound stabilization on healing. *J Periodontol*. 1990;61(12):719–24.
- Azuma H, Kono T, Morita H, Tsumori N, Miki H, Shiomi K, et al. Single Flap Periodontal Surgery Induces Early Fibrous Tissue Generation by Wound Stabilization. *J Hard Tissue Biol*. 2017;26(2):119–26.
- Caton J, Nyman S, Zander H. Histometric evaluation of periodontal surgery. II. Connective tissue attachment levels after four regenerative procedures. *J Clin Periodontol*. 1980;7(3):224–31.
- Bosshardt D, Lang NP. The junctional epithelium: From health to disease. *J Dent Res*. 2005;84(1):9–20.
- Sowmya NK, Kumar AB, Mehta DS. Clinical evaluation of regenerative potential of type I collagen membrane along with xenogenic bone graft in the treatment of periodontal intra-bony defects assessed with surgical re-entry and radiographic linear and densitometric analysis. *J Indian Soc Periodontol*. 2010;14(1):23–9.

## Author biography

**Sharashchandra M Patil**, Professor and HOD  <https://orcid.org/0009-0008-5787-870X>

**Swasthik Kalluraya B**, PG Student

**Anjali Chambole**, PG Student

**Uzma Tarannum**, PG Student

**Farah Naaz**, PG Student

**Indirapriyadarshini**, PG Student

**Cite this article:** Patil SM, Kalluraya B S, Chambole A, Tarannum U, Naaz F, Indirapriyadarshini. Non-incised papillae surgical approach (NIPSA): A new technique for the treatment of deep intra-bony defect: A case report. *IP Int J Maxillofac Imaging* 2024;10(3):113-116.