

Content available at: <https://www.ipinnovative.com/open-access-journals>

IP International Journal of Maxillofacial Imaging

Journal homepage: <https://www.ijmi.in/>

## Case Report

# Plunging ranula in a pediatric patient: A rare case report

Umashankar K V<sup>1</sup>, Mohammed Muzammil Khan<sup>2</sup>, Satya Prasad<sup>3</sup>, Nagaveni N B<sup>1\*</sup>

<sup>1</sup>Dept. of Oral and Maxillofacial Surgeon, Garike Dental Care, Davangere, Karnataka, India

<sup>2</sup>Ministry of Health, Taif, Kingdom of Saudi Arabia

<sup>3</sup>Dept. of Conservative Dentistry, College of Dental Sciences, Davangere, Karnataka, India



### ARTICLE INFO

#### Article history:

Received 20-08-2024

Accepted 14-09-2024

Available online 03-10-2024

#### Keywords:

Plunging ranula

Ranula

Surgical removal

Floor of the mouth

Pediatric patient

### ABSTRACT

‘Plunging Ranula’ also referred as ‘Diving Ranula’ or ‘Cervical Ranula’ or ‘Penetrating Ranula’ is rarely seen in children. They most commonly occur in second and third decade of life and represents a deep type of ranula that is seen in the floor of the mouth and extends to involve the submandibular and submental space. The present article showcases occurrence of a huge plunging ranula in a 13-year-old male Indian patient and its treatment aspect. As many other intraoral swellings or cysts seen in the floor of the mouth mimicking different pathology knowledge about its occurrence, diagnosis and detailed treatment is highly essential among all pediatric professionals to escape from the misdiagnosis.

This is an Open Access (OA) journal, and articles are distributed under the terms of the [Creative Commons Attribution-NonCommercial-ShareAlike 4.0 License](https://creativecommons.org/licenses/by-nc-sa/4.0/), which allows others to remix, tweak, and build upon the work non-commercially, as long as appropriate credit is given and the new creations are licensed under the identical terms.

For reprints contact: [reprint@ipinnovative.com](mailto:reprint@ipinnovative.com)

## 1. Introduction

Numerous odontogenic pathologies like cysts and tumors are seen in children and adolescents.<sup>1–7</sup> ‘Plunging Ranula’ is a rare cystic mass of the neck which represents mucous retention pseudocysts due to obstruction in the sublingual salivary gland. It represents a deep type ranula that extends beyond the floor of the mouth to involve the submandibular and submental space dissecting through the mylohyoid muscle.<sup>8</sup> Plunging ranulas plunge by extending inferiorly beyond the free edge of the mylohyoid muscle, or through a dehiscence of the muscle itself to enter the submandibular space. They are more prevalent in second and third decade of life and rarely seen in children. It is called by various synonyms as ‘diving ranula’ or ‘cervical ranula’ or ‘penetrating ranula’. The exact prevalence is not known and estimated that its prevalence is extremely low with majority occurring in second and third decade of life and rarely encountered in young children. It showed an increased

predilection for males than females and reported more on the left side based on a Chinese retrospective study.<sup>8,9</sup> Though literature shows hundreds of plunging ranula cases in adults but occurrence of this lesion in children less than 10 years is a rare entity. Therefore, the aim of this research clinical case paper is to illustrate a huge plunging ranula occurring in a 13-year-old Indian male patient and its management.

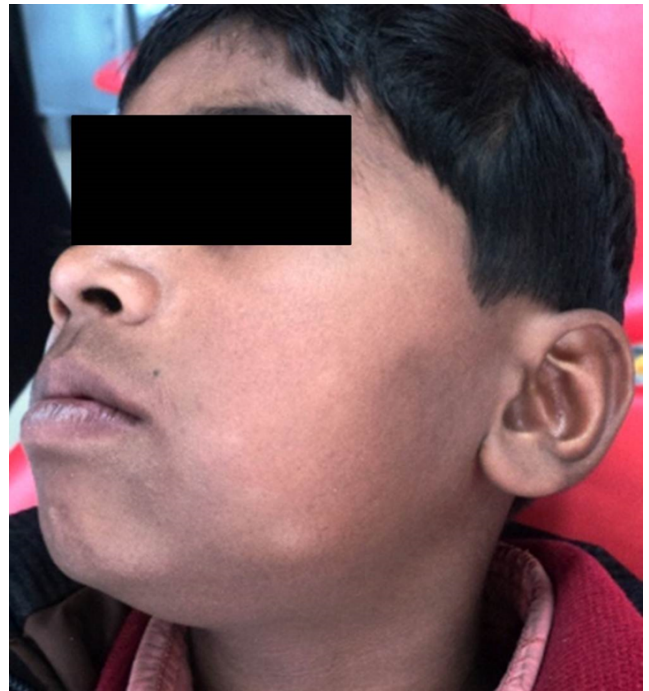## 2. Case Report

A 13-year-old Indian boy visited a private hospital complaining of swelling in the floor of the mouth and also in the left lower border of the jaw. Patient was absolutely normal having normal built and well-nourished with no signs and symptoms of any systemic, metabolic or syndromic disorder. Past history did not reveal presence of any traumatic or surgical history in that region. Patient noticed the swelling two months back which was smaller in size and gradually increased to reach the present size. Extra oral examination showed

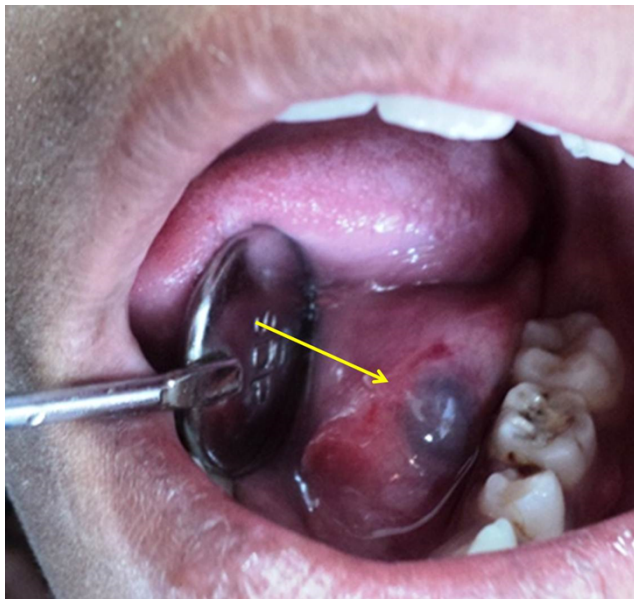
\* Corresponding author.

E-mail address: [nagavenianurag@gmail.com](mailto:nagavenianurag@gmail.com) (Nagaveni N B).

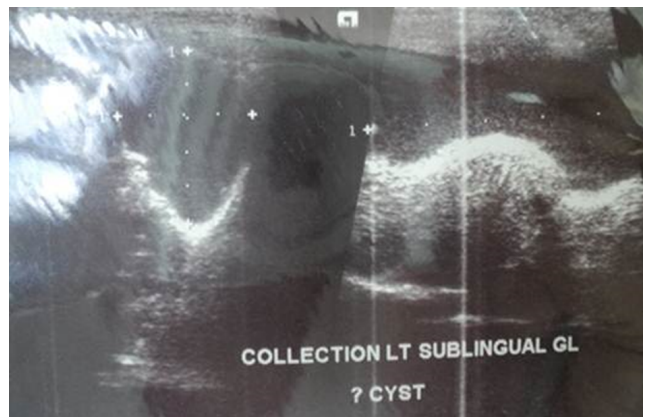presence of swelling in the left side of the submandibular region which was soft in consistency and painless on palpation (Figure 1). On intraoral examination, a soft, painless swelling was observed below the tongue at the left side of floor of the mouth measuring about 3X4 cm in size (Figure 2). Swelling caused discomfort during speaking, chewing food and during swallowing. Patient was subjected to ultrasonographic investigation which showed an ovoid lesion measuring about 3.5X4 cm size located in the submandibular triangle (Figure 3). Based on clinical features and investigation features, a diagnosis of plunging ranula was made. A treatment plan of surgical excision under general anesthesia was planned. Routine blood investigation and thyroid profile parameter test was carried out and results found within normal limits. Prior to surgical excision, aspiration of was performed which showed presence of thick straw-coloured mucus content in the lesion. Under general anesthesia, surgical excision of the cystic mass was carried out (Figures 4 and 5). The cystic mass was extended into the sublingual space by crossing over the mylohyoid muscle and was found adhering to the sublingual gland. Hence, entire sublingual gland along with cystic mass was totally removed using extraoral or cervical approach (Figure 6) followed by suturing (Figure 6). After one week follow-up sutures were removed and patient was regularly monitored till six months and there was no recurrence.



**Figure 2:** Intraoral picture showing swelling in below the tongue



**Figure 1:** Extroral picture showing swelling in the left lower submandibular region



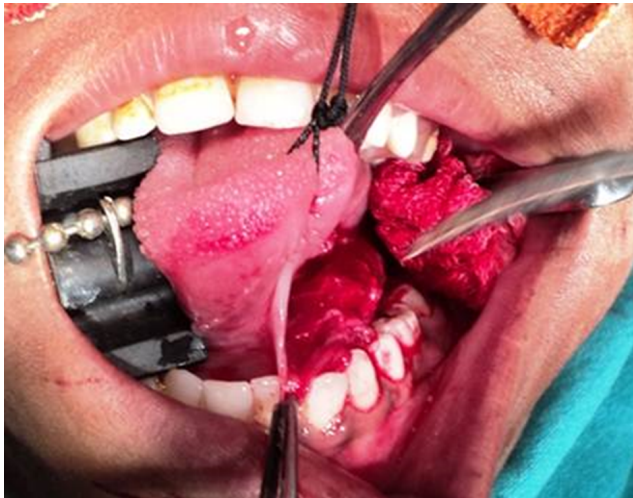
**Figure 3:** Ultrasound image of the lesion

### 3. Discussion

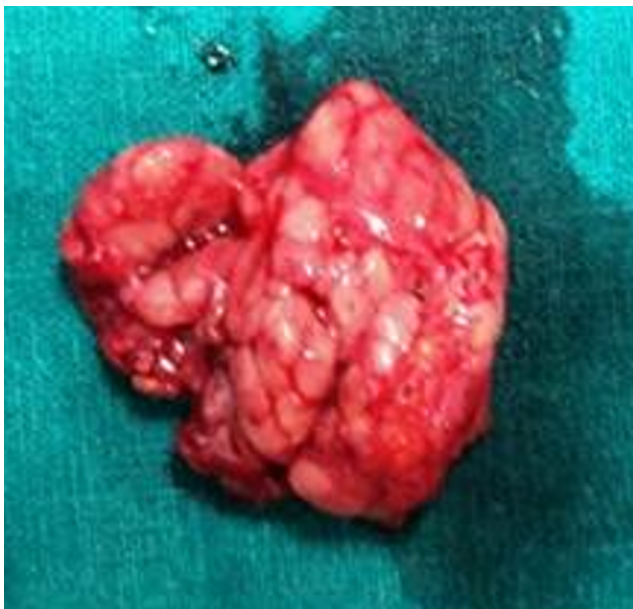Ranula is one of the most common salivary gland disorders that most often occur in the sublingual glands beneath the

tongue, which empty onto the floor of the mouth. There are two types of ranula. One is simple ranula or oral ranula and the other is plunging ranula or diving ranula. Plunging ranula is comparatively rarer than a simple ranula and sometimes seen along with a simple ranula. A simple ranula is mentioned when the cyst located in the floor of the mouth, underneath the tongue. A diving or plunging ranula referred to the cyst which grows down under the mouth and into the neck.<sup>8-10</sup>

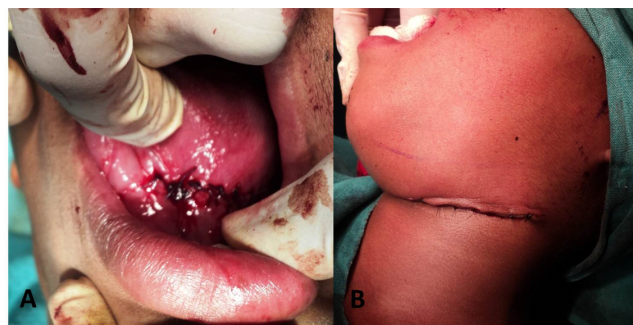
There is no exact etiology behind the occurrence of plunging ranula. It is stated that it may be due to congenital anomalies, diseases of sublingual gland or trauma to the ducts. It is also stated that ranula occurs



**Figure 4:** Removal the cyst by intraoral approach



**Figure 5:** Surgically removed sublingual salivary gland



**Figure 6:** Suturing following surgery. Intraoral (A) and extraoral approach (B)

secondary to a blockage in the ducts of sublingual gland which in turn causing backpressure of mucin and subsequent extravasation of mucus, through a hiatus in the mylohyoid muscle.<sup>11</sup> Other hypothesis suggests a genetic predisposition, causing abnormalities in the mylohyoid muscle, or anatomical changes in the sublingual gland. However, a congenital predisposition especially in children has been reported showing the predominance of ranulas in young siblings. In addition to this, presence of ranula in a one-year-old child suggests a possible congenital malformation.<sup>8,9</sup>

Plunging ranulas clinically manifests as a fluctuant, painless, gradually increasing lateral neck swelling and it does not usually change with swallowing or eating. Majority times it is situated on centre of the submandibular triangle and measures about 4 to 10 cm in size. Its extension seen superiorly into the parapharyngeal space and sometimes even extending to the base of the skull and inferiorly to the supraclavicular area, posteriorly into the retropharyngeal space or across the midline anteriorly.<sup>12</sup>

In differential diagnosis various conditions should be ruled out such as lipomas, branchial cyst, dermoid cyst, cervical thymic cyst, cystic hygroma, benign teratoma, intramuscular hemangioma, neoplastic thyroid disease, submandibular sialadenitis, laryngocele, lymphatic or vascular malformations. In addition to these, other conditions which is associated with infectious cervical lymphadenopathy like, cystic hygroma, cervical thymic cysts, Epstein-Barr Virus, and tuberculosis should also be considered.<sup>11</sup>

For the detection of plunging ranulas various diagnostic methods are employed such as ultrasonography, CT scan and Magnetic Resonance Imaging (MRI). Among these, ultrasonography is one of the best tools and more reliable method of investigation and has been recommended in the literature for diagnosis of pediatric ranulas.<sup>12</sup> MRI provides presence of cystic lesions in the submandibular triangle as well as a mylohyoid defect, which is associated with this condition in up to 90% of the cases. CT scan and MRI stands as second line of investigation method whenever there is an unclear diagnosis even after thorough clinical assessment and ultrasound imaging. In the case described here, ultrasonography was performed which confirmed presence of plunging ranula. Apart from clinical and imaging modality, a definitive diagnosis is achieved with fine needle aspiration cytology (FNAC) and the presence of yellow aspirate, positive amylase and mucin but not associated with epithelial/glandular elements, cholesterol crystals and keratin.<sup>8,12</sup>

Pertaining to treatment aspect, various methods of treatment for plunging ranula have been reported in the literature review such as marsupialization, excision of the pseudocyst, excision of the submandibular gland or sublingual gland and sclerotherapy. However, till date there

is no well documented and most appropriate treatment modality established for the management of plunging ranulas in children.<sup>11</sup> According to literature search, surgery is considered as preferred method to treat this cyst. In children, surgical treatment is quite difficult compared to adults, because of its thinner wall, smaller size and greater friability. In case of adults, for excision of the lesion, an intraoral approach is followed. In the present case, both extra and intraoral approach was employed to completely remove the lesion along with the sublingual salivary gland.<sup>12</sup>

#### 4. Conclusion

Pathologic lesions occurring in intraoral region in children are important clinical entity to all pediatric dentists and other pediatric professionals as he or she is the first person to encounter such patients. Therefore, knowledge about management of rare intraoral pathologies is highly essential among all pediatric dentists and also for early referral to a concerned specialist to provide immediate care. In addition to this, a collaborative team work is important to reach out with proper diagnosis and treatment.

#### 5. Source of Funding

None.

#### 6. Conflict of Interest

None.

#### References

1. Nagaveni NB, Umashankara KV, Radhika NB. Inflammatory dentigerous cyst associated with an endodontically treated primary second molar: a case report. *Arch Orofac Sci.* 2011;6(1):27–31.
2. Nagaveni NB, Umashankara KV, Radhika NB, Satisha TM. Eruption cyst: A literature review and four case reports. *Indian J Dent Res.*

- 2011;22(1):148–51.
3. Nagaveni NB. Lateral periodontal cyst in a pediatric patient - report of a rare case. *J Pediatr Dent Hyg.* 2023;2(1):1008.
4. Nagaveni NB, Shashikiran ND, Reddy VVS. Surgical management of palatal placed, inverted, dilacerated and impacted mesiodens. *Int J Clin Pediatr Dent.* 2009;2(1):30–2.
5. Nagaveni NB, Umashankar KV, Ashwini KS, Chiranjeevi H. Inversion of impacted mandibular third molar in ascending ramus of the mandible - report of a rare case. *Clin Pathol.* 2024;8(1):185.
6. Umashankara KV, Manjunath S, Nagaveni NB. Ameloblastic fibro-dentinoma: Report of a rare tumor with literature review. *J Cranio Max Dis.* 2012;1(2):141–4.
7. Nagaveni NB, Umashankara KV. A giant radicular cyst involving the left maxillary sinus diagnosed on CBCT image - Report of a rare case. *J Oral Health Dent.* 2024;7(1):591–5.
8. Carlini V, Calcaterra V, Pasqua N, Guazzotti M, Fusillo M, Pelizzo G. Plunging ranula in children: Case report and literature review. *Pediatr Rep.* 2016;17(4):6576.
9. Zhi K, Gao L, Ren W. What is new in a management of pediatric ranula? *Curr Opin Otolaryngol Head Neck Surg.* 2014;22(6):525–9.
10. Bertrand B, Chimeli-Ormonde L, Ormonde JP. Plunging ranula in a 7-year-old girl. *J Pediatr Surg Case Rep.* 2021;69:101857.
11. Packiri S, Gurunathan D, Selvarasu K. Management of paediatric oral ranula: a systematic review. *J Clin Diagn Res.* 2017;11(9):6–9.
12. Garofalo S, Mussa A, Mostert M, Suteu L, Vinardi S, Gamba S. Successful medical treatment for ranula in children. *Oral Surg Oral Med Oral Pathol Oral Radiol.* 2014;117(4):289–97.

#### Author biography

**Umashankar K V**, Professor

**Mohammed Muzammil Khan**, Specialist Pedodontist

**Satya Prasad**, Senior Lecturer

**Nagaveni N B**, Professor

**Cite this article:** Umashankar K V, Khan MM, Prasad S, Nagaveni N B. Plunging ranula in a pediatric patient: A rare case report. *IP Int J Maxillofac Imaging* 2024;10(3):117-120.