

Ossifying Fibroma of the Maxilla: A rare case

Priyanka Bhatt¹, Vinod VC², Atul Kaushik^{3,*}, K. Sridevi⁴, Astha Chaudhry⁵

¹Private Practitioner, New Delhi, ²Professor, ^{3,5}Reader, Faculty of Dental Sciences, SGT University, Gurgaon, Haryana, ⁴Professor & Head, Lenora Institute of Dental Sciences, Vikarbad, Andhra Pradesh

***Corresponding Author:**

Email: dratulkaushik@gmail.com

Abstract

Ossifying Fibroma (OF) is benign, uncommon fibro osseous tumor, composed of fibrous connective tissue with variable amounts of calcified tissue resembling bone, cementum or both. It is primarily classified under fibro osseous lesions (FOL's) of the jaw: the rare, benign, non aggressive tumors. OF exhibit markedly varying radiographic patterns based on the amount of mineralized tissue and degree of progression and maturation of the lesion at the time of presentation. This article presents a case of OF with minimal symptoms involving the left maxilla in a 66 year old female patient. The clinical and diagnostic features, management and prognosis are discussed along with the review of literature.

Keywords: Ossifying Fibroma, Fibro osseous lesion, Maxilla

Introduction

OF is benign, uncommon, monostotic well-defined usually unilocular but occasionally multilocular fibro osseous tumor, arising from the cells of periodontal ligament and is composed of fibrous connective tissue with variable amounts of calcified tissue resembling bone, cementum or both. It is generally an asymptomatic, slow growing lesion, found in 2nd to 4th decades of life at the time of diagnosis with female predilection, however ossifying fibroma may affect children and adolescent as well as older adults.^(1,2) It predominantly affects the craniofacial bones, mandible being the most common site of involvement. Reporting here is a case of Ossifying Fibroma in a female aged 66 years with minimal symptoms involving the left maxilla diagnosed with radiographic and histopathological examination.

Case Report

A female aged 66 years reported to the Department of Oral Medicine and Radiology of SGT Dental College with the complaint of painless swelling in the upper jaw since 2 years that was slowly progressive in nature. The patient had a history of hypertension and was on medication since 4 years for the same. Her dental history included extraction of 25, 26, 27 due to caries, around 10 years back.

Extra oral examination revealed facial asymmetry towards the left side associated with fullness in the middle third of the face, measuring approximately size of 18mm x18mm. It was non tender and hard in consistency. Overlying skin was normal and pinchable. No local rise in temperature and no paraesthesia was observed.

Intraorally, a diffuse expansile lesion involving the left maxillary posterior region, measuring approximately 40mm x 30mm was extending from the distal aspect of 24 to the tuberosity region with partial

obliteration of the buccal vestibule (Fig. 1) and normal overlying mucosa. The swelling was non tender and bony hard in consistency. 16, 17, 25, 26, 27, 34, 36 and 37 were missing, 11 and 21 were non vital along with generalized attrition. Based on the history and clinical examination, a provisional diagnosis of a benign lesion affecting the left maxilla was arrived at.

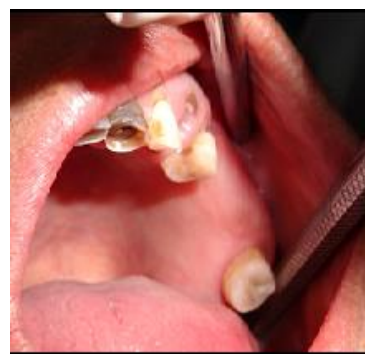

Fig. 1

The investigations advised included the complete blood picture, intraoral periapical radiograph, maxillary occlusal view, panoramic radiograph and cone beam computed tomographic (CBCT) scan. Periapical radiograph and maxillary left lateral topographical occlusal view revealed a diffuse patchy radiolucency in region of 26, 27 along with multiple flecks of fine calcifications; hypercementosis was seen with respect to 28 (Fig. 2 and 3). Panoramic view revealed radiopacity extending from 24 to tuberosity and encroaching onto the maxillary sinus (Fig. 4). To make out the exact extent of the lesion CBCT imaging was planned. CBCT sections showed mixed radiopaque radiolucent (predominately radiopaque) lesion, with well-defined borders, extending from 24 till tuberosity region (Fig. 5) measuring antero posteriorly 4 cm, supero inferiorly 5 cm and mesio distally around 2.5 cm

in dimension. The pterygoid plates though intact, the lesion however did superimpose on the maxillary sinus. No secondary reaction in the sinus could be appreciated. With a clearer picture on the extent of the lesion, we took the next step towards the management.

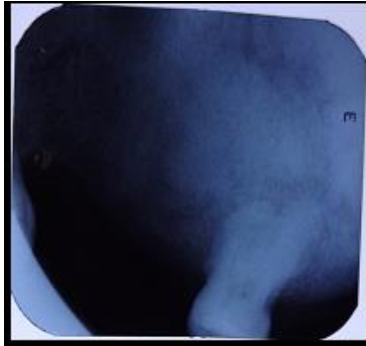


Fig. 2

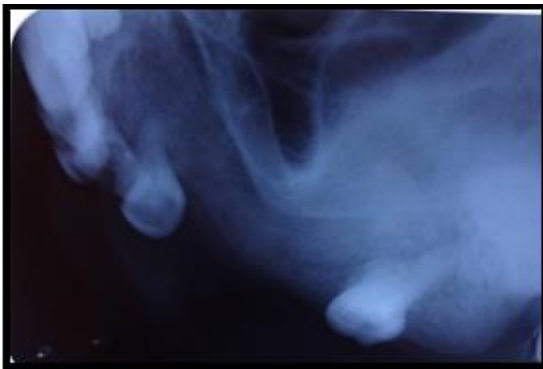

Fig. 3

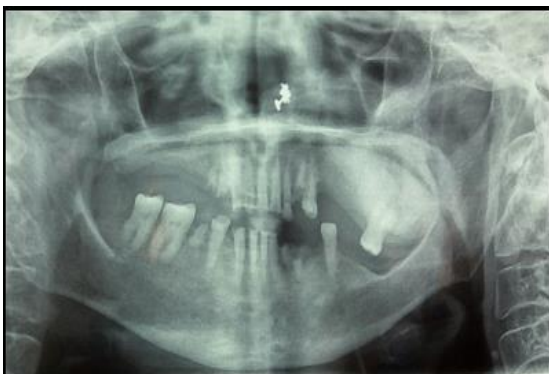

Fig. 4

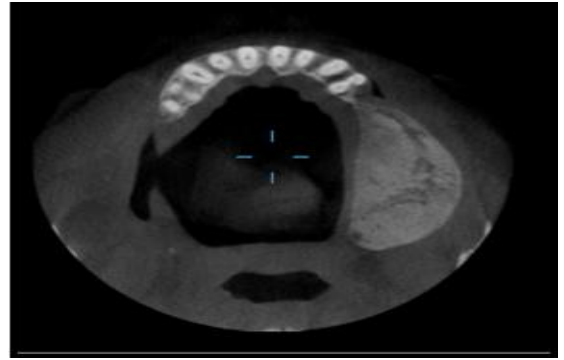


Fig. 5

Incisional biopsy followed by surgical resection of the left posterior maxilla was done under general anaesthesia (Fig. 6 a, b & c). Histopathology revealed proliferating fibroblastic stroma without any mitotic activity and with the deposition of lamellar bone. Connective tissue stroma comprised of plump spindle shaped fibroblasts. Trabecular ossification showed osteoblastic rimming (Fig. 7). The result of which confirmed the diagnosis of OF and the patient is under regular follow up.

Figure: 6(a)

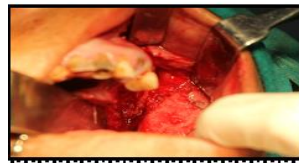

Figure: 6(b&c)

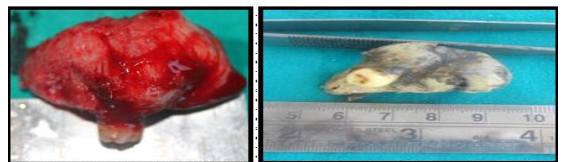


Fig. 6

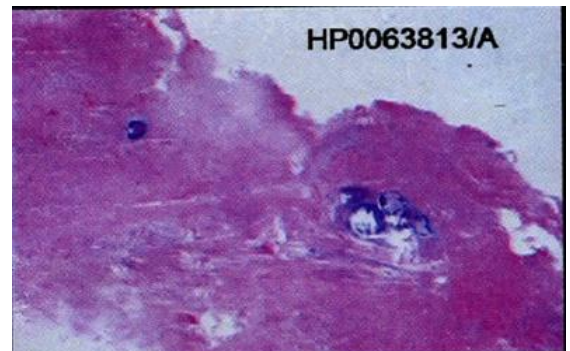


Fig. 7

Discussion

Sciubba et al⁽³⁾ and Yih et al⁽⁴⁾ attributed the first description of OF to Menzel in 1872 as a rare benign primary bone tumor that affects most commonly the

jaws. However the term, OF was first used by Montgomery⁽⁵⁾ in 1927 by which the lesion is currently known.

In 1971, the World Health Organization (WHO) classified four types of cementum containing lesions: fibrous dysplasia, ossifying fibroma, cementifying fibroma and cemento-ossifying fibroma.⁽⁶⁾ According to the second WHO classification, benign fibro-osseous lesions in the oral and maxillofacial regions were divided into two categories, osteogenic neoplasms and non-neoplastic bone lesions; cementifying ossifying fibroma belonged to the former category. However, the term “cementifying ossifying fibroma” was reduced to ossifying fibroma in the new WHO classification in 2005.^(7,8)

OF develops from the pluripotent mesenchymal cells that are capable of forming cementum, bone and fibrous tissue.^(9,10,11) According to Ono et al⁽¹²⁾ the histogenesis of OF consists of two possible origins, the excessive proliferation of the cells of periodontal ligament and a metaplastic process occurring in the connective tissue fibres (non periodontal in origin), the former being more common. OF affects the jaws, could be related to an extensive mesenchymal cellular induction in to bone and cementum, required in odontogenesis. Hence an error in the tissue induction process, may lead to the development of OF in the jaws. Although the precise triggers are still unknown, other suggested factors include trauma, previous extractions and prior existence of periodontitis.⁽¹⁾ OF can occur at any age but usually is found in young adults. Females are affected more often than males.⁽²⁾

Our present case is nearly three decades older than the reported peak incidence and involved the maxilla in a female patient. Juvenile aggressive OF is a subtype of OF, arises in children (early onset), more aggressive clinically, exhibit rapid growth and erosion or invasion of the adjacent tissue and more vascular on histopathologic examination. OF with size over 80mm in their greatest diameter have been termed as “Giant Ossifying Fibroma”.^(13,14) Central ossifying fibromas are slow growing and asymptomatic until they cause expansion. One remarkable finding that the maxillary lesions are large at the time of diagnosis could be attributed to the capacity of the tumor to expand freely within the maxillary sinus similar to our case. The patient did not present with significant clinical symptoms, despite the large size of the lesion encroaching the sinus. OF exhibit markedly varying radiographic patterns based on the amount of mineralized tissue and degree of progression and maturation of the lesion at the time of presentation. Radiographically, the lesion is well circumscribed and initially seen as an osteolytic image followed by gradual transformation into a mixed lesion finally in cases of long duration, it becomes radiopaque, the final stage being considered as exceptional.⁽¹¹⁾

Eversole et al reported 6 variations in the radiographic patterns of OF.⁽¹⁵⁾

1. The most prevalent pattern has an unilocular radiolucency containing radiopaque foci with neither root divergence nor root resorption. The radiopaque foci yield a target appearance with dense foci of ground glass and irregular opacifications.
2. The second common pattern shows a well delineated unilocular radiolucency without radiopaque foci superimposed over the intact roots without causing the root divergence or root resorption.
3. A radiolucency with central opacifications, root divergence and/or root resorption. The radiopaque foci yield a target appearance with dense foci of ground glass or irregular opacifications
4. Massive, expansile lesion larger than 5cm, exhibited well-defined margins with ground glass or mottled radiopacities. These lesions were classified as active or aggressive OF (AOFs)
5. A multilocular radiolucency with/without root resorption
6. A unilocular radiolucency interposed between divergent or resorbed roots.

Waldron C A and Giansanti¹⁶ stated that all OF invariably show a thin radiolucent line surrounding the lesion representing capsule and sometimes a sclerotic rim present within the host bone at the margin that may be smooth and delicate or it may be slightly irregular, more diffuse and of varying thickness. In our present case, CBCT showed a mixed radiolucent radiopaque lesion of size 4cm x 5cm x 2.5cm encroaching the maxillary sinus surrounded by a radiolucent line causing expansion and thinning of the cortical plates, mimicking the Ever sole type 4 OF.

Histopathologically, the OFs are encapsulated, well circumscribed and basically composed of many delicate collagen fibers with whorled arrangement interspersed by large number of actively proliferating fibroblasts. The connective tissue characteristically presents spherical deposits of calcified material that may increase in number, enlarge and coalesce as the lesion matures accounting for the increasing radiopaqueness of the lesion on the radiograph and also show osteoblastic rimming, similar to the present case reported here.^(6,7)

The radiologic differential diagnosis of OF necessarily includes the radiolucent lesions and lesions that contain radiopacities within well-defined radiolucent mass depending on the degree of maturation at the time of presentation. Keeping the present case in view, lesions like Fibrous Dysplasia, Chondrosarcoma, Osteosarcoma, Benign cementoblastoma, Pindborg tumor, Gorlin cyst and Periapical cemento osseous dysplasia may be included under differential diagnosis.

The highly cellular nature of the stroma reflects the aggressive nature of these lesions and demands

complete surgical excision to obviate local recurrence. This can be achieved by enucleation and curettage of smaller lesions and radical resection for larger lesions. The wide variation in the reported rates of recurrences of 14-38% could be due to incomplete removal and variations in the follow up period.^(17,18,19)

Conclusion

The OF of the maxilla is an uncommon, benign fibro osseous tumor. The timely diagnosis and management of this tumor is of utmost importance to limit the progression and to reduce morbidity of the patient. In the present case report, CBCT played an important role in determining the extent of the lesion thus aiding in proper, diagnosis and apt management.

References

1. Marx RE, Stern D. Oral and maxillofacial pathology. A rationale for diagnosis and treatment. Chicago: Quintessence 2002. P.789-95.
2. Gurol M, Uckan S, Guler N, Yatmaz PI. Surgical and reconstructive treatment of a large ossifying fibroma of the mandible in a retrognathic patient. J Oral Maxillofac Surg 2001;59:1097-100.
3. Sciubba JJ, Younai F. Ossifying fibroma of the mandible and maxilla: review of 18 cases. J Oral Pathol Med 1989;18:315-21.
4. Yih WY, Pederson GT, Bartley MH. Multiple familial ossifying fibromas: relationship to other osseous lesions of the jaws. Oral Surg Oral Med Oral Pathol 1989;68:754-8.
5. Montgomery AH. Ossifying fibroma of the jaw. Arch Surg 1927;15:30-44.
6. Pindborg JJ, Kramer IRH. Histological typing of odontogenic tumors, jaw cysts and allied lesions. In: International histological classification of tumors. Geneva:WHO,1971,pp 31-34.
7. Kramer IRH, Pindborg JJ, Shear M. Neoplasm and other lesions related to bone .Histologic typing of odontogenic tumors, World Health Organization. Berlin, Springer-Verlag 1992:28-31.
8. Reichart PA, Philipsen HP, Sciubba JJ. The new classification of head and neck Tumors (WHO)- any changes? Oral Oncol 2006;42:757-758.
9. Eversole LR, Leider AS, Nelson K. Ossifying fibroma: a clinicopathologic study of sixty-four cases. Oral Surg Oral Med Oral Pathol Oral Radiol Endod 1985;60:505-11.
10. Mintz S, Velez I. Central ossifying fibroma: an analysis of 20 cases and review of literature. Quintessence Int 2007;38:221-7.
11. Waldron CA. Fibro-osseous lesions of the jaws. J Oral Maxillofac Surg 1993;51:828-35. Review.
12. A. Ono, G. Tsukamoto, H. Nagatsuka et al., "An immunohistochemical evaluation of BMP-2,-4, osteopontin, osteocalcin and PCNA between ossifying fibromas of the jaws and peripheral cement-ossifying fibromas on the gingival," Oral Oncology, vol.43, no.4, pp. 339-344, 2007.
13. Van Heerden WF, Raubenheimer EJ, Weir RG, Kreidler J. Giant ossifying fibroma: A clinicopathologic study of 8 tumours. J Oral Pathol Med. 1989; 18:506-9. [PubMed]
14. Khanna JN, Anarade NN. Giant ossifying fibroma: Case report on a bimaxillary presentation. Int J Oral Maxillofac Surg. 1992;21:233-5. [PubMed]
15. Eversole LR, Merrell PW, Strub D. Radiographic characteristics of central ossifying fibroma. Oral Surg Oral Med Oral Pathol 1985;59:522-527.
16. Waldron CA, Giansanti JS. Benign fibro-osseous lesions of the jaw: a clinical-radiologic review of sixty-five cases. Oral Surg Oral Med Oral Pathol 1973;35:340-350.
17. Liu Y, Wang H, Zang Z, Miao J, Schimizutani K, Koseki T. Ossifying fibroma of the jaw bone: 20 cases. Dentomaxillofacial Radiology 2010;39:57-63.
18. Triantafyllidou K, Ventis G, Karakinaris G, Iordanidis F. Ossifying fibroma of the jaws: a clinical study of 14 cases and review of literature. Oral Surg Oral Med Oral Pathol Oral Radiol. 2012;114(2):193-199.
19. R. Gunaseelan, P. Anantnarayanan, E. Ravindramohan, K. Ranganathan, "Large cement-ossifying fibroma of the maxilla causing proptosis: a case report," Oral Surgery, Oral Pathology, Oral Radiology and Endodontology, vol.104, no.4, pp.e21-e25, 2007.