

Osteosarcoma of mandible – A case report with imaging perspective

Sankireddy Shailaja^{1,*}, Astha Chaudhary², V. Eswar Rao³, Ratna Samudrawar⁴

¹Associate Professor, ²Assitant Professor, SGT Dental College, Hospital & Research Institute, Gurgaon, Haryana, ⁴UG Student, Dept. of Oral Medicine & Radiology, Rungta Dental College, Chattisgarh, ³Reader, Dept. of Oral & Maxillofacial Surgery, CKS Teja Dental College, Tirupati

***Corresponding Author:**

Email: drsrshailaja@gmail.com

Abstract

Osteosarcoma (OS) is the most common primary bone malignant tumor in which osteoid is produced directly by malignant stroma as opposed to adjacent reactive bone formation. Osteosarcoma of the jaw (OSJ) represent less than 10% of all osteosarcomas and less than 1% of all malignant tumors of the head and neck. The dentist may be the first health care professional who observes tumors involving the jaws. Early diagnosis and radical surgery are the keys to high survival rates.

Conventional radiographs are of limited value in head and neck osteosarcomas because of the superimposed bony structures. CT provides excellent detection of tumor calcification, cortical involvement, and, in most instances, soft-tissue and intramedullary extension. MR is even more effective in demonstrating the intramedullary and extra osseous tumor components on both T1- and T2-weighted images thus helps not only in better preoperative assessment but also post operative follow up. Hereby, reporting a case of osteosarcoma of mandible in a 40 year old female patient with emphasis on CT and MR imaging characteristics.

Keywords: CT; Jaw; MRI; Osteosarcoma.

Introduction

OS represent malignant neoplasms arising from mesenchymal stem cells and/or their early progeny. Their partial differentiation leading to the production of tumor bone from a malignant cellular stroma is what defines them as osteosarcomas rather than any other malignant mesenchymal tumor that can arise from a mesenchymal stem cell.

Osteosarcomas of long bones (OSL) occur at an average age of 25 years whereas the average age in the jaws is 37 years. Mandibular osteosarcomas are more frequent than those in the maxilla (60:40). Majority arise from within the bone. Parosteal/Juxtacortical OS arise from periosteum and accounts for only 4% of OSL and less than 1% of OSJ.⁽¹⁾

Imaging is important for the diagnosis, as clinical symptoms such as pain, paraesthesia, swelling and loose teeth are non-specific.⁽²⁾ In some cases, a classical histopathological appearance makes the diagnosis clear; however when the picture is that of new bone formation in a background of cellular fibrous connective tissue, the diagnosis becomes more difficult. Depending on tissue sampling and location of biopsy, these similar features can be seen in active fibrous dysplasia and chronic osteomyelitis as well. Hence, when the histopathology is not clear cut, the imaging characteristics plays a crucial role in the establishment of diagnosis in a non-invasive manner.⁽³⁾

Conventional imaging is nonspecific and needs to be supplemented with CT and MRI to provide details regarding tumor grade, composition, extent and involvement of adjacent hard and soft tissue structures.⁽⁴⁾ Multiple reports of OSJ have been published in the literature regarding the imaging

characteristics. However, they are limited to conventional imaging and CT. The MR characteristics of OSJ are scantily reported. Hence, this report aims to emphasize the CT as well as the MR characteristics of OSJ to aid the oral and maxillofacial radiologist in the proper diagnosis.

Case Report

A 40 year old female patient presented with a painful, non-discharging swelling in the right lower back region of the jaw since 4 months subsequent to the extraction of carious 48. It started intraorally and gradually increased to extend extraorally with resultant trismus. Patient also gave a history of paraesthesia of right lower lip since 2 months.

On extraoral examination, a single diffuse swelling was seen over the right body of mandible extending supero-inferiorly from alaragus line to 3 cm crossing inferior border of mandible and mediolaterally from angle of mouth to 1 cm crossing tragus of the ear measuring approximately 8X6 cm.(Fig. 1). The skin overlying the swelling showed no secondary changes. On palpation it was firm in consistency, afebrile, tender and fixed to underlying bone but the overlying skin was partially movable.

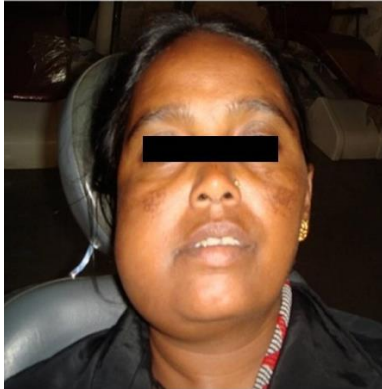

Fig. 1: Extra oral view of the patient showing diffuse swelling on right side of the face

Intraorally, a solitary localised swelling was seen in right mandibular buccal vestibule extending from 46 till retro molar region and also extending superiorly obliterating the buccal vestibule up to cervical third of molars. Lingual cortical plate expansion was noted in 47 region below mylohyoid prominence. It was firm, non-tender and fixed.

Orthopantomograph revealed mixed radiolucent-radiopaque lesion in the mandibular body extending from mesial aspect of 46 and involving ramus up to 4 cm below coronoid process. There was a breach in inferior cortex and spiculated periosteal reaction was seen. Loss of lamina dura and PDL space widening in 46, 47, 48 with alteration in the trabecular pattern was noticed. (Fig. 2).

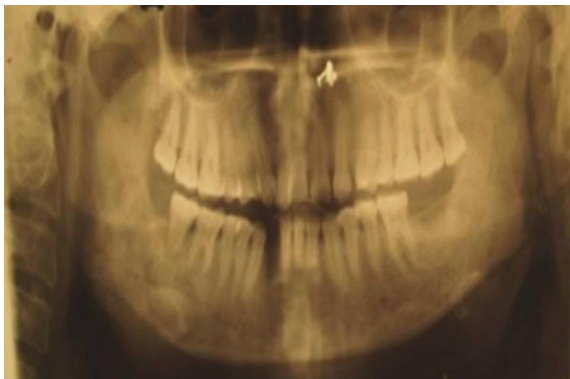

Fig. 2: OPG showed mixed radiolucent-radiopaque lesion extending from mesial aspect of 46 to involving ramus up to 4 cm below coronoid process. Loss of lamina dura and widening of PDL space IRT 45, 46 and 47

Axial and coronal CT sections in bone window revealed hyperdense areas in right ramus with breach in the medial and lateral cortex and perpendicularly radiating spicules of bone mediolaterally, anteroposteriorly and superoinferiorly but sparing the condyle. Also, mandibular foramen involvement was appreciated on right side signifying the subjective symptom of paraesthesia on right side. (Fig. 3a,b,c) The

axial section in soft tissue window showed the massive soft tissue mass around the ramus lesion with involvement of medial pterygoid and masseter muscle mediolaterally and measuring 6.79 cm X 5.10 cm in its largest dimensions. (Fig. 4).

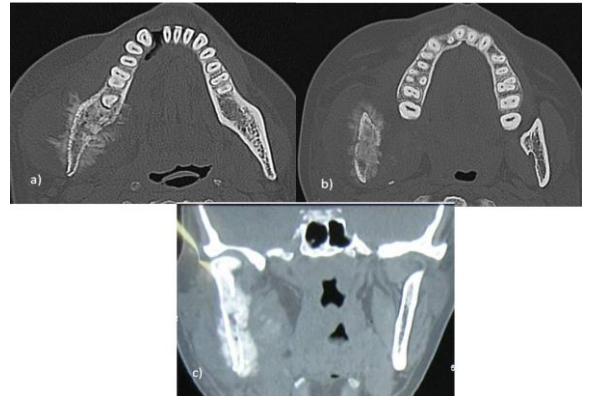


Fig. 3: CT-axial-soft tissue window revealing a massive lesion involving ramus with surrounding soft tissue mass involving the pterygomasseteric sling. Multiple hyper dense foci within and around the lesion suggestive of ossification. Note the normal ramus and adjacent masseter and medial pterygoid muscles on left side

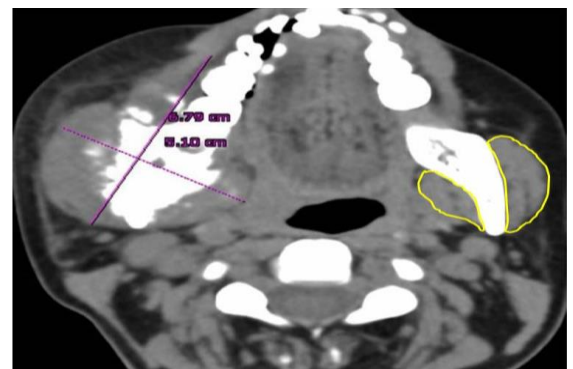


Fig. 4: CT-axial(a) and coronal(c) section revealing cortical breach and sclerotic area in right ramus with perpendicular spiculated periosteal reaction sparing the condyle. (b) shows the involvement of mandibular foramen on affected side

MRI-Axial T1 weighted image showed hypointense mass in the right side involving ramus, masseter and medial pterygoid. (Fig. 5a). Axial T2 weighted image revealed heterogeneous mixed intensity destructive mass involving the right mandibular body, subcutaneous soft tissues of mandibular and maxillary regions with displacement of the muscles of cheek. Marrow infiltration into the alveolus was seen. Multiple enlarged lymph nodes were seen. Coronal T2 weighted image showed hyperintense lesion extending superiorly into temporal bone and inferiorly seen displacing the submandibular gland as compared to normal gland on left side. (Fig. 6a). Sagittal T2 image showed temporal

extension of the lesion sparing the mandibular condyle. (Fig. 6b). The CT and MRI features gave the diagnosis of osteogenic sarcoma of right mandible.

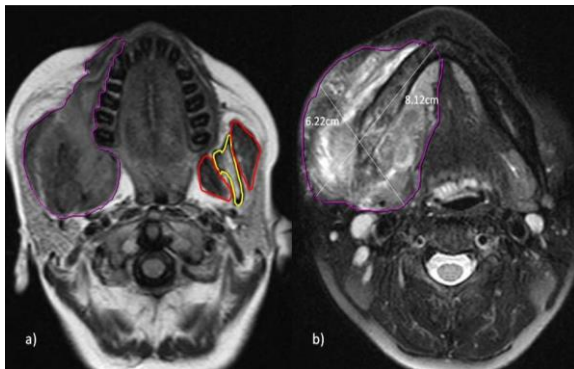


Fig. 5: MRI-Axial T1(a) weighted image showing hypointense mass lesion in right mandibular body and ramus with involvement of adjacent muscles. Normal ramus and masseter and medial pterygoid muscles on left side. Axial T2(b) weighted image revealing evidence of heterogeneous mixed intensity destructive mass lesion of right mandible. The surrounding subcutaneous tissue is hyperintense with displacement of muscles of cheek. Marrow infiltration of the alveolus noted on right side. Multiple enlarged lymph nodes noted

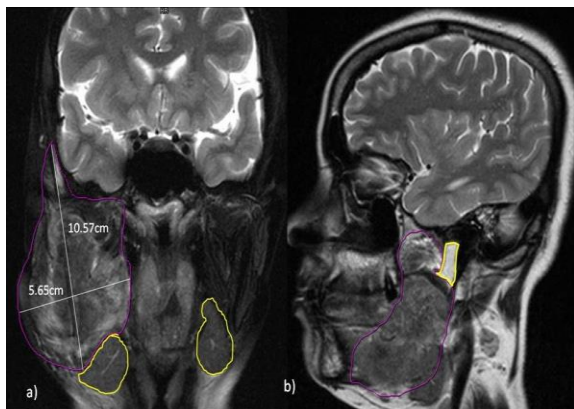


Fig. 6: MR- Coronal T2(a) showing hyperintense lesion extending superiorly into temporal bone and inferiorly pushing submandibular gland compared to normal gland on left side. Sagittal T2 (b) showing extension into temporal fossa sparing condylar region

Incisional biopsy was done and it showed cellular tumor and surrounding fibroadipose tissue and multiple skeletal muscle bundles. Round polygonal cells were seen scattered singly and in clusters and sheets, closely associated with osteoid matrix containing scant to moderate amount of amphophilic cytoplasm and large round to oval nucleus. Moderate nuclear pleomorphism, coarse chromatin clumping with high mitotic activity was seen. The intercellular matrix showed focal

ossification, some osteoclastic type of giant cells suggestive of osteosarcoma.

The patient was then referred to oncology department for surgery and chemotherapy treatment.

Discussion

OSJ occurs in the mean age range of 31- 40 years^(5,6) with a debatable gender predilection. Some studies have reported male predominance⁽⁷⁾ whereas some have reported female predominance⁽⁸⁾ and equal gender distribution.⁽⁹⁾ The characteristic clinical presentation of OSJ is swelling as compared to pain in OSL⁽⁶⁾ as seen in our patient. The site predilection in OSJ is mandible⁽¹⁰⁾ with preferred location being ramus and condyle. However, in our case the condyle was particularly spared with epicentre being mandibular body and ramus.⁽¹¹⁾

Imaging characteristics of OSJ are diverse owing to diverse patterns of bone destruction and varied degrees of calcification leading to osteolytic, osteoblastic and mixed patterns. Osteoblastic pattern is commonly seen in OSJ.⁽¹²⁾ Conventional imaging even though, suffers limitation of superimposition can prove to be vital in the diagnosis by detecting the asymmetrically widened periodontal ligament space (WPLS) on IOPA which is significant finding of early OSJ, chondrosarcoma(CS) and ewing sarcoma(ES).⁽¹³⁾ This asymmetric widening (Garrington's sign) needs to be differentiated from symmetric widening in systemic sclerosis.⁽¹⁴⁾ Also; conventional imaging can be an indispensable adjunct to CT in patient with extensive metallic restoration or cast partial dentures.⁽¹¹⁾

Cross-sectional imaging in the form of CT and MRI best determines the extent in both soft tissue and hard tissue structures for preoperative assessment. CT provides excellent detection of tumor matrix calcification, cortical involvement and bone destruction or reaction.⁽¹³⁾ CT is better than MRI in demonstrating matrix mineralization but is less accurate in detecting skip lesions and bone marrow and soft tissue extension.⁽¹⁵⁾

Three specific CT appearances of OSJ have been described by Bianchi SD and Boccardi A.⁽⁷⁾ The first is radiolucent, characterized by a total absence of bone formation within the tumour. On conventional imaging, this appears as a nonspecific erosion of bone similar to that seen in carcinoma or metastatic lesion. The second has a mottled appearance with small areas of amorphous ossification separated by non-ossified tumour tissue. This mottled ossification is sometimes visualized exclusively on CT. The third, with lamellar ossification, is typically characterized by bony plates irradiating from a focus like a sunburst. This type is easily detected by conventional imaging. However, CT better differentiates the fine lamellae from adjacent structures.⁽⁷⁾ Our case showed features of third type. CT in our case clearly showed tumor calcification, cortical breach, adjacent muscle and nerve encroachment as

well as intramedullary extension. Spiculated perpendicular periosteal reaction was beautifully appreciated.

Periosteal reaction (PR) is a response of cellular layer of periosteum to the underlying tumor or infection. OS is one neoplasm that can show diverse periosteal reactions in the form of lamellar interrupted, onion skin, solid irregular, codman's triangle, sunburst and irregular spiculated reaction. However, these periosteal reactions are not limited to only OS; they can be seen in osteomyelitis, CS and ES. Osteomyelitis will usually show lamellar uninterrupted pattern with maintenance of cortical continuity whereas parallel lamellated interrupted PR i.e. with permeative destruction of cortex is usually a sign of malignancy.⁽¹⁶⁾

Spiculated form of PR is associated with gross destruction of the cortex in malignant tumors and is always seen within the tumor mass. The divergent spicules may be composed of tumor bone, reactive bone or combination of both. In rapidly but steadily growing lesions, the periosteum will not have enough time to lay down even a thin shell of bone; therefore the tiny fibers that connect the periosteum to the bone become stretched out perpendicular to the bone, which after ossification produce a pattern called 'sunburst' or 'hair-on-end' depending on the extent of bone involved by the process.⁽¹⁶⁾ However, this type is not limited to OSJ, it can be seen in CS as well as ES. The differentiation between OS and CS may be troublesome radiographically and sometimes impossible even histologically. CS appears less aggressive radiographically with less bone destruction and more bone formation.⁽⁶⁾ New bone in OS & parosteal OS and secondary deposits tend to be coarser and less well defined so that the spicules are thicker than the intervening spaces. In ES and hyper trophic osteoarthropathy the layers of new bone are characteristically fine and thinner than the spaces between them.⁽¹⁷⁾

MR is most effective in demonstrating the intramedullary and extra osseous tumor components on both T1 and T2-weighted images. Bone marrow extension is best seen on T1-weighted images as loss of the high signal intensity of bone marrow. Periosteal new bone growth appears as a low intensity area on various MRI sequences. The osteoblastic component of the tumor has low signal intensity on all sequences. The non-mineralized component has low signal intensity on T1 –weighted images and high signal intensity on T2-weighted images. Soft tissue extension is best seen on T2-weighted images as tumor and muscle may have the same signal intensity on T1-weighted images.⁽¹⁵⁾

MRI is superior to CT in distinguishing the margins of the tumour.⁽¹⁸⁾ In our case, size of the tumor in MRI is more compared to CT thus proving that MRI is better in delineation of the borders thus helping the surgeon in better preoperative assessment. The intramedullary extension in our case was demonstrated

in all the sections. Soft tissue extension was better visualized by the involvement of muscles of mastication, masticator and parapharyngeal space and lymph node involvement in axial images. Extension of the tumor into temporal fossa and pressure effect on right submandibular gland was better visualized in coronal images.

Imaging, especially cross sectional is also helpful in the evaluation of tumor's response to the chemotherapy treatment which is the mainstay treatment modality in sarcomas. Positive response to treatment is indicated on CT by decrease in size or complete disappearance of the soft tissue mass, increased calcification of the mass, improved delineation of the margins and formation of a peripheral rim of calcification. Decreased signal intensity of the non-mineralized mass on T2-weighted MR images is thought to represent fibrosis or sclerosis of the tumor. Persistent high signal intensity may be a result of non responding tumor or necrotic tumor, reactive granulation tissue or hemorrhage. Administration of gadolinium cannot help distinguish viable tumor from reactive inflammation, since both enhance, but a lack of enhancement indicates tumor necrosis.⁽¹⁵⁾ Unfortunately, we could not have the follow up CT and MR images of the patient.

In conclusion, OSJ may have a nonspecific clinical appearance but its imaging features are characteristic and role of oral and maxillofacial radiologist is indispensable in the diagnosis at early stages as well as in the careful differentiation from other similar lesions for better patient treatment and prognosis.

References

1. Malignant neoplasms of bone in Marx RE, Stern D. Oral and Maxillofacial Pathology: a rational for diagnosis and treatment. Chicago: Quintessence Pub Co; 2003. p. 851.
2. Sheikh S, Pallagatti S, Aggarwal A, Gupta D, Puri N, Mittal A: Osteosarcoma of the maxilla: A case report. J Clin Exp Dent. 2010;2(3):e 117-120.
3. Yeşilova E, Akgünlüb F, Dolanmazc D, Yaşard F, Şenere S: Osteosarcoma: A case report. Eur J of Dent 2007, 1(1):60-63.
4. Razek A A, Huang B Y: Soft tissue tumors of the head and neck: Imaging based review of the WHO classification: RSNA, 2011. Radiographics.rsna.org.1923-1954.
5. Garrington GE, Scofield HH, Cornyn J, Hooker SP. Osteosarcoma of the jaws: analysis of 56 cases. Cancer 1967;20:377–391.
6. Wang S, Shi H and Yu Q: Osteosarcoma of the jaws: demographic and CT imaging features: Dentomaxillofacial Radiology (2012) 41, 37–42.
7. Bianchi SD, Boccardi A. Radiological aspects of osteosarcoma of the jaws. Dentomaxillofac Radiol 1999;28:42-47.
8. Bennett JH, Thomas G, Evans AW, Speight PM. Osteosarcoma of the jaws: A 30-year retrospective review. Oral Surg Oral Med Oral Pathol Oral Radiol Endod 2000;90:323-333.
9. Clark JL, Unni KK, Dahlin DC, Devine KD. Osteosarcoma of the jaw. Cancer 1983;51:2311–2316.

10. August M, Magennis P, Dewitt D. Osteogenic sarcoma of the jaws: factors influencing prognosis. *Int J Oral Maxillofacial Surg* 1997;26:198–204.
11. Lee YY, Van Tassel P, Nauert C, Raymond AK, Edeiken J. Craniofacial osteosarcomas: plain film, CT, and MR findings in 46 cases. *AJR Am J Roentgenol* 1988;150:1397–1402.
12. Sayin B, Yildirim N, Vural N, Dede D: Osteosarcoma of the maxilla; *Radiol Oncol* 2005;39(2):95-9.
13. Khorate M M, Goel I S, Singh M P and Ahmed J: Osteosarcoma of Mandible: A Case Report and Review of Literature. *J Cancer Sci Ther* 2010;2(4):122-125.
14. Samraj L, Kaliamoorthy S, Venkatapathy R, Oza N: Osteosarcoma of the mandible: A case report with an early radiographic manifestation. *Imaging Science in Dentistry* 2014;44:85-8.
15. Haaga J.R. CT and MRI of the whole body. In Amikare Gentili. *Musculoskeletal tumors*. 5th edition. Chicago: Mosby/Elsevier, 2008: p. 1806-1824.
16. Ida M, Tetsumura A, Kurabayashi T and Sasaki T Periosteal new bone formation in the jaws. A computed tomographic study. *Dentomaxillofac Radiol* (1997) 26, 169-176.
17. Ghom A.G, Ghom S.A. Textbook of oral radiology. In: Lohe. V and Kadu. R. Periosteal bone reactions and its diagnostic significance. 2nd ed. India: Elsevier; 2016; p. 844-52.
18. Uchiyama Y, Matsumoto K, Murakami S, Kanasaki T, Matsumoto A, Kishino M and Furukawa S. MRI in a case of osteosarcoma in the temporomandibular joint: *Dentomaxillofac Radiol* (2014) 43, 20130280.