

Evaluation of size and morphology of sella turcica

Syeda Arshiya Ara^{1,*}, Shilpa Shastri², Bhagyashree M Patil³, Humera Ayesha⁴, Priyanka A⁵

¹Professor, ^{2,4,5}PG Student, ³Senior Lecturer, Dept. of Oral Medicine & Radiology, Al-Badar Rural Dental College & Hospital, Gulbarga, Karnataka

***Corresponding Author:**

Email: drarshiyazaka@gmail.com

Abstract

Introduction: One of the most commonly used cranial landmarks for cephalometric tracing is sella point. Sella point is located in the centre of sella turcica with the turcica housing the pituitary gland in the cranial base. This gland lies within the pituitary fossa and consists of the anterior lobe, the intermediate lobe and the posterior lobe. Any abnormality or pathology in the gland could manifest from an altered shape of the sella turcica to a disturbance in the regulations of glandular hormones, prolactin, growth hormones, thyroid – stimulating hormone, follicular stimulating hormone, etc.

Aims and Objective: The aim of the study was to determine difference in dimensions of sella turcica in different age groups and genders, that could assist in detection and evaluation of pathological conditions.

Materials and Method: Lateral cephalometric radiographs of 100 individuals (50 males and 50 females) were evaluated retrospectively. The radiographs were divided into two groups according to the subject's age: pre-pubertal (<15 years) and post pubertal (15 years or more). Linear dimensions length, depth and diameter were measured. Chi-square test and ANOVA test were used for statistical analysis

Results: A statistical significant difference in linear dimensions between age groups were found in sella length, depth and diameter with p value <0.0001. There was no significant difference in the linear measurements of sella turcica between males and females with p value >0.05.

Conclusion: Dimensions of sella turcica used as reference standards in the assessment of age of the subjects in different age groups and there was a gradual increase in the size of sella turcica as age advances.

Keywords: Sella point, Sella turcica, Lateral cephalometric.

Introduction

The lateral cephalometric radiographs displays numerous cranial, facial and oral anatomical structures imaged from lateral aspect. Cephalometric radiography is helpful aid in diagnosis and analysis of dentofacial and neurocranial morphology.⁽¹⁾ One of the most commonly used cranial landmarks for cephalometric tracing is sella point. Sella point is located in the centre of sella turcica with the turcica housing the pituitary gland in the cranial base. This gland lies within the pituitary fossa and consists of the anterior lobe, the intermediate lobe and the posterior lobe. (Fig. 1). Any abnormality or pathology in the gland could manifest from an altered shape of the sella turcica to a disturbance in the regulations of glandular hormones, prolactin, growth hormones, thyroid – stimulating hormone, follicular stimulating hormone, etc. Disturbances can in turn lead to growth problems such as acromegaly or gigantism, cushings disease, hyperthyroidism amenorrhea and menstrual disturbance.⁽²⁾

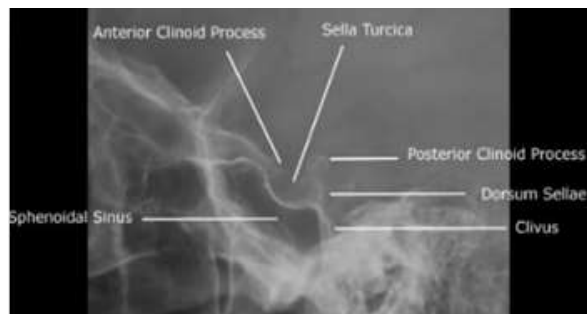


Fig. 1: Anatomical structure of Sella turcica

Materials and Method

Study settings: This retrospective study was conducted out in the Department of Oral Medicine and Radiology Al- Badar Dental College, Gulbarga.

Study Subjects: A study group consisted of total 100 individuals, 50 males and 50 females, they were further divided into various age group of 10-20 years, 21-30 years, 41-50 years.

Inclusion Criteria

- Healthy patients without any history of systemic diseases.
- Patients in the age group of 10-50 years.
- Patients advised for lateral cephalometric radiograph for orthodontic treatment.

Exclusion Criteria

- Individuals with congenital defect in the craniofacial region like clefts and malformations

- History of craniofacial fractures
- Patients suffering from disorder of bone, nutritional deficiencies and endocranial disturbances.

Following Measurements were Calculated: This retrospective study consists of lateral cephalogram images stored data. The images were viewed on a flat screen Compaq TFT- LCD monitor with a resolution of 2906 x 2304. Software used was Trophy Dicom and Master view version 4.5.1. The images obtained in Kodak 8000 c lateral cephalogram machine. The length was measured as the linear distance from the superior most point on the tuberculum sella to the tip of the dorsum sella. The depth was measured as a line perpendicular from the line joining tuberculum sella and dorsum sella to the inferior most point on the floor. The anteroposterior diameter of sella turcica was measured from the superior most point on the posteroinferior aspect of the hypophyseal fossa. (Fig. 2).

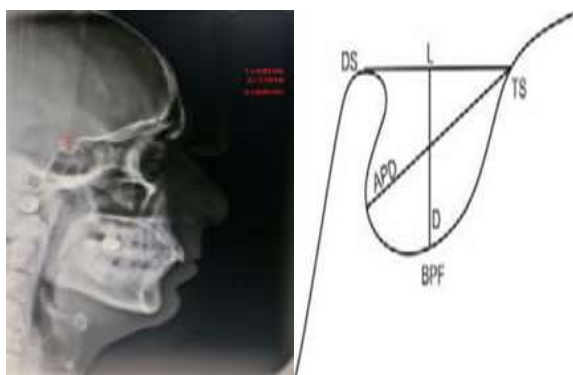


Fig. 2: Linear measurements of sella turcica. L- Length, D-Depth, APD-Anteroposterior diameters

Statistical analysis: Chi-square test and ANOVA tests were used for statistical analysis.

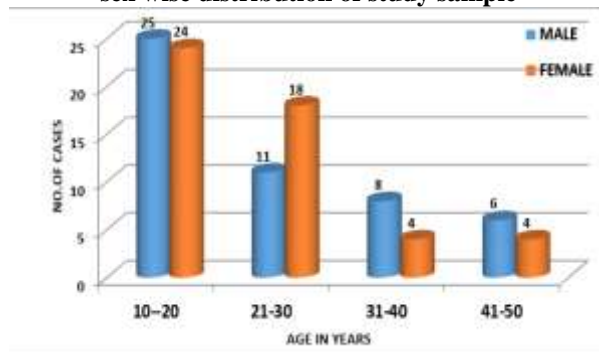
Results

Age & Sex Wise Distribution of Study Subjects: The study group consisted of 100 individuals, with equal distribution of 50 males and 50 females in the age group of 10- 50 years. There were 49(49%) subject in 10-20 years age group, 29(29%) subjects in 21-30 years age group, 12(12%) subjects in 31-40 years age group, 10(10%) subjects in 41-50 years age group. Among the study subjects there were 25(50%) males, 24(48%) females in 10-20 years age group, 11(22%) males and 18(36%) females in 21-30 years age group, 8(16%) males and 4(8%) females in 31-40 years age group, 6(12%) males and 4(8%) females in 41-50 years of age group. Mean age of the study subjects was 24± 11.36 in male 10-50 years age group and 23.02±11.77 in female 10-50 years age group. There was no statistically significance difference of age among males and females with Z=0.445 and P<0.05. (Table 1 & Graph 1).

Table 1: Age and sex wise distribution of study subjects

Age	Male		Female		Total		Z-Test	P-Value
	No	%	No	%	No	%		
10-20	25	50.0	24	48.0	49	49.0	0.445	P<0.05
21-30	11	22.0	18	36.0	29	29.0		
31-40	8	16.0	4	8.0	12	12.0		
41-50	6	12.0	4	8.0	10	10.0		
Total	50	100.0	50	100.0	100	100.0		
Mean±SD	24.04 ± 11.36		23.02 ± 11.77		23.53 ± 11.56			

Graph 1: Multiple bar diagram represents age and sex wise distribution of study sample



Age Wise Distribution of Sella Turcica Parameters

Length: Maximum length of sella turcica was 16.57 and minimum length was 4.57 with mean value of 9.59±1.78 in 10-20 years age group subjects, maximum length of sella turcica was 12.72 and minimum length was 7.39 with mean value of 11.80±2.08 in 21-30 years of age group subjects, maximum length of sella turcica was 12.66 and minimum length was 8.89 with mean value of 11.06±2.12 in 31-40 years of age group subjects, maximum length of sella turcica was 15.3 and minimum length was 8.88 with mean value of 11.5±1.83 in 41 -50 years of age group subjects. Among the 100 study subjects maximum length was 16.57 and minimum length was 4.57 with total mean value of 10.5±1.93. There was statistically highly significant age wise distribution of sella turcica parameters with F=11.4 and P<0.0001 (Table 2 & Graph 2).

Depth: Maximum depth of sella turcica was 10.28 and minimum depth was 3.83 with mean value of 7.13±1.32 in 10-20 years age group subjects, maximum depth of sella turcica was 10.99 and minimum depth 6.70 with mean value of 8.31+/- 1.43 in 21-30 years of age group subjects, maximum depth of sella turcica was 11.19 and minimum depth 5.93 with mean value of 8.14±1.14 in 31-40 years of age group subjects, maximum depth 10.8 respectively and minimum depth was 6.81 with mean value of 8.93±1.20 in 41 -50 years of age group subjects. Among the 100 study subjects maximum depth 11.19 and minimum depth was 3.83 with total mean value of

7.82±1.34. There was statistically highly significant age wise distribution of sella turcica parameters with F= 202.45 and P<0.0001 (Table 2 Graph 2)

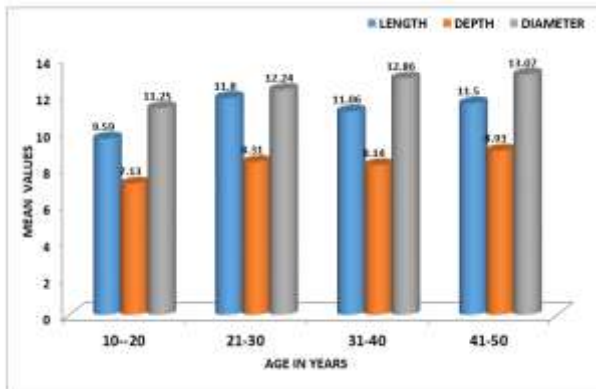
Diameter: Maximum diameter of sella turcica was 13.71 and minimum diameter was 7.20 with mean value of 11.25±1.83 in 10-20 years age group subjects, maximum diameter of sella turcica was 15.91 and minimum diameter was 9.59 with mean value of 12.24± 1.64 in 21-30 years of age group subjects, maximum diameter of sella turcica was 18.72 and minimum diameter was 10.32

with mean value 12.86±1.67 in 31-40 years of age group subjects, maximum diameter of sella turcica 14.69 and minimum diameter was 9.04 with mean value 13.07±1.54 in 41 -50 years of age group subjects. Among the 100 study subjects maximum diameter was 18.72 and minimum diameter was 7.20 with total mean value of 12.29±1.72. There was statistically highly significant age wise distribution of sella turcica parameters with F= 103.53 and P<0.0001 (Table 2 Graph 2).

Table 2: Age wise distribution of sella turcica parameters for length, depth and diameter

Age in Years	No/of cases	Length				Depth				Diameter			
		Mean	SD	Mini mum	Maxim um	Mean	SD	Mini mum	Maxim um	Mean	SD	Mini mum	Maxim um
10-20	49	9.59	1.78	4.57	16.57	7.13	1.32	3.83	10.28	11.25	1.84	7.2	13.71
21-30	29	11.8	2.08	7.39	12.72	8.31	1.43	6.7	10.99	12.24	1.64	9.59	15.91
31-40	12	11.06	2.12	8.89	12.66	8.14	1.14	5.93	11.19	12.86	1.67	10.32	18.72
41-50	10	11.5	1.83	8.88	15.3	8.93	1.2	6.81	10.8	13.07	1.54	9.04	14.69
Total	100	10.5	1.93	4.57	16.57	7.82	1.34	3.83	11.19	12.29	1.72	7.2	18.72
F= 11.4 P<0.0001						F=202.45 p<0.0001				F=103.53 P<0.0001			

Graph 2: Linear dimensions of sella turcica (In Mm) according to age group



10.73±2.40 in 50 males subjects, maximum length of sella turcica 16.57 and minimum length was 4.57 with mean value of 10.27±1.41 in 50 females subjects. Among the 100 study subjects maximum length was 16.57 and minimum length was 4.57 with total mean of value 10.5±1.93. There was no statistically significance sex wise distribution of sella turcica parameters with F=1.031 and P>0.0001 (Table 3).

Depth: Among the study subjects there were 50 males and 50 females. Maximum depth of sella turcica was 11.19 and minimum depth was 3.83 with mean value of 7.67±1.38 in 50 males subjects, maximum depth of sella turcica was 10.99 and minimum depth was 4.31 with mean value of 7.97±1.31 in 50 females subjects. Among the 100 study subjects maximum depth was 11.19 and minimum depth was 3.83 with total mean value of 7.82±1.34. There was no statistically significance sex wise distribution of sella turcica parameters with F=1.081 and P>0.0001 (Table 3 & Graph 3).

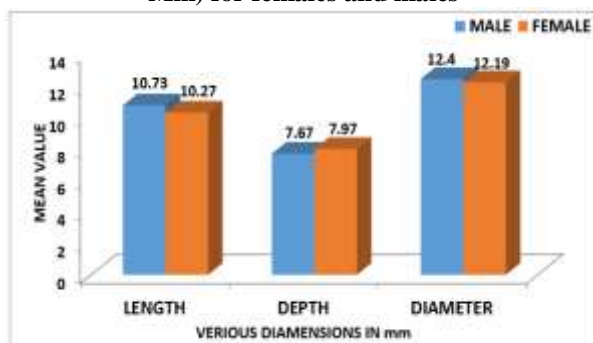
Sex Wise Distribution of Sella Turcica Parameters

Length: Among the study subjects there were 50 males and 50 females. Maximum length of sella turcica 15.73 and minimum length was 4.57 with mean value of

Table 3: Sex wise distribution of sella turcica parameters for length, depth and diameter

Sex	No of cases	Length				Depth				Diameter			
		Mean	SD	Mini um	Maxi mum	Mean	SD	Mini mum	Maximu m	Mean	SD	Mini um	Maximu m
Male	50	10.73	2.4	4.57	15.73	7.67	1.38	3.83	11.19	12.4	2.32	7.2	18.72
Female	50	10.27	1.41	6.76	16.57	7.97	1.31	4.31	10.99	12.19	1.54	7.48	15.91
Total	100	10.5	1.93	4.57	16.57	7.82	1.34	3.83	11.19	12.29	1.72	7.2	18.72
F=1.031 P>0.05						F=1.081 P>0.05				F=2.64 P>0.05			

Graph 3: Linear dimensions of sella turcica (In Mm) for females and males



Diameter: Among the study subjects there were 50 males and 50 females. Maximum depth of sella turcica was 18.72 and minimum depth was 7.20 respectively with mean value of 12.40 ± 2.32 in 50 males subjects, maximum depth of sella turcica was 15.91 and minimum depth 7.48 with mean value of 12.19 ± 1.54 in 50 females subjects. Among the 100 study subjects maximum depth was 18.72 and minimum depth was 7.20 with total mean value of 12.29 ± 1.72 . There was no statistically significance sex wise distribution of sella turcica parameters with $F=2.64$ and $P>0.0001$ (Table 3 & Graph 3).

Discussion

The Sella turcica is a structure recognized on lateral cephalometric radiographs and routinely traced for cephalometric analysis. This makes it a good source of additional diagnostic information related to pathology of the hypophysis, or to various syndromes that affect the craniofacial region. Clinicians should be familiar with the normal radiographic variability of this area in order to recognize and investigate deviations that may reflect pathological situations, even before these become clinically apparent.

Age wise distribution of sella turcica parameters: A statistical significant difference in linear dimensions between age groups were found in sella length, depth and diameter with p value < 0.0001 . All these results from our study agree with findings from Choi et al⁽³⁾ study where they found that an increase in sella dimensions with age, from the 6 - 10 to the 21 - 25 age group, because of its contents, i.e. the hypophysis, have been shown to increase in size with age. When our study sample was compared to a Norwegian sample in a study by Axelsson et al.⁽⁴⁾ The linear dimension in the study sample were on average 2.5 mm to 3mm larger than those in Norwegian subjects. Although the size of sella turcica measured are comparable in both studies the discrepancy can be attributed to factor such as ethnicity Elster et al.⁽⁵⁾ When studying the effects of gender and age, on the size of the sella turcica, the results showed that age was significantly related to the dimensions of sella, which were larger in older subjects, irrespective of gender. The linear dimensions obtained from the current study can be used to approximate the size of the pituitary gland, and may aid the clinician with an abnormally large sella turcica on lateral cephalograms. The orthodontist should also be familiar with the different shapes of the

sella area, in order to help distinguish pathology from normal developmental patterns

Sex wise distribution of sella turcica parameters:

There was no significant difference in the linear measurements of sella turcica between males and females with p value > 0.05 . All these results from our study agree with Yassir et al⁽⁶⁾ in Iraq population, Shah et al⁽⁷⁾ in Pakistan population, Chavan et al⁽⁸⁾ in Maharashtra population, Osunwoke et al⁽⁹⁾ in Nigerian population, where between genders no significant difference was found in terms of length, depth, and diameter. Study done by Axelsson et al. also revealed that there was significant difference in the length of sella turcica in gender which was more in males compared to females, whereas there was no difference in depth and anteroposterior diameter.

Similar results were given in the study done in south Indian population which showed the difference in length of sella turcica between males and females. The Genetic factors it is most likely play a leading role in male-female growth differences. The marked advancement of girls over boys in the rate of maturation is attributed to the delaying action of the Y chromosome in males. By delaying growth, the Y chromosome allows males to grow over a longer period of time.

Conclusion

There was a significant increase in the length, depth and anteroposterior diameter of sella turcica as age advances. There was no difference in the size of sella turcica between males and females. The results can be used as a reference in future studies with larger study population.

References

1. Du Bonlay G, Trickey S. The choice of radiological investigation in the management of tumors around file sella. *Clin Radiol*.1967;18:349-65.
2. Pisaneschi M, Kapoor G. Imaging of the sella and parasellar region. *Neuroimaging Clinics of North America* 2005;15:203-219.
3. Choi WJ, Hwang EH, Lee SR. The study of shape and size of normal sella turcica in cephalometric radiographs. *Korean J Oral Maxillofac Radiol*. 2001;31:43-9.
4. Axelsson S, Storhaug K, Kjaer I. Post-natal size and morphology of the sella turcica. Longitudinal cephalometric standards for Norwegians between 6 and 21 years of age. *Eur J Orthod* 2004;26:597-604.
5. Elster AD. Imaging of the sella: anatomy and pathology. *Seminars in Ultrasound, CT, and MRI*. 1993;14a:182-94.
6. Yassir AY, Nahidh M, Yousif HA. Size and morphology of sella turcica in Iraqi adults. *Mustansiria Dent J* 2010;7:23-30.
7. Shah AM, Bashir U, Ilyas T. The shape and size of the sella turcica in skeletal class I, II, III in patients presenting at Islamic International Dental Hospital, Islamabad. *Pak Oral Dent J* 2011;31:104-10.
8. Chavan SR, Kathole MA, Katti AS, Herekar NG. Radiological analysis of sella turcica. *Int J Recent Trends Sci Technol* 2012;4:36-40.
9. Osunwoke EA, Mokwe CR, Amah-Tariah FS. Radiologic measurements of the sella turcica in an adult Nigerian population. *Int J Pharm Res* 2014;4:115-7.