

Multiple cysts involving maxilla and mandible: A case report

MK Navya^{1,*}, Sujatha GP², Shivaprasad S³, Ashok L⁴

¹PG Student, ^{2,3}Professor, ⁴Professor & HOD, Dept. of Oral Medicine & Radiology, Bapuji Dental College & Hospital, Davangere, Karnataka

***Corresponding Author:**

Email: navu_mk@yahoo.in

Abstract

Among the developmental cysts affecting the maxillofacial region, Odontogenic Keratocyst (OKC) is the most common one. Recently OKC is reclassified as Keratocystic Odontogenic Tumor (KCOT) Usually multiple OKCs are seen in association with Nevoid Basal Cell Carcinoma Syndrome (NBCCS) in 95% of cases but this case report highlights a non-syndromic case of multiple OKCs affecting both maxilla and mandible.

Keywords: multiple radiolucencies, marsupialization, keratocystic odontogenic tumor

Introduction

One of the most common developmental cyst affecting the maxillofacial region is OKC. It causes asymmetry of the jaw, has an aggressive growth pattern and also has high recurrence rate. Presence of multiple OKCs are usually associated with syndrome but at times they can be present without any association with syndrome. Ours is one such case where there are multiple cysts in both the jaws and is not associated with any syndrome.

Case Report

A 15 year old male patient came to the department of Oral Medicine & Radiology, Bapuji Dental College and Hospital, Davangere, with a chief complaint of swelling on left face region since 1 month. The history of present illness revealed swelling was insidious in onset, gradually progressing in size, initially was small and attained current size in months duration. The swelling was painless. His past medical history revealed that he had undergone surgical intervention for cleft lip and palate 12 years back. On extra oral examination surgical scar was evident on left border of philtrum region. Gross facial asymmetry was evident on left side of lower 3rd of face involving the angle and ramus. (Fig. 1) Swelling was roughly oval about 6×4cm in size, skin over the swelling was normal, smooth and borders were well defined. On palpation, swelling was non-tender and bony hard in consistency. On intra oral examination expansion of the labial and lingual cortical plate w.r.t 35, 36, 37 and 38 was evident. It extended from mesial aspect of 33 till distal aspect of 38. Surface of the swelling was normal and on palpation it was non tender and bony hard in consistency with intermittent yielding areas. Surgical scar was also evident on the hard palate. Patient had mixed dentition with retained 52, 53, 55, 63, 74, 75 and 85. Peg lateral was evident w.r.t 12 and 21 was rotated. Caries was evident w.r.t 55, 74, 75, 84 & 85.

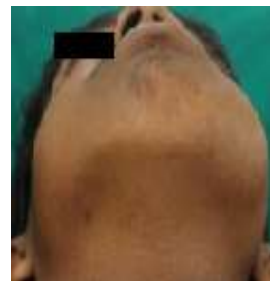
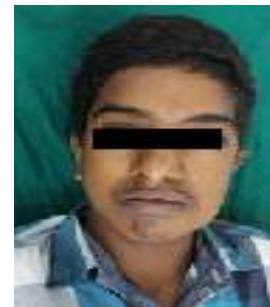
Fig. 1: Facial asymmetry and surgical scar of cleft lip & palate

Based on the clinical findings a provisional diagnosis of multiple odontogenic cysts involving maxilla and mandible was given. Differential diagnosis of multiple dentigerous cysts and nevoid basal cell carcinoma syndrome was considered

Patient was advised to undergo complete blood investigations, OPG and CBCT. Patient was anemic with hemoglobin concentration of 9 g/dl. OPG revealed, mixed dentition stage with impacted 17, 23, 27, 34. Crown formation was evident w.r.t 18 & 28. Multiple well defined radiolucencies were evident at the apical region w.r.t 33, 34, 35 and angle and ramus region distal to 37. 34 was vertically impacted in the radiolucency and was distally as well as inferiorly displaced. Radiolucency w.r.t 33, 34 & 35 is about 4×3.5 cm in size with a homogeneously radiolucent internal structure and the radiolucency posterior to 37

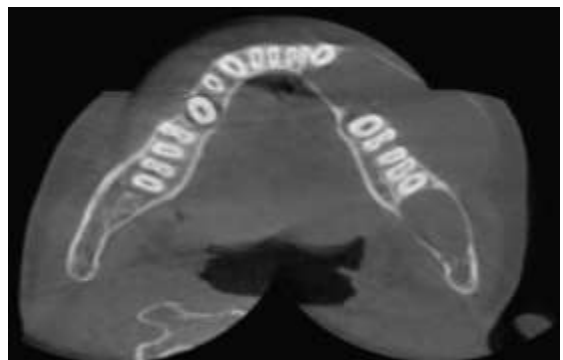
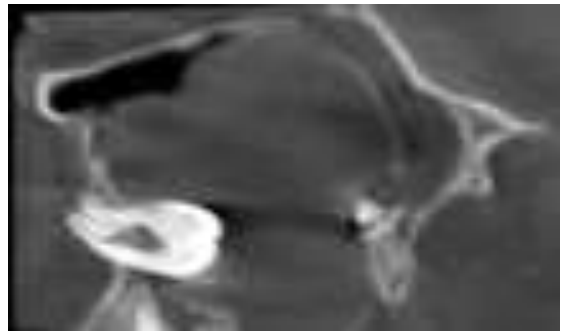
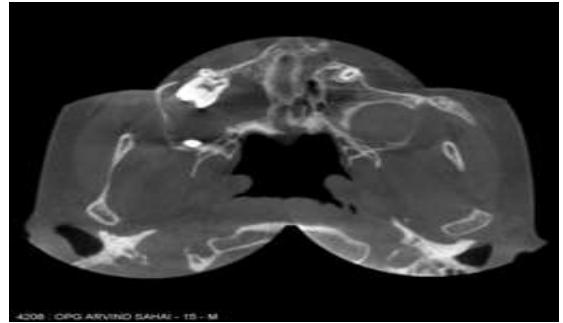
was about 4×2.5 cm in size with homogenously radiolucent internal structure. Radiopaque tooth like portion evident at the incisal aspect of impacted 23. Superiorly and distally displaced impacted 18 & 28. (Fig. 2)

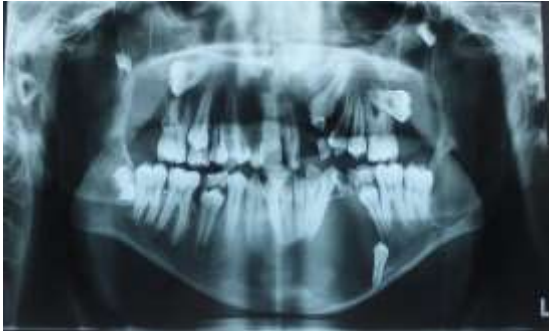

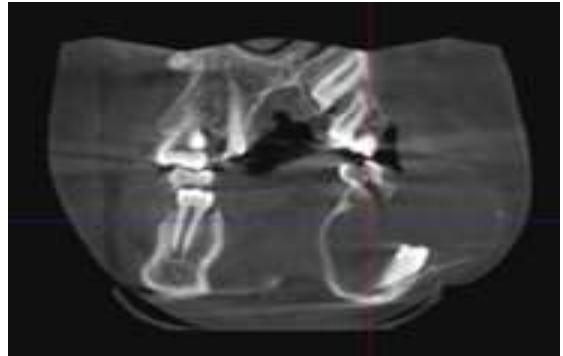Fig. 2: OPG showing multiple radiolucencies in left side of mandible & multiple impacted tooth

Chest X-ray & skull X-ray revealed no abnormalities.

CBCT of both maxilla and mandible was done. In maxilla, right axial section showed horizontally impacted 17 with crown facing posteriorly. There was evident of hypodense area roughly oval in shape about 3cm in diameter. Buccal and lingual cortical plate expansion was seen. Left maxilla showed thinning of buccal and lingual cortical plate with impacted 28. In mandible, on axial section of left body of mandible, the lesion crossing midline extending upto 43 region with expansion of buccal and lingual cortical plate. The Hounsfield of lesion ranged from 150-200 HU. Coronal section showed break in continuity of the buccal cortical plate along with impacted 34 which is pushed posteroinferiorly with root projecting lingually. Sagittal section showed thinning of buccal and lingual cortical plate with break in continuity of lingual cortical plate with respect to lower incisor region. (Fig. 3) Excisional biopsy of the lesion was done and the histopathological report revealed, Odontogenic Keratocystic Tumor involving anterior body and posterior angle and ramus of left side of mandible and left and right posterior maxilla. Correlating the clinical, radiographic and histopathologic reports, a final diagnosis of Non-syndromic Multiple Keratocystic Odontogenic Tumor involving maxilla and mandible was given. Marsupialization followed by enucleation of the lesions were carried out.



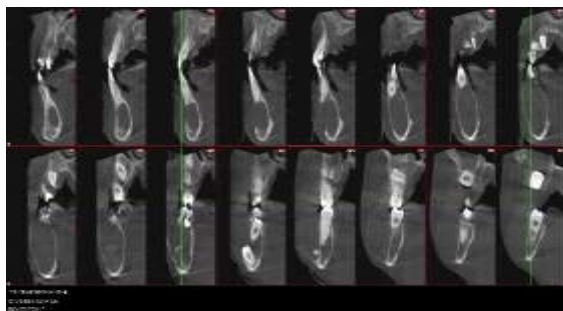


Fig. 3: CBCT images showing the lesion in various sections

Patient was then reevaluated after 3 months and 1 year, there was complete regression of swelling and OPG taken revealed adequate bone healing at the affected site.(Fig. 4)

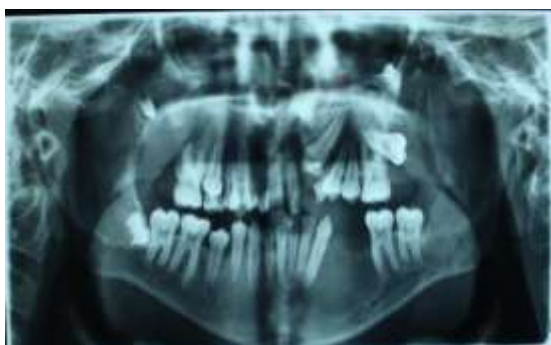
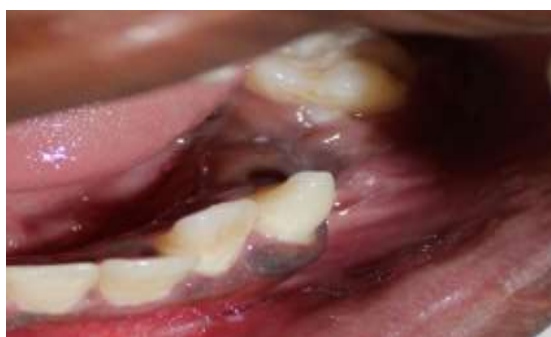
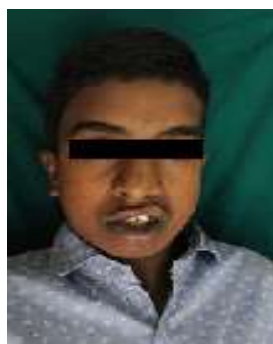Fig. 4: Post-operative follow up shows healing of lesion

Discussion

The first description of odontogenic keratocyst (OKC) was published in 1956 by Philipsen;⁽¹⁻³⁾ the lesion attracted interest because of its specific histopathological features. In 1963 Pindborg and Hansen suggested the histological criteria for describing the essential features of OKC,⁽¹⁾ and investigators started to discuss the differences between the common parakeratinized type and the rarer orthokeratinized type.⁽³⁾ Clinically, the parakeratinizing lesions are characterized by aggressive growth and a tendency to recur after surgical treatment. They show increased mitotic activity in the cystic epithelium, together with a potential for budding of the basal layer and the presence of daughter cysts in the cystic wall. The odontogenic keratocyst (OKC) is now designated by the World Health Organization (WHO) as a keratocystic odontogenic tumour (KCOT) and is defined as “a benign uni- or multicystic, intraosseous tumour of odontogenic origin, with a characteristic lining of parakeratinized stratified squamous epithelium and potential for aggressive, infiltrative behavior.” WHO “recommends the term keratocystic odontogenic tumour as it better reflects its neoplastic nature.”⁽⁴⁾ The discovery of chromosomal abnormalities and genetic alterations, such as mutation of the PTCH gene, appeared to confirm this concept.

KCOTs comprise approximately 11% of all cysts of the jaws.⁽²⁾ They occur most commonly in the mandible, especially in the posterior body and ramus regions. It has a wide range of occurrence but is seen commonly in second and third decade of life, after that it gradually decreases. Most recent studies reveal that there is slight male dominance.⁽⁵⁾ Patients usually present with complaint of swelling, pain and discharge or may be asymptomatic.⁽⁶⁾ Distinctive clinical features include a potential for local destruction and a tendency for multiplicity, especially when the lesion is associated with nevoid basal cell carcinoma syndrome (NBCCS) or Gorlin-Goltz syndrome. But in our case the lesion is not associated with any syndrome.⁽⁷⁾ KCOT has a high recurrence rate of about 25%- 60% and when it is syndromic case then it has a recurrence as high as 80%.^(8,9) In 1976, Brannon proposed 3 mechanisms for KCOT recurrence: incomplete removal of the cyst lining, growth of a new KCOT from satellite cysts (or odontogenic rests left behind after surgery) and development of a new KCOT in an adjacent area that is interpreted as a recurrence.^(6,10) The wide range in reported recurrence rates has been attributed to the variation in follow-up times used by examiners, the surgical technique used and the number of cases incorporated into the studies.⁽¹¹⁾ Due to its high recurrence rate a long term follow up is required as there are chances of recurrence after 5- 7 years following treatment.

The radiographic appearance of KCOT is a unilocular or multilocular well circumscribed

radiolucent lesion with scalloped and corticated margins.⁽¹²⁾ Involvement of an unerupted tooth has been reported in 25% to 40% of cases.⁽¹³⁾ Radiographically, displacement of impacted or erupted teeth, root resorption, root displacement or extrusion of erupted teeth may be evident. There will be both buccal and lingual cortical plate thinning evident in radiographs.

The treatment of choice for KCOT lesions is still debatable. Traditionally, enucleation followed by peripheral ostectomy is considered the best treatment for KCOTs; however, its high surgical morbidity and relatively high rate of associated recurrence mean that it cannot be considered the most ideal form of surgical management. Some authors advocate a site- and size-based approach to KCOT treatment planning. For example, Dammer and others⁽¹⁴⁾ suggest that “small keratocysts near the alveolar process a maximum of 1 cm in diameter should be treated by simple excision, but large keratocysts near the base of the skull which have invaded soft tissue should be treated by radical excision.” This is presumably because of the potential for local invasion of the skull base, which can have catastrophic consequences.

Later studies revealed that marsupialization is applicable as a conservative technique for large lesions.⁽²⁾ Although it has the advantage of being less aggressive, it is not widely used by surgeons because it requires a high degree of patient cooperation, involving lesion irrigation on a regular basis and attendance for regular follow-ups.⁽¹⁵⁾ According to a retrospective study conducted by Habibi A et al in 2007, treatment modality for KCOT by enucleation of lesions showed a 7.6% recurrence rate, which was somewhat lower than in similar studies. Marsupialization resulted in a 33.3% recurrence rate,⁽¹⁶⁾ which was similar to the figures reported by Forssell et al.⁽¹⁷⁾ and Ahlfors et al.⁽¹⁸⁾ No recurrences were found in 11 cases treated by marsupialization in combination. In our case also a combination treatment was done and after a year’s follow up no recurrence was seen.

In recent years, studies have hinted at possible new treatment methods for KCOT. According to Taipale and colleagues,⁽¹⁹⁾ cyclopamine, a plant-based steroidal alkaloid, inhibits the cellular response to the SHH signal. They found that cyclopamine blocks activation of the SHH pathway caused by oncogenic mutation making it a potential “mechanism-based” therapeutic agent for human tumours whose pathogenesis involves excess SHH pathway activity. Zhang and others⁽⁴⁷⁾ postulate that antagonists of SHH signalling factors could effectively treat KCOTs. Their suggested strategies include the reintroduction of a wild-type form of PTCH, inhibiting the SMO molecule by synthetic antagonists and suppressing the downstream transcription factors of the SHH pathway. They suggest that intracystic injection of an SMO protein-antagonist has the greatest potential as a future treatment option.⁽²⁰⁾

Conclusion

KCOT is a highly recurrent tumor and there needs a proper evaluation. History, proper examination, radiographic and histopathologic investigations should be carried out to diagnose this lesion for an accurate treatment planning. Treatment planning is important aspect because of high recurrence rate for this tumor. In our case a proper clinical, radiographic and histopathologic investigations were done which helped in diagnosis of lesion. And based on the diagnosis the treatment done was successful and no recurrence was seen after 1 year follow up. Patient is still under follow up.

References

1. Pindborg JJ, Hansen J. Studies on odontogenic cyst epithelium. 2. Clinical and roentgenologic aspects of odontogenic keratocysts. *Acta Pathol Microbiol Scand*. 1963; 58: 283-294.
2. Maurette PE, Jorge J, de Moraes M. Conservative treatment protocol of odontogenic keratocyst: a preliminary study. *J Oral Maxillofac Surg*. 2006; 64: 379-383.
3. Chow HT. Odontogenic keratocyst: a clinical experience in Singapore. *Oral Surg Oral Med Oral Pathol Oral Radiol Endod*. 1998; 86: 573-577.
4. Barnes L, Eveson JW, Reichart P, Sidransky D, editors. Pathology and genetics of head and neck tumours. Lyon: IARC Press; 2005. WHO classification of tumours series.
5. Browne RM. The odontogenic keratocyst: clinical aspects. *Br Dent J* 1970; 128(5):225-31.
6. Brannon RB. The odontogenic keratocyst. A clinicopathologic study of 312 cases. Part I. Clinical features. *Oral Surg Oral Med Oral Pathol* 1976; 42(1):54-72.
7. Jonathan Madras, Henry Lapointe. Keratocystic Odontogenic Tumour: Reclassification of the Odontogenic Keratocyst from Cyst to Tumour. *JCDA*. 2008; 74(2):165-165h.
8. Sapp JP, Eversole LR, Wysocki GP. Contemporary oral and maxillofacial pathology. 2nd ed. St. Louis: Mosby; 2004. p. 54.
9. Dominguez FV, Keszler A. Comparative study of keratocysts, associated and non-associated with nevoid basal cell carcinoma syndrome. *J Oral Pathol*. 1988; 17(1):39-42.
10. Woolgar JA, Rippin JW, Browne RM. A comparative study of the clinical and histological features of recurrent and non-recurrent odontogenic keratocysts. *J Oral Pathol* 1987; 16(3):124-8.
11. Bataineh AB, al Qudah M. Treatment of mandibular odontogenic keratocysts. *Oral Surg Oral Med Oral Pathol Oral Radiol Endod* 1998;86(1):42-7.
12. Farish SE, Di Leo CT. A case report. Under diagnosis of an odontogenic keratocyst: common cyst can be controversial lesion. *J Am Dent Assoc*. 1994;125:738-741.
13. Neville BW, Damm DD, Allen CM, Bouquot JE (2002) Oral and maxillofacial pathology. 2nd ed, WB Saunders, Philadelphia, 595-598.
14. Dammer R, Niederdelmann H, Dammer P, Nuebler-Moritz M. Conservative or radical treatment of keratocysts: a retrospective review. *Br J Oral Maxillofac Surg* 1997;35(1):46-8.

15. Marker P, Brondum N, Clausen PP, Bastian HL. Treatment of large odontogenic keratocysts by decompression and later cystectomy: a long term follow-up and a histologic study of 23 cases. *Oral Surg Oral Med Oral Pathol Oral Radiol Endod.* 1996;82:122-131.
16. Habibi A, Nasrollah Saghravani N, Habibi M, Ehsan Mellati E and Morteza Habibi M. Keratocystic odontogenic tumor: a 10-year retrospective study of 83 cases in an Iranian population. *J. Oral Sci.* 49,229-235,2007.
17. Forssell K, Sorvari TE, Oksala E. A clinical and radiographic study of odontogenic keratocysts in jaws. *Proc Finn Dent Soc.* 1974;70:121-134.
18. Ahlfors E, Larsson A, Sjögren S. The odontogenic keratocyst: a benign cystic tumor? *J Oral Maxillofac Surg.* 1984;42:10-19.
19. Taipale J, Chen JK, Cooper MK, Wang B, Mann RK, Milenkovic L, Scott MP, and others. Effects of oncogenic mutation in Smoothed and Patched can be reversed by cyclopamine. *Nature* 2000;406(6799):1005-9.
20. Zhang L, Sun ZJ, Zhao YF, Bian Z, Fan MW, Chen Z. Inhibition of SHH signaling pathway: molecular treatment strategy of odontogenic keratocyst. *Med Hypotheses* 2006;67(5):1242-4.